

A Piece of Light: Contrast Enhanced Mammographic (CEM) Guided Biopsy



Disclosure

- I have research and consulting collaboration with GE



Anat Kornecki, M.D FRCPC
Division of Breast Imaging & Lawson Research
Institutes
Western University, London, Ontario
St. Joseph Health Care
Canada

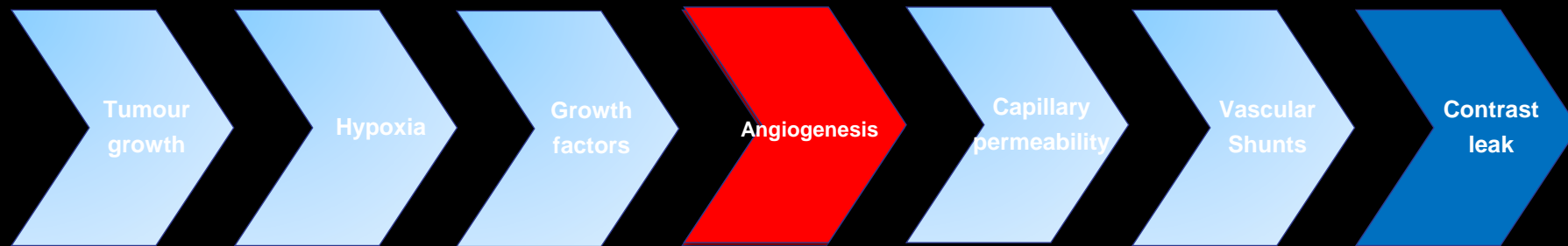
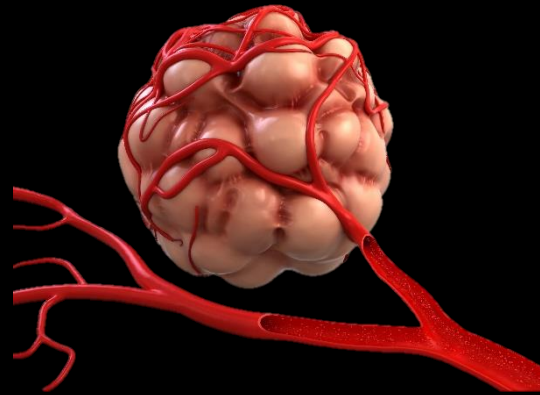



Anat.Kornecki@SJHC.london.on.ca

Objectives

- To describe CEM-Biopsy technique
- To explain the differences between biopsy approaches
- To provide solutions for non-visualized lesions
- To highlight the utility of CEM-guidance localization

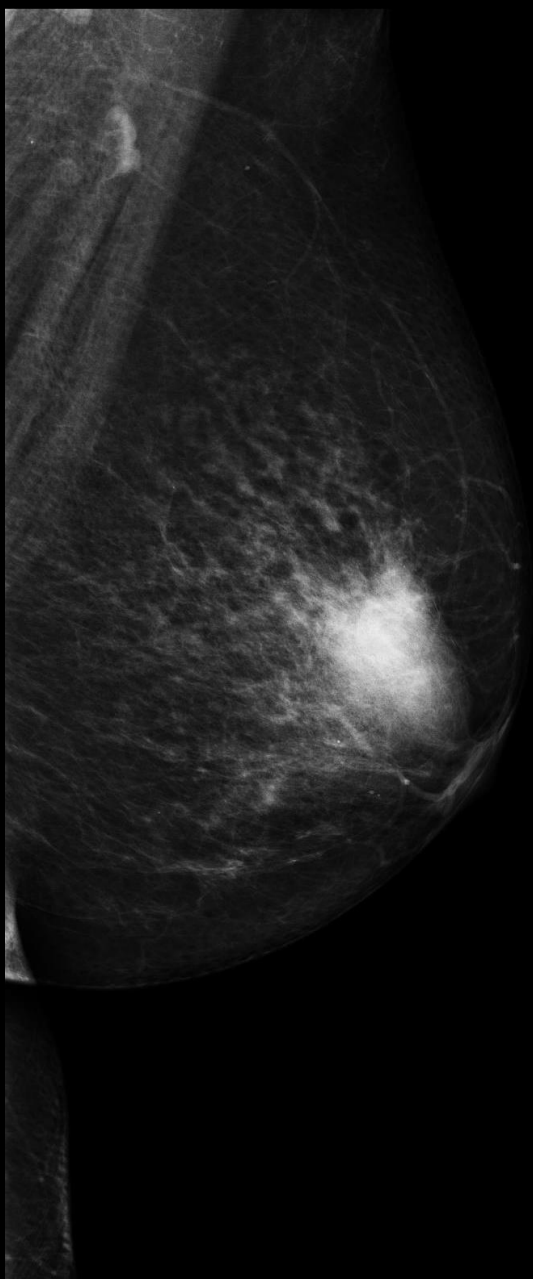Angiogenesis





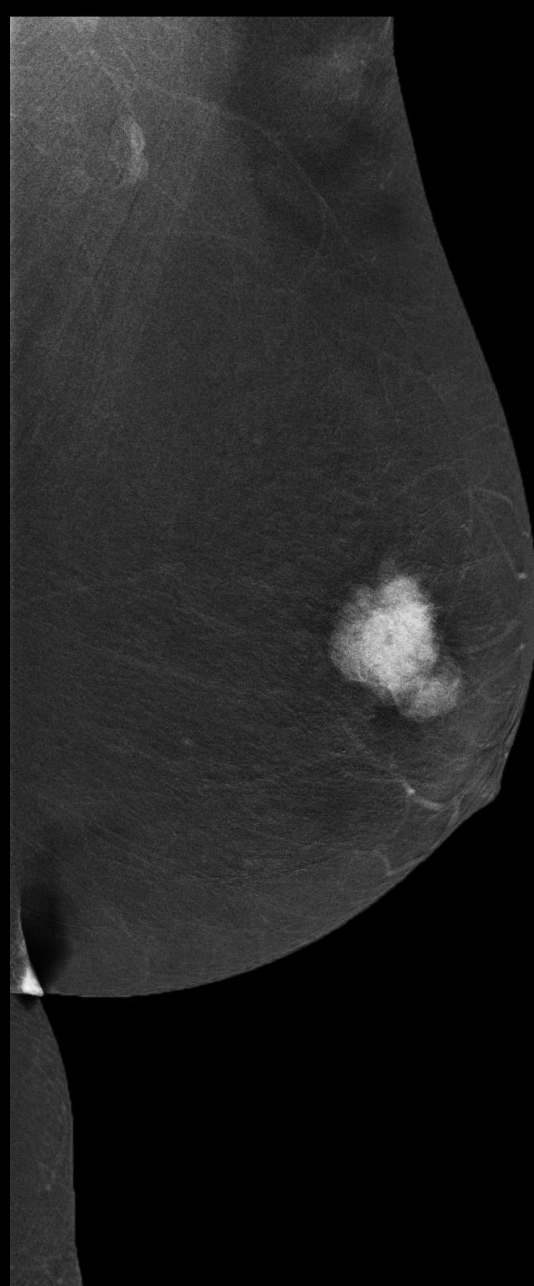HE

-

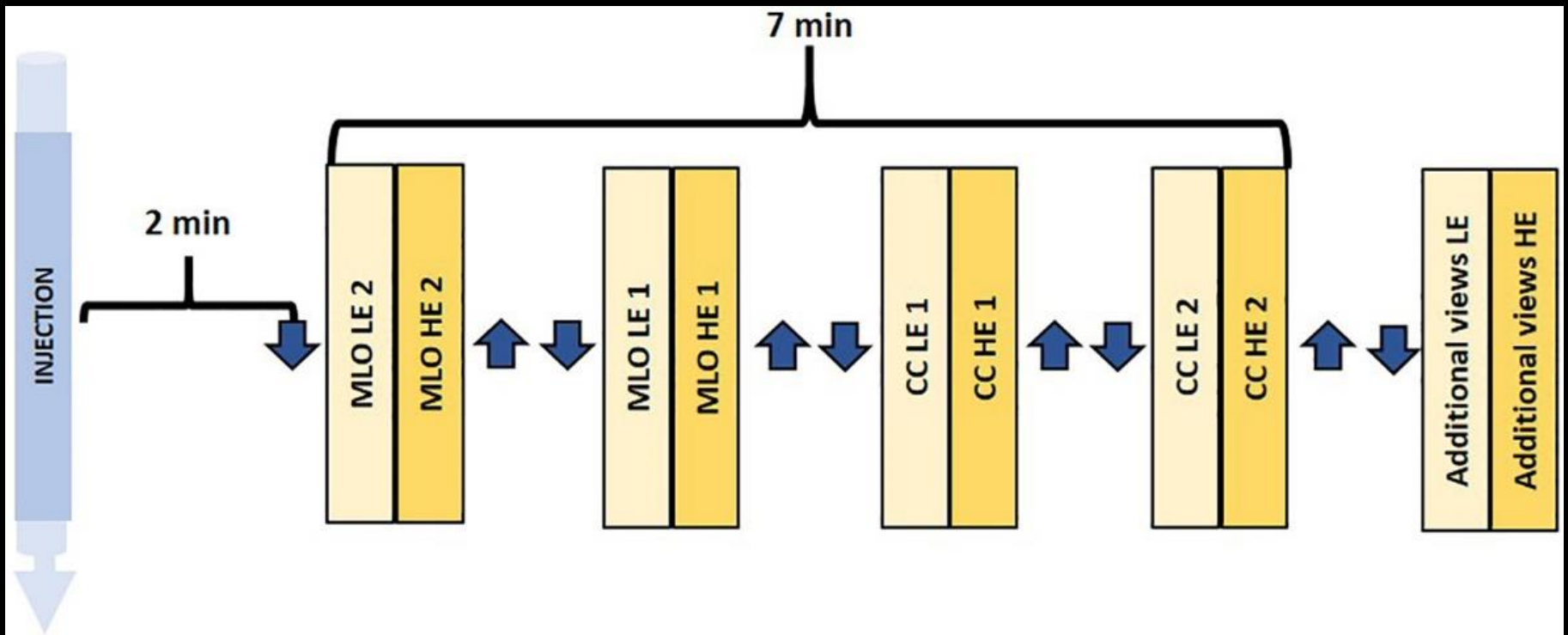


LE

=

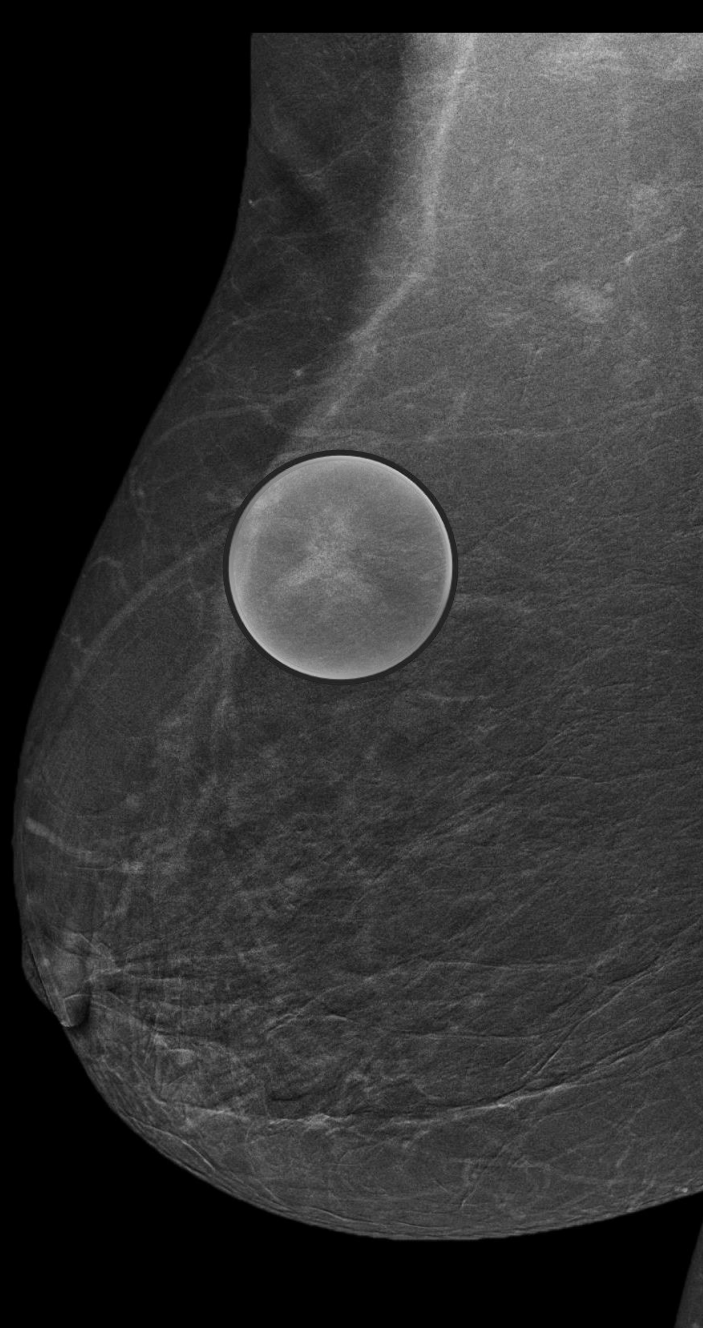
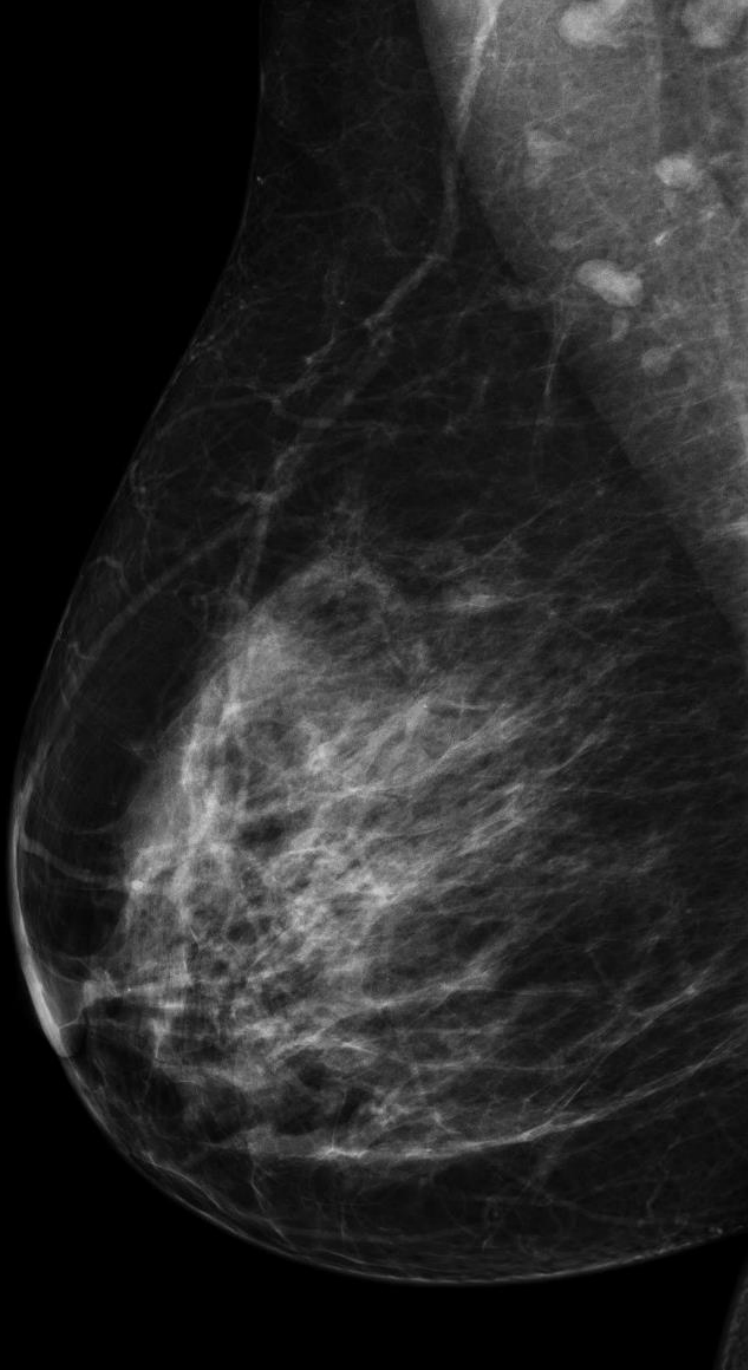


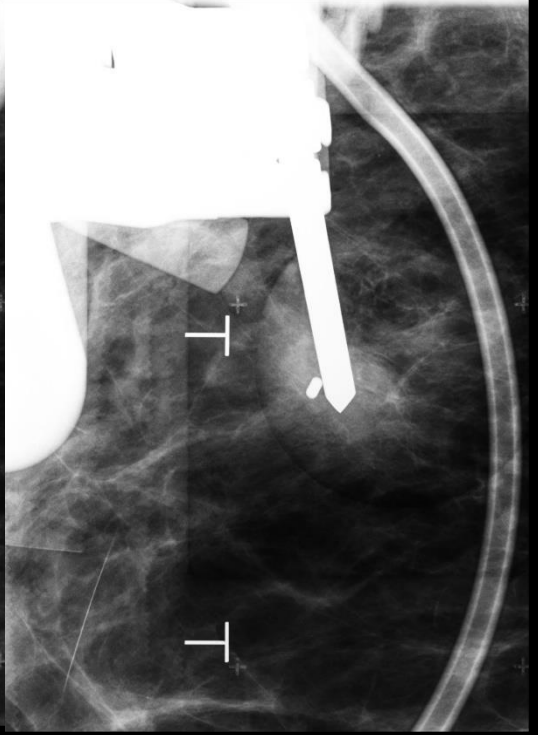
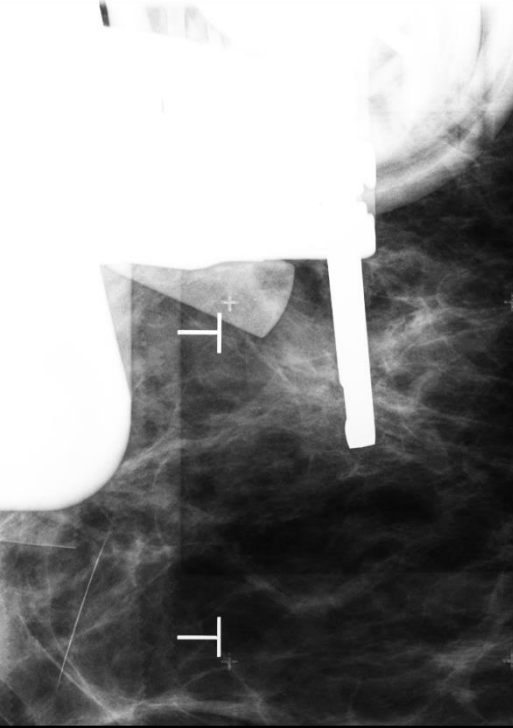
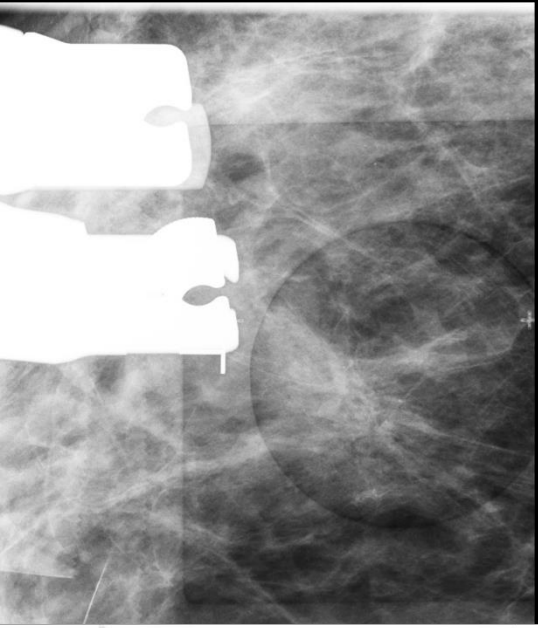
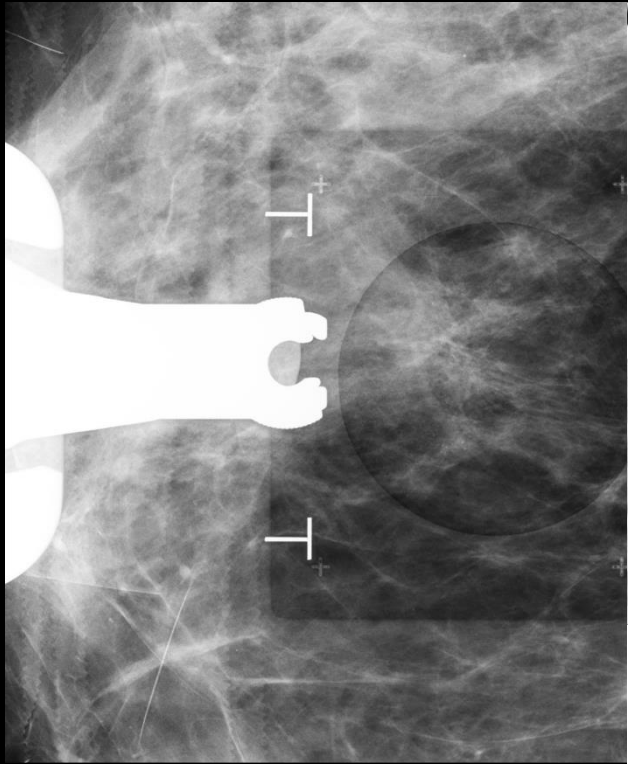
Recombined Views

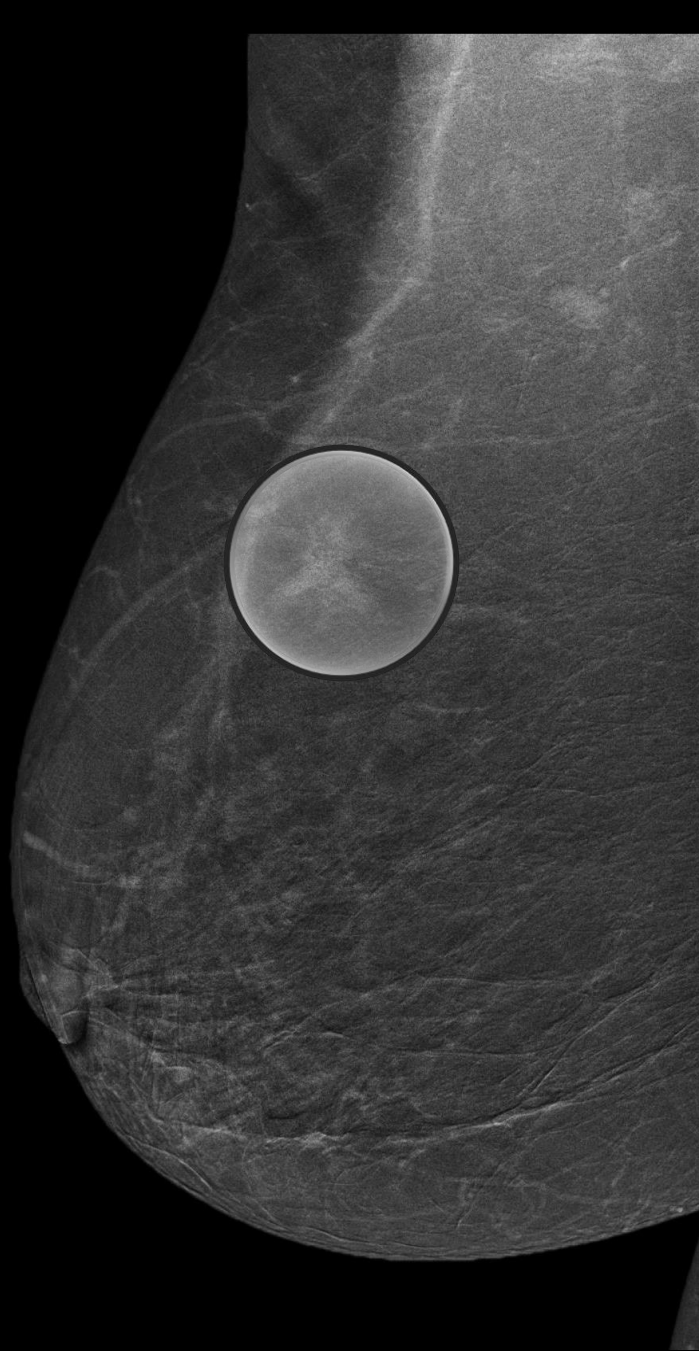
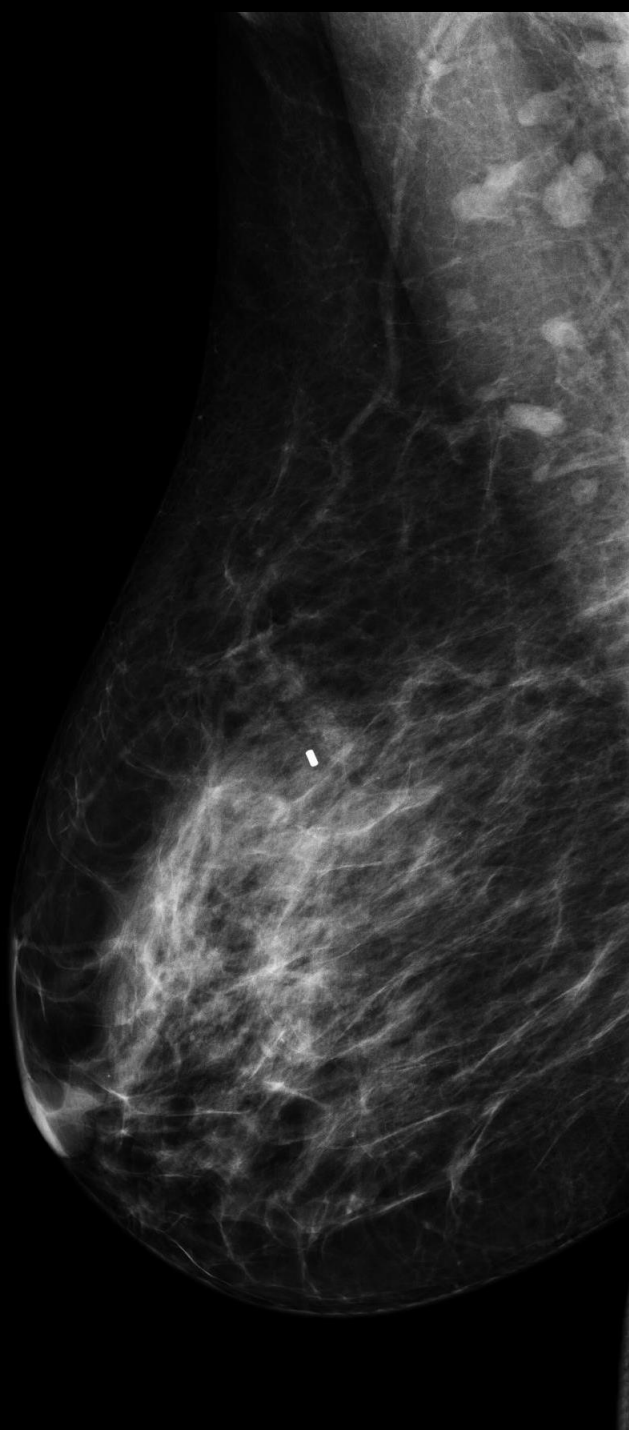


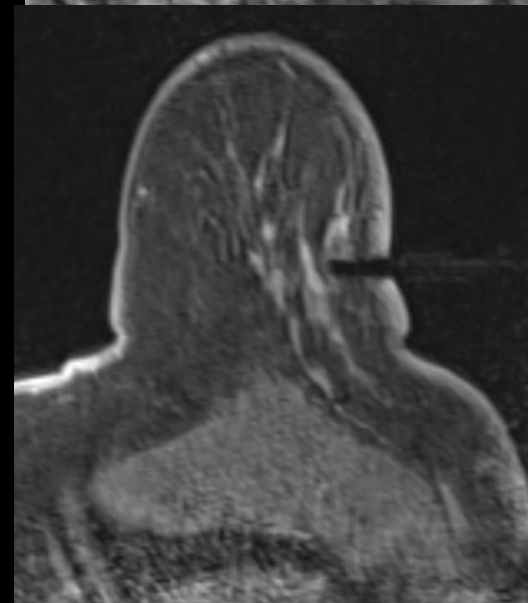
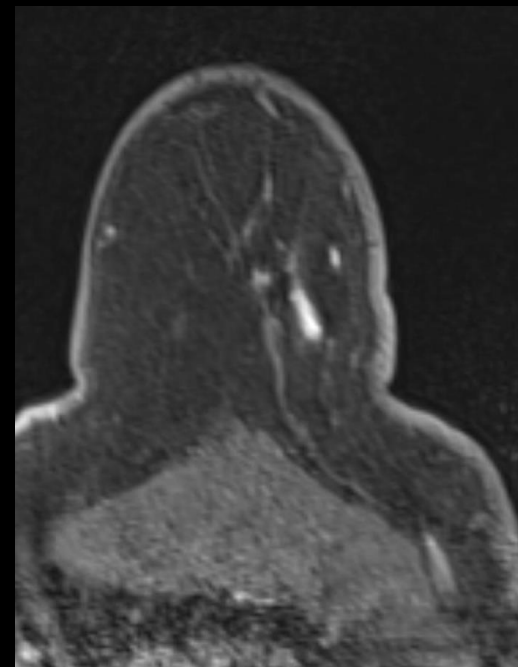
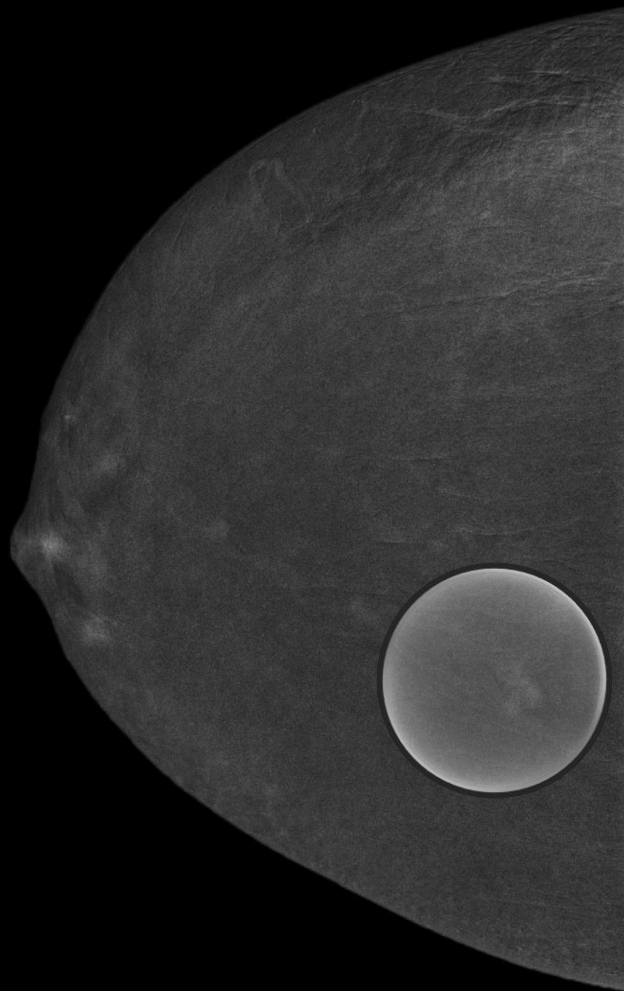
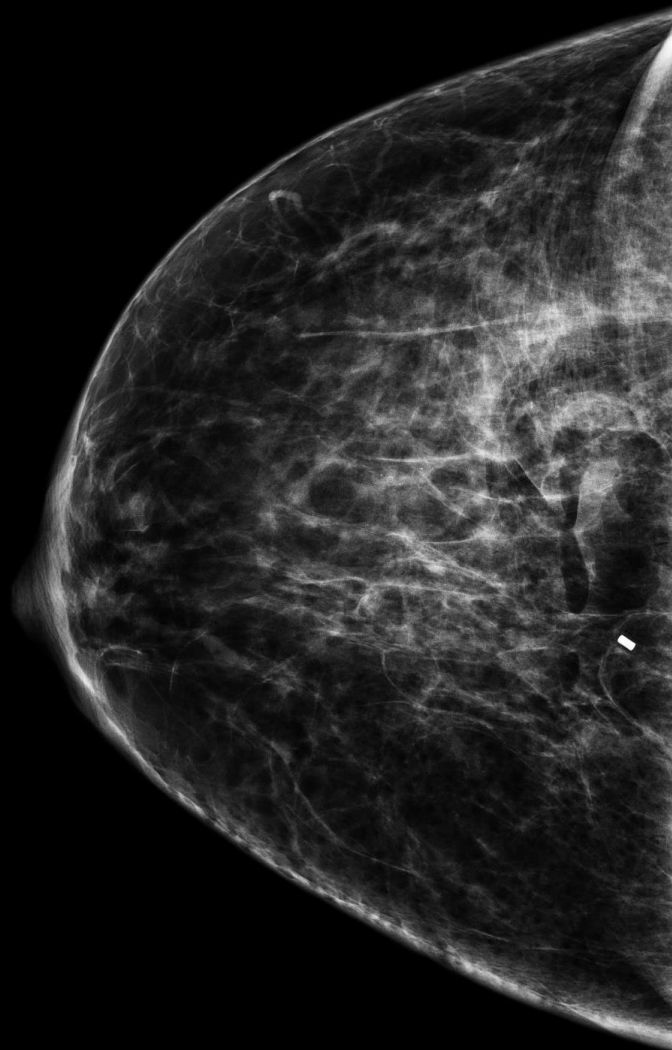
Challenge:

Lesions that are sonographically
occult



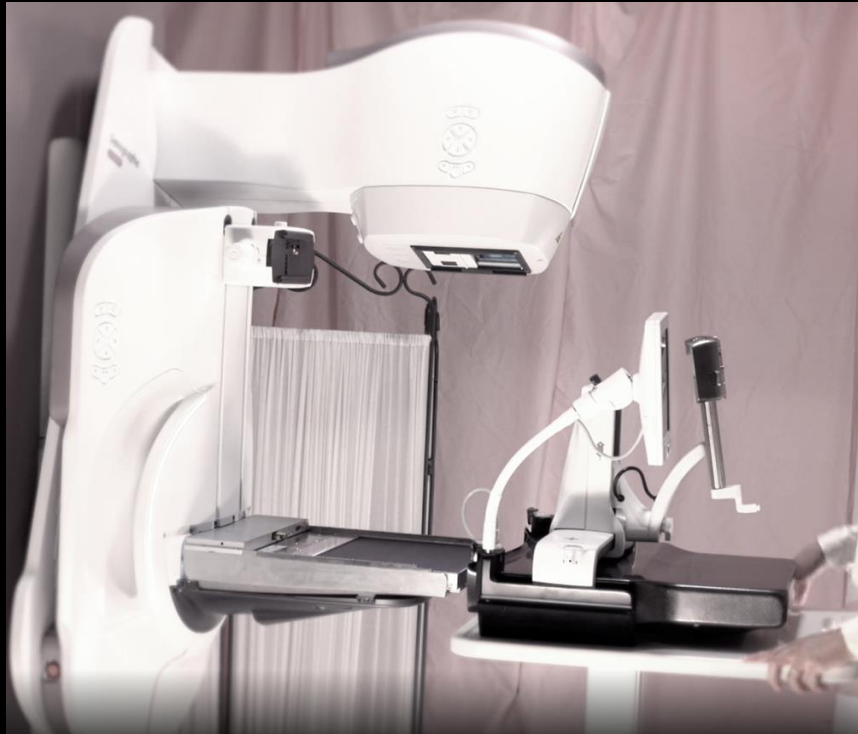



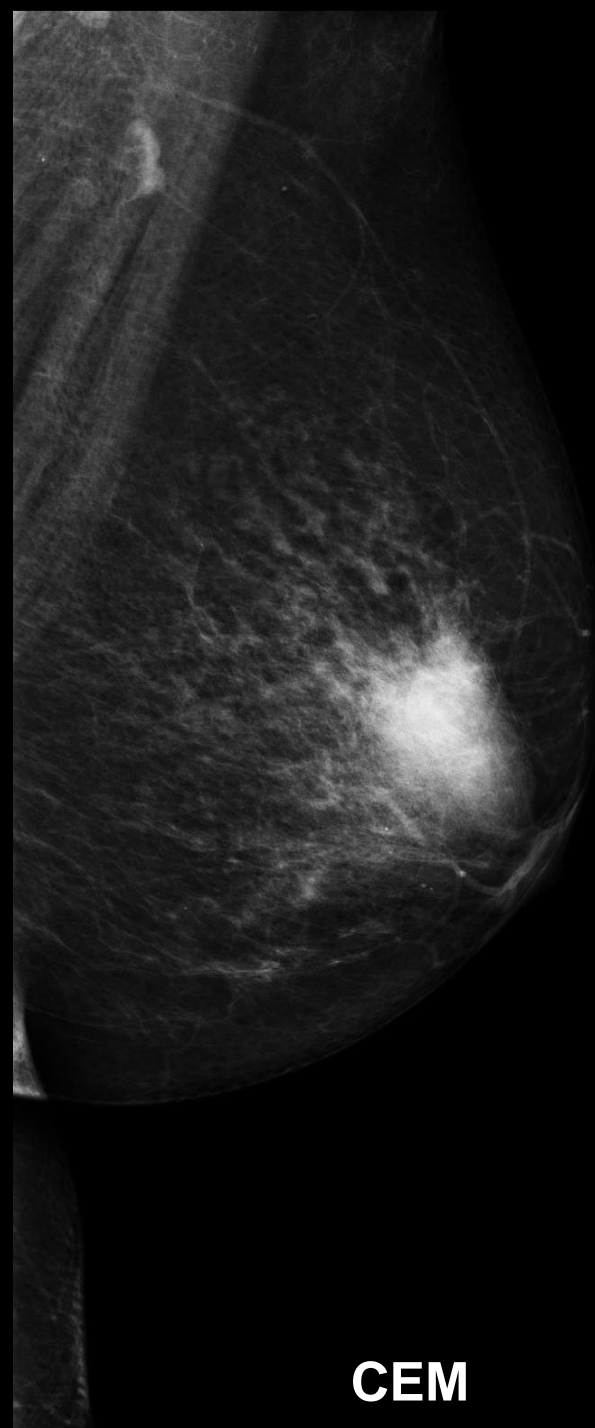




Solution

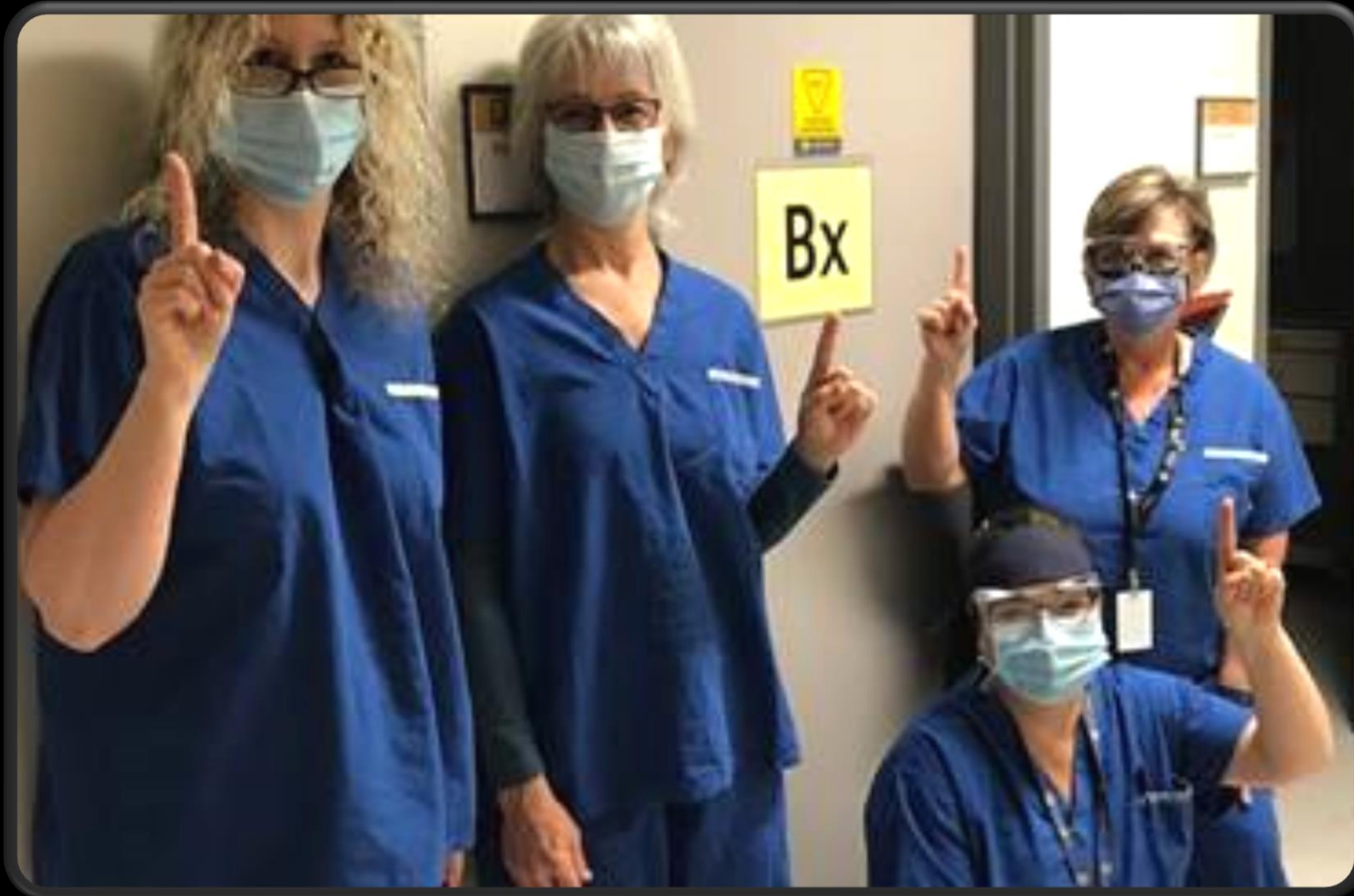


+

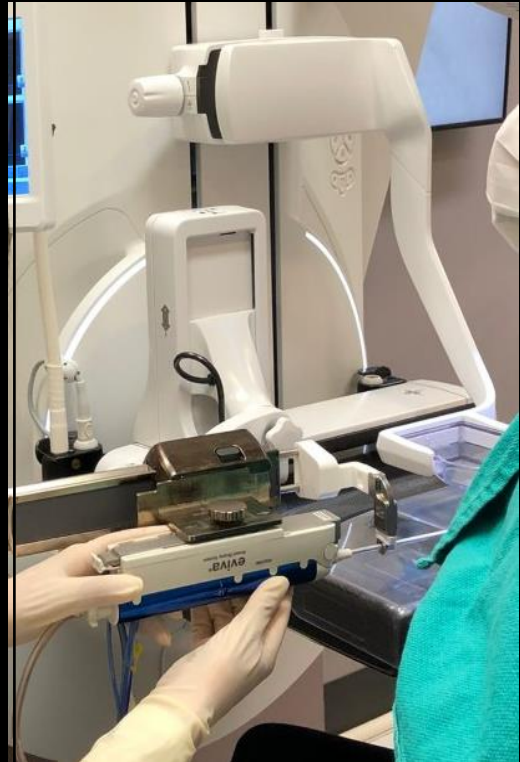
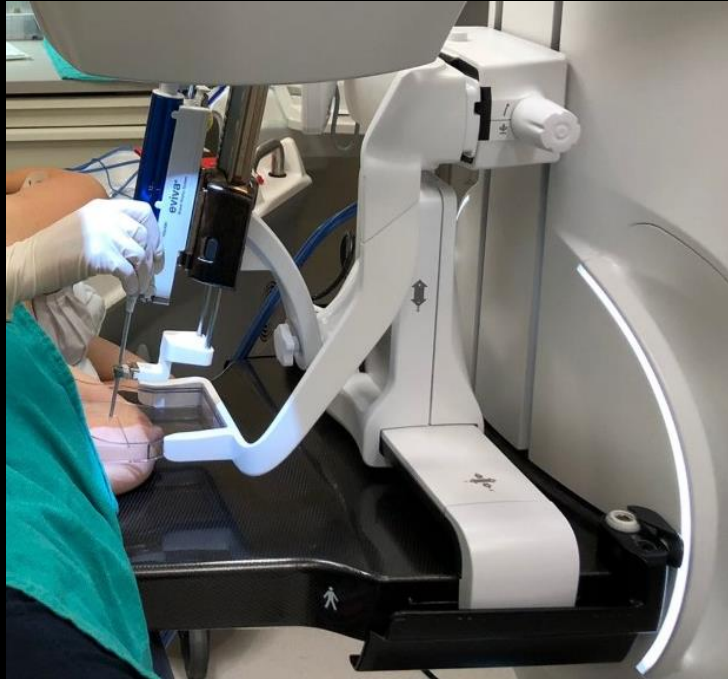
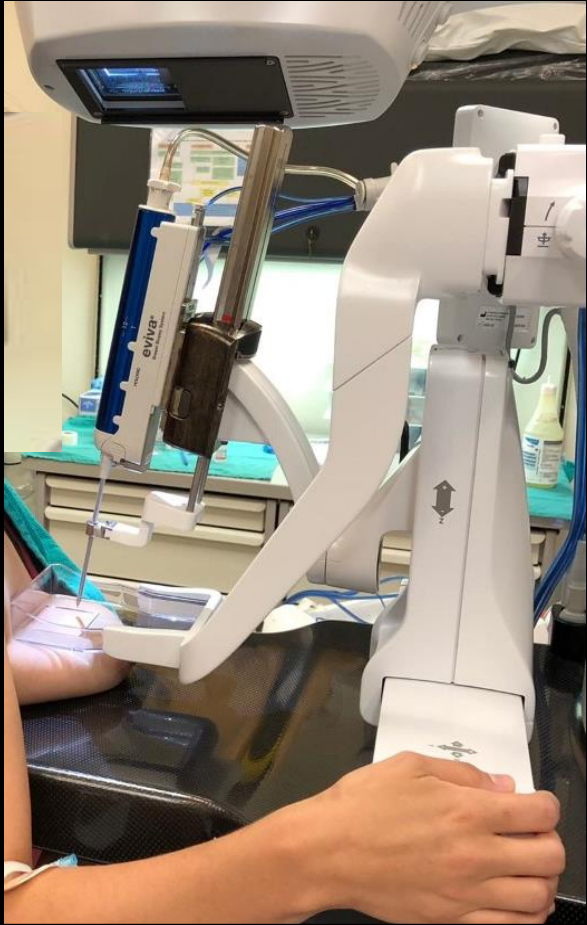CEM

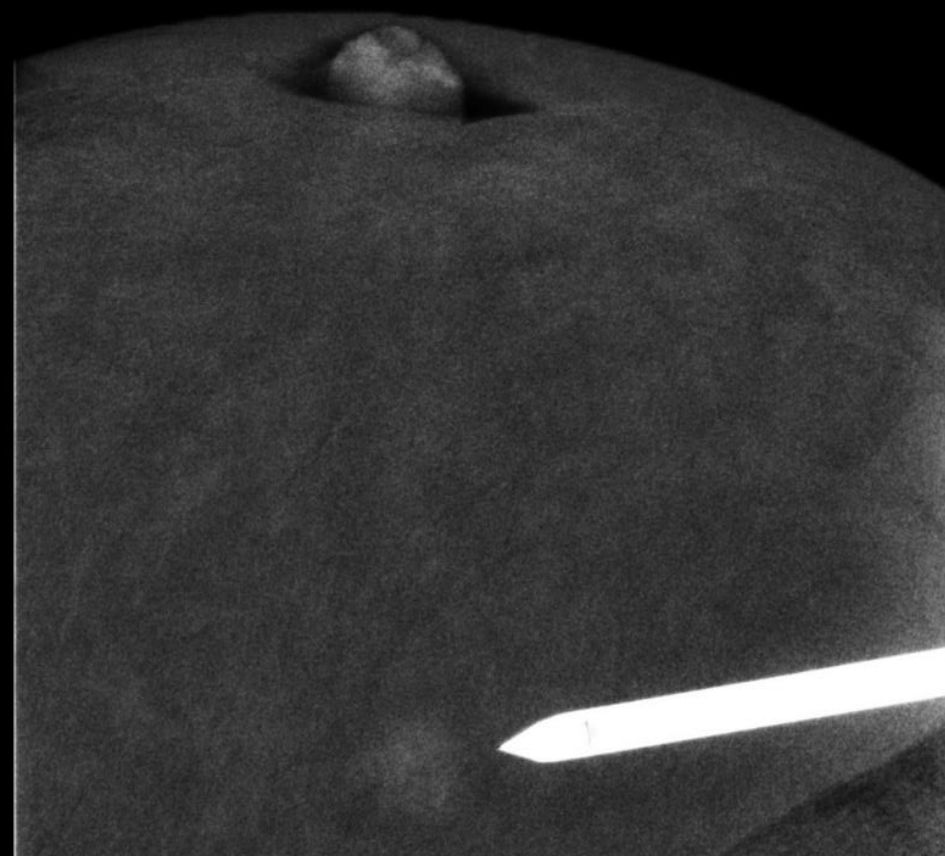
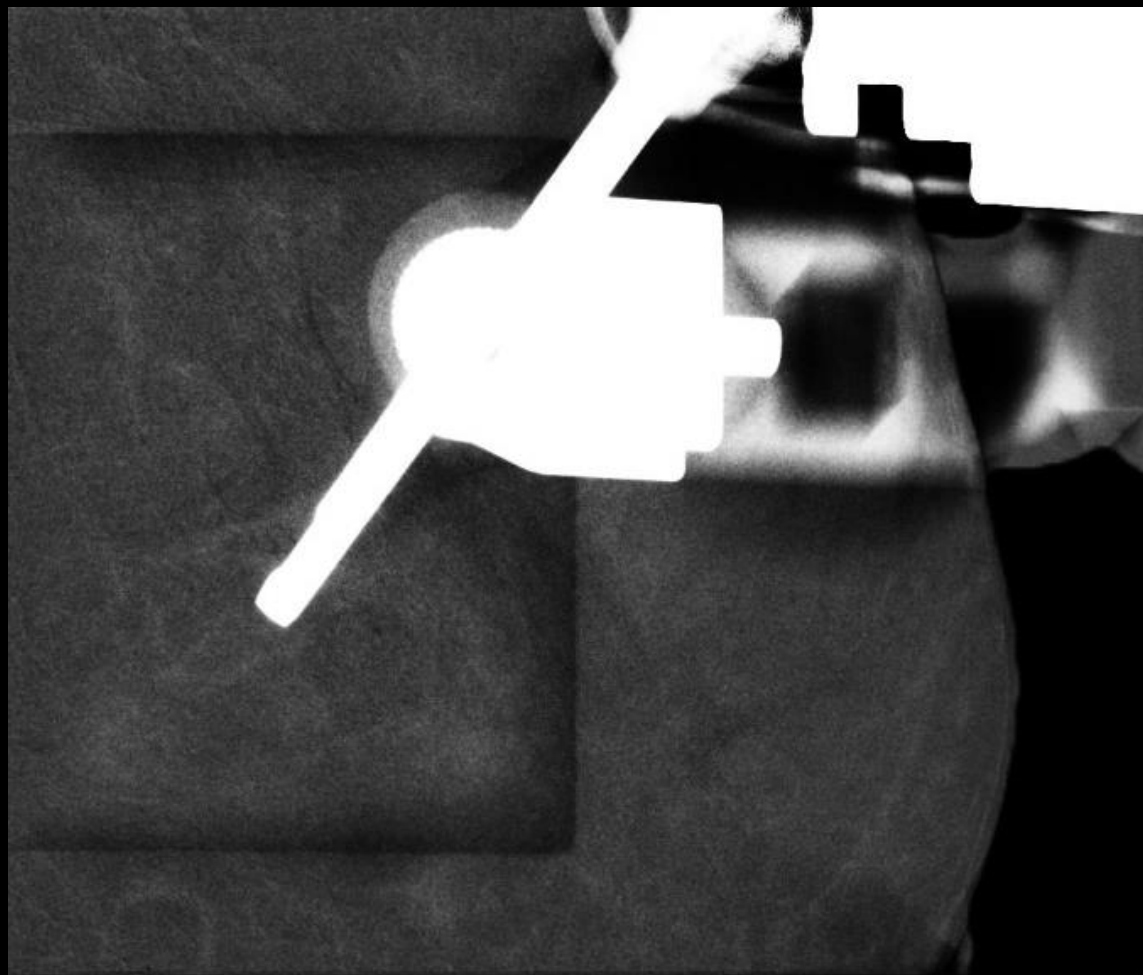


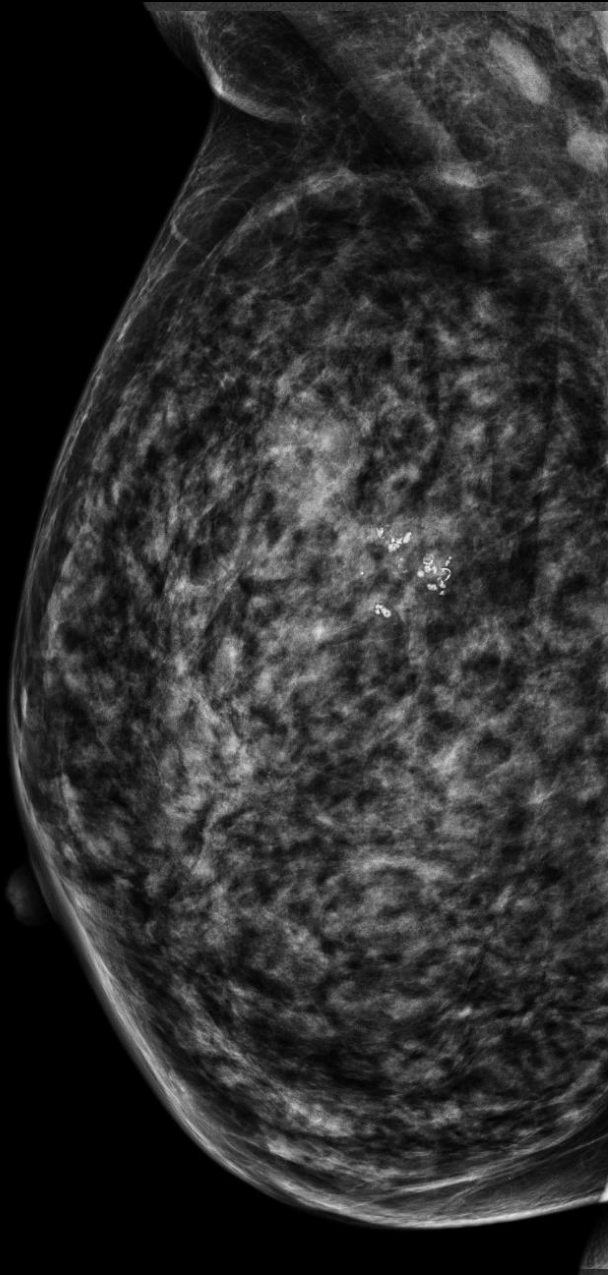
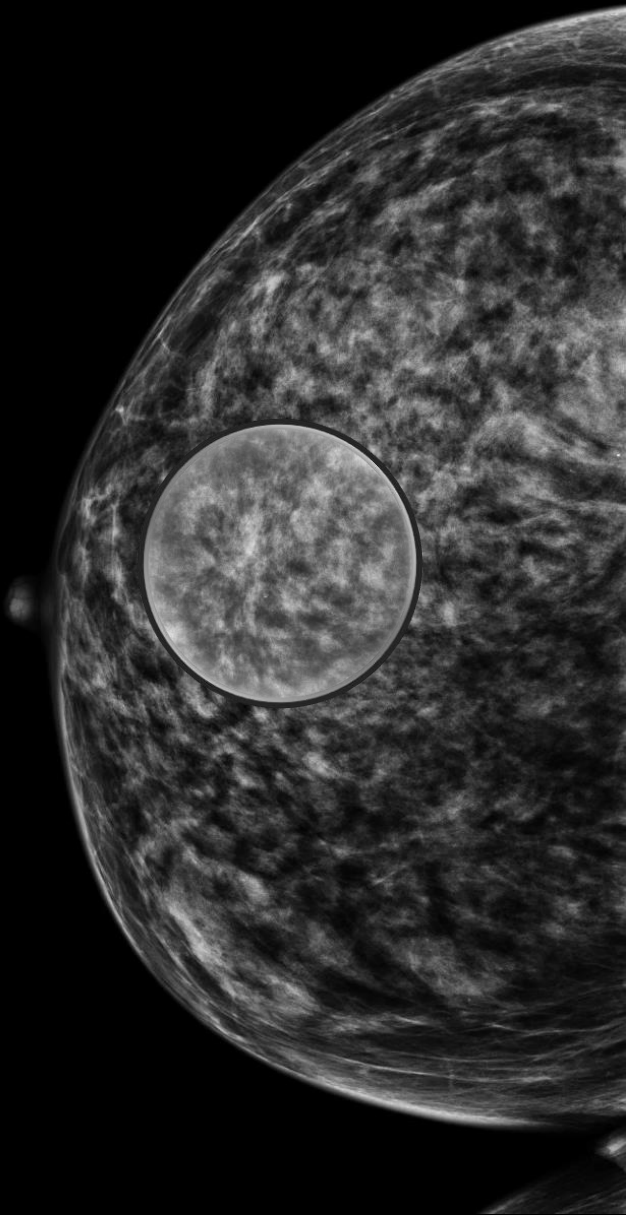


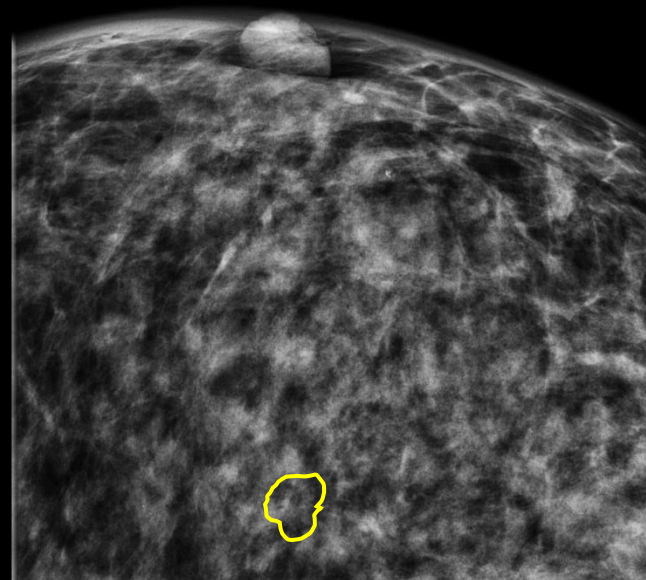
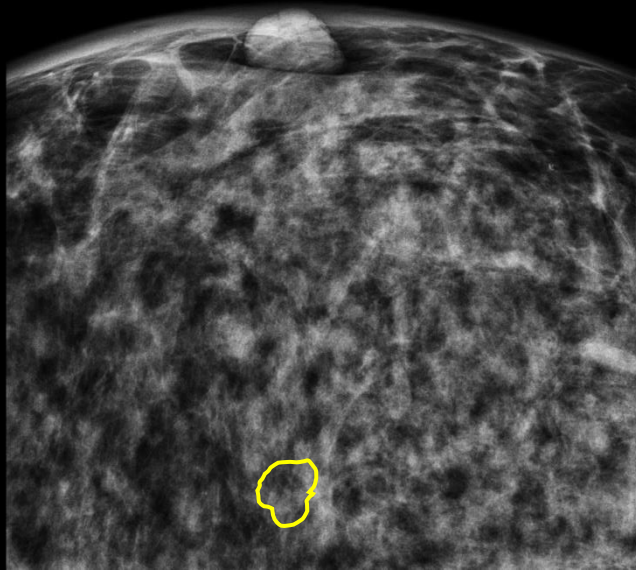
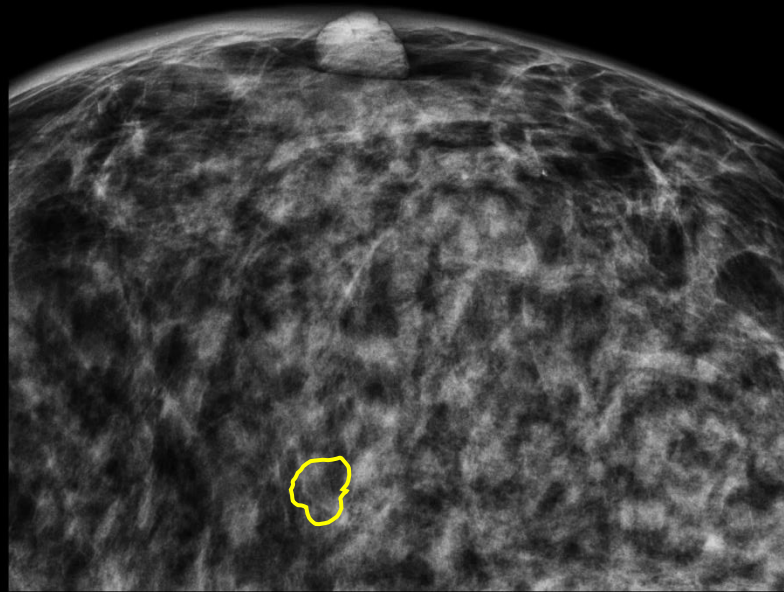
How ?





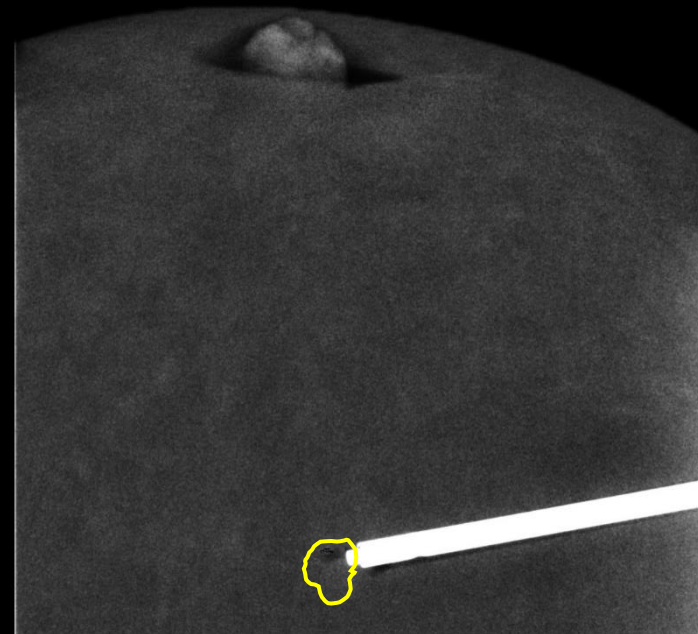
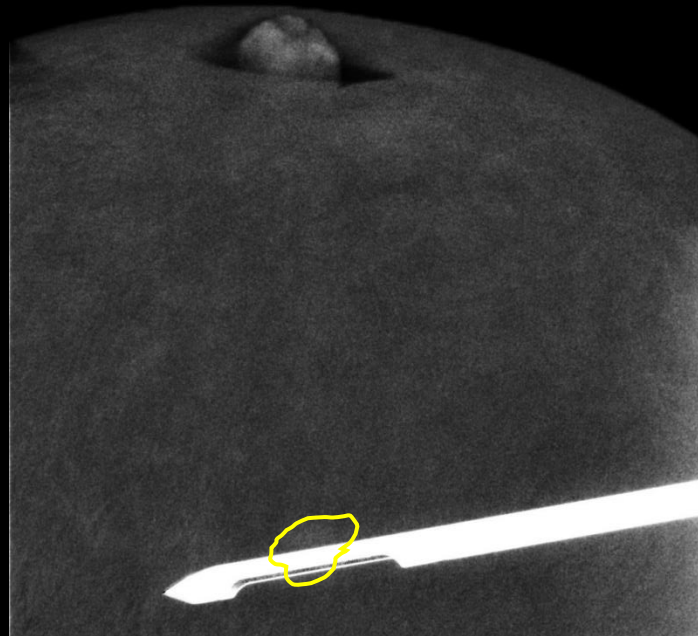
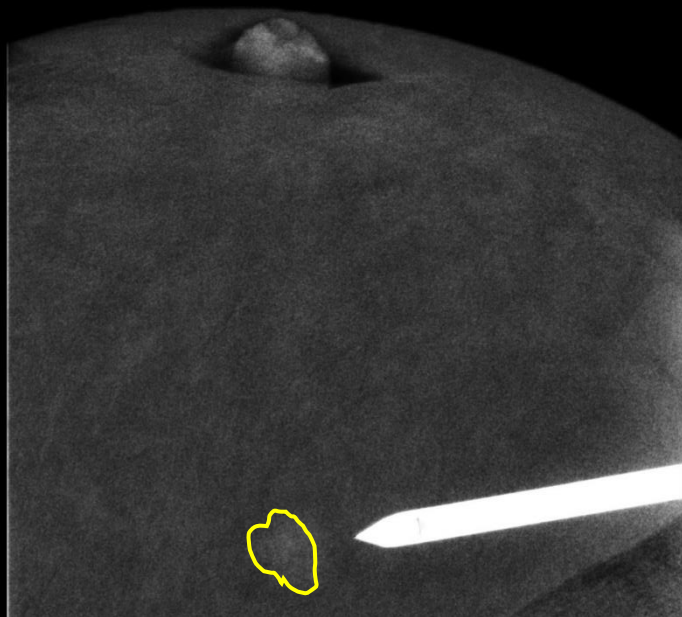


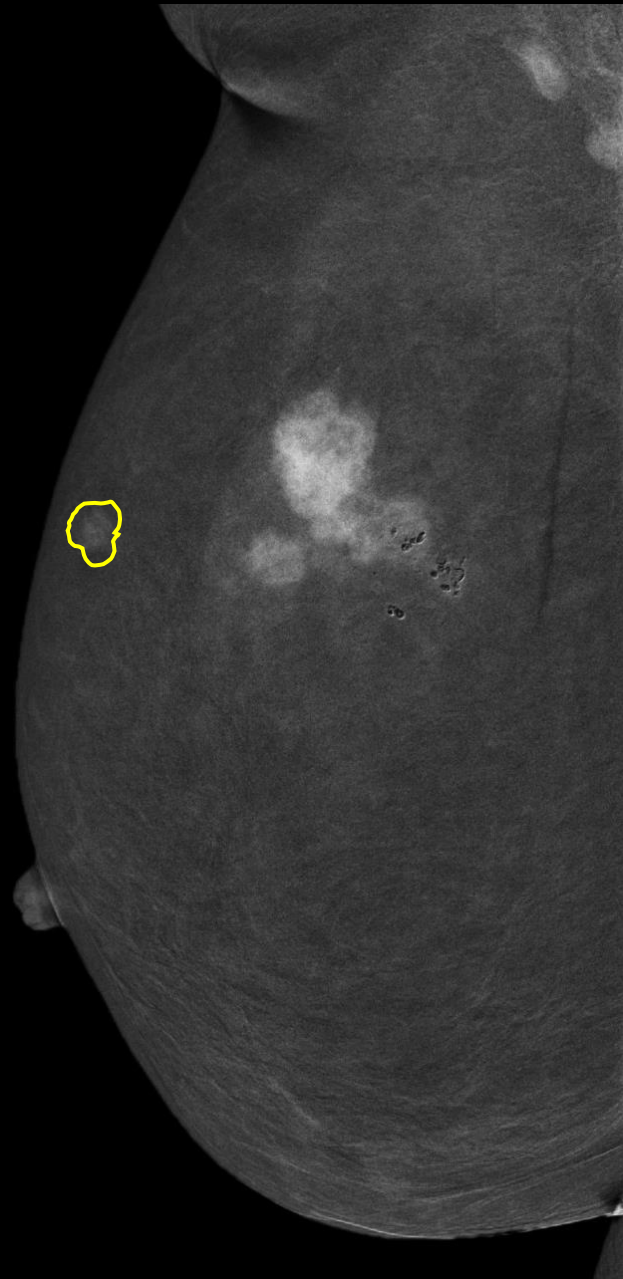
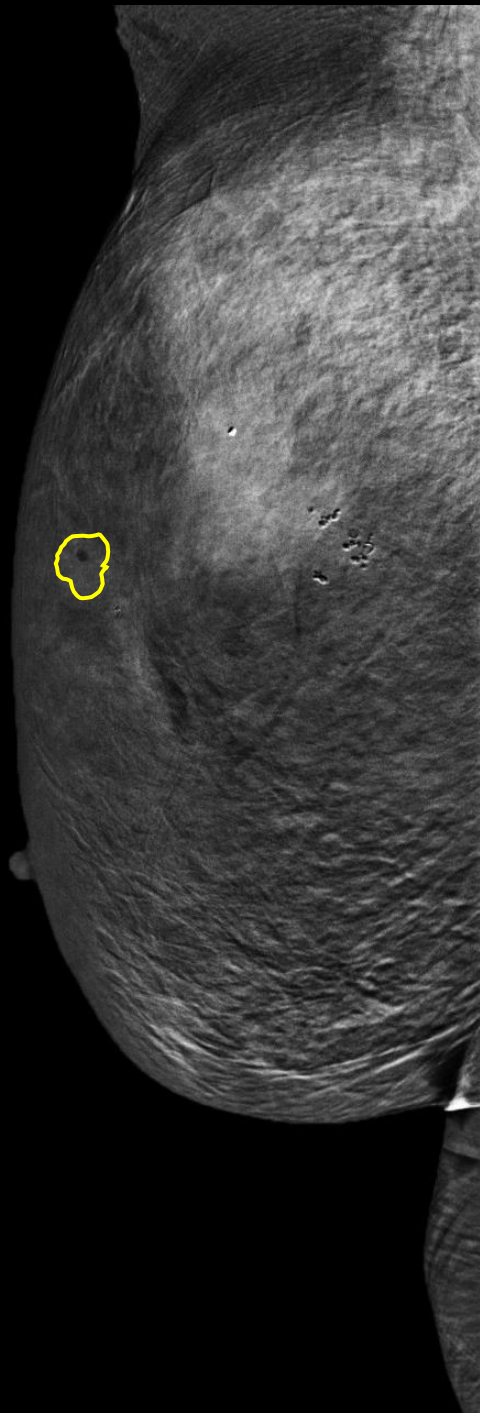
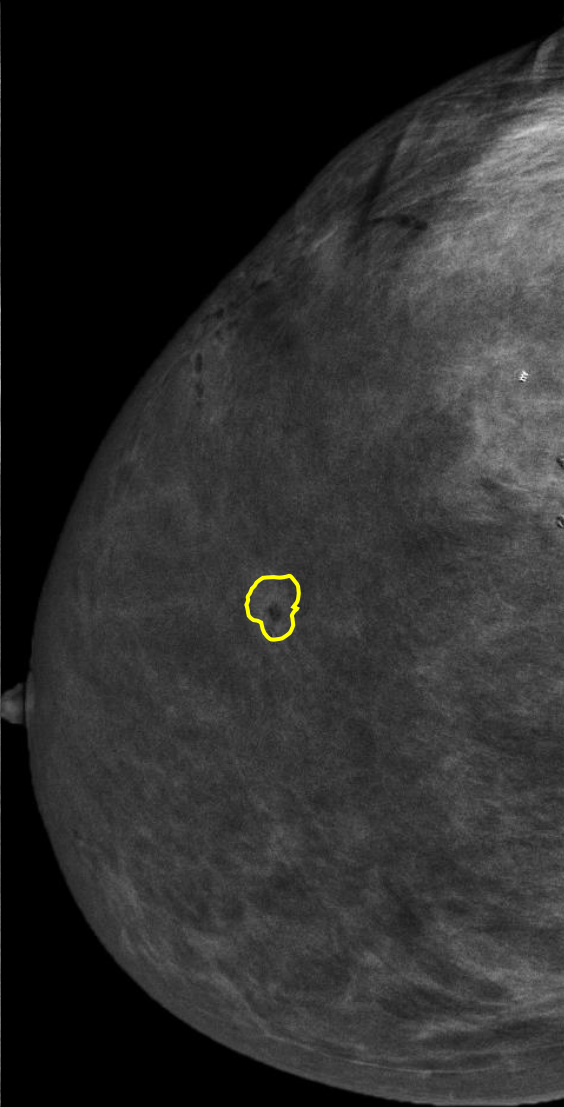
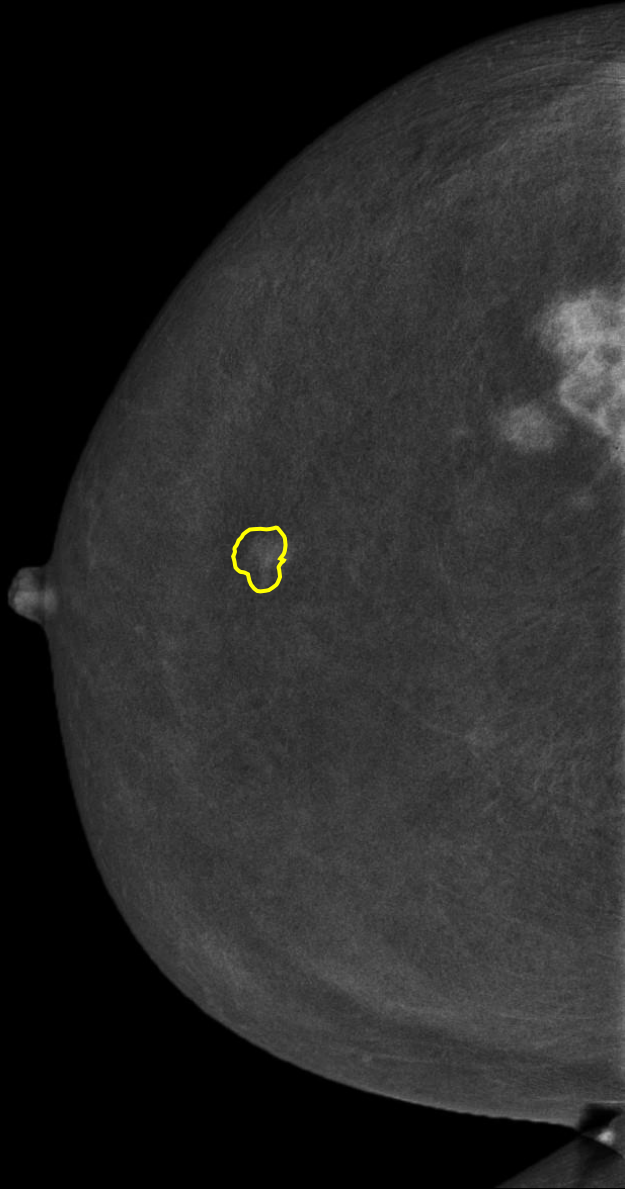


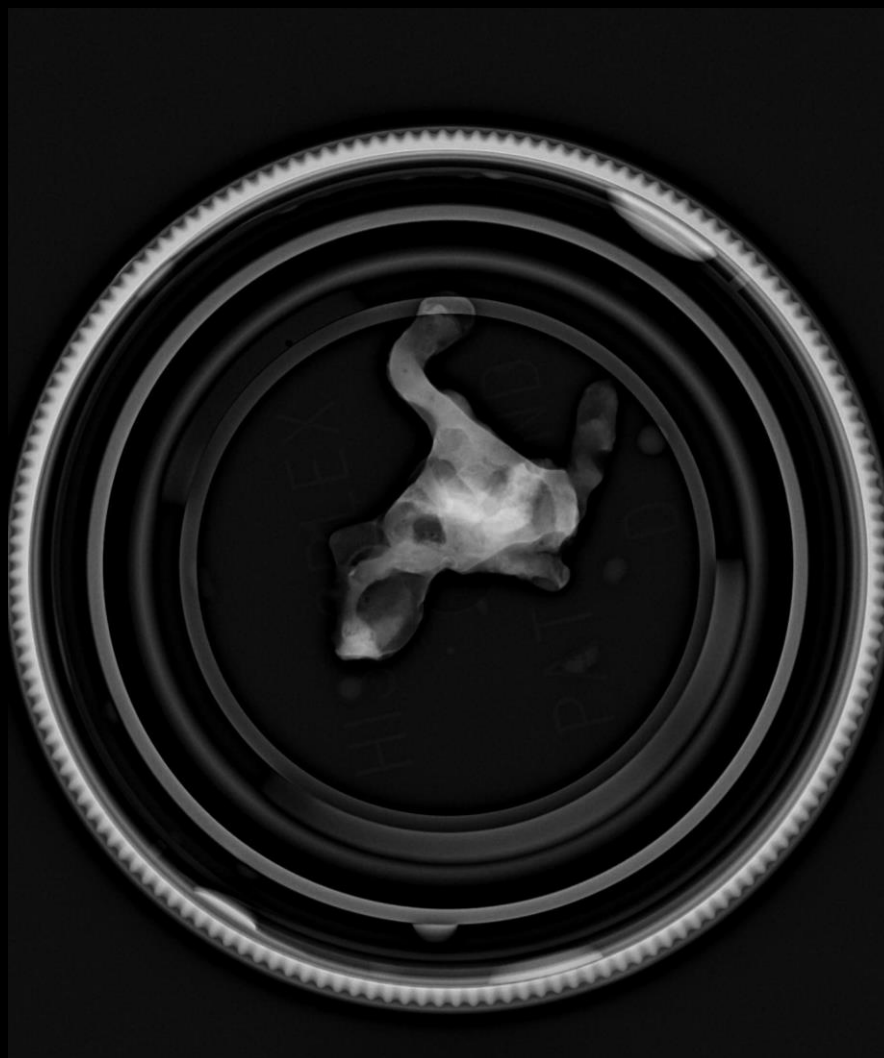


-15°

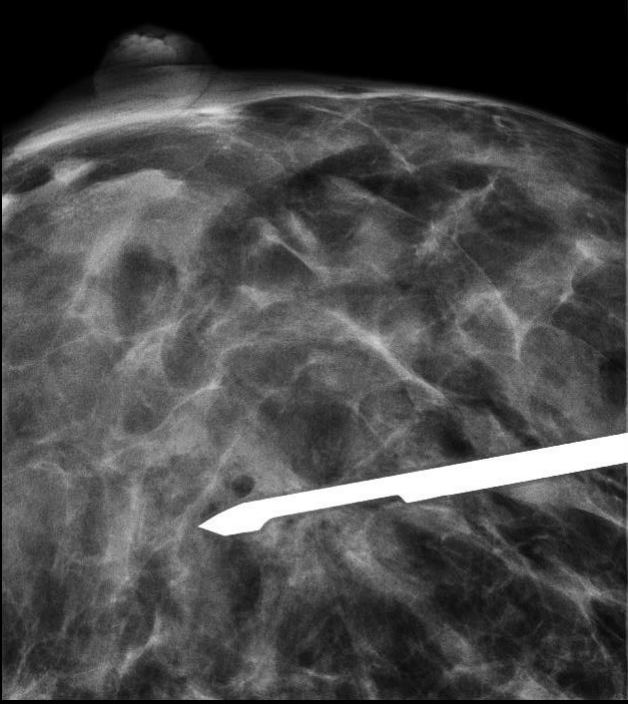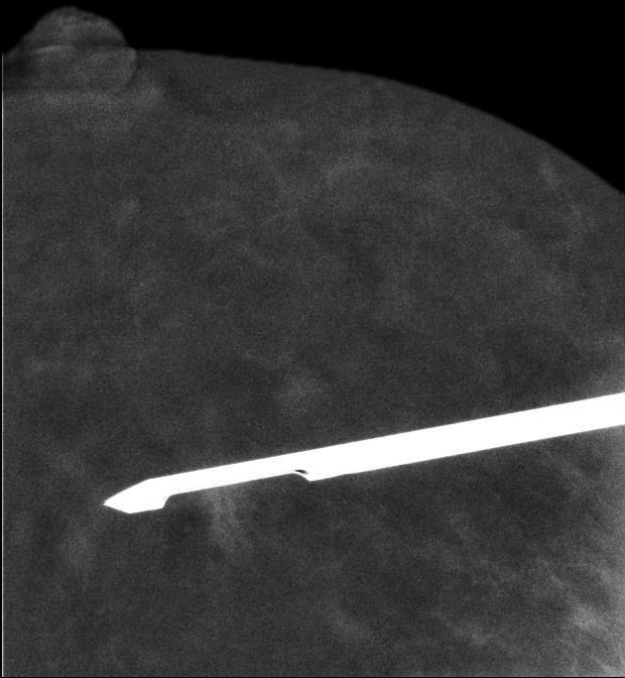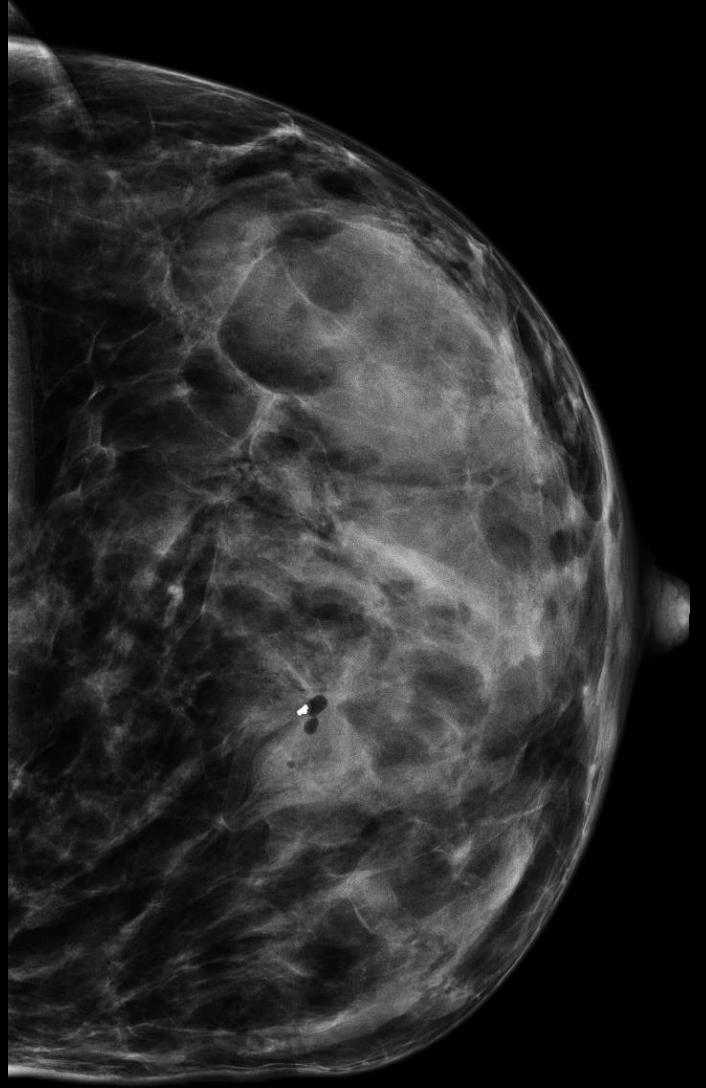
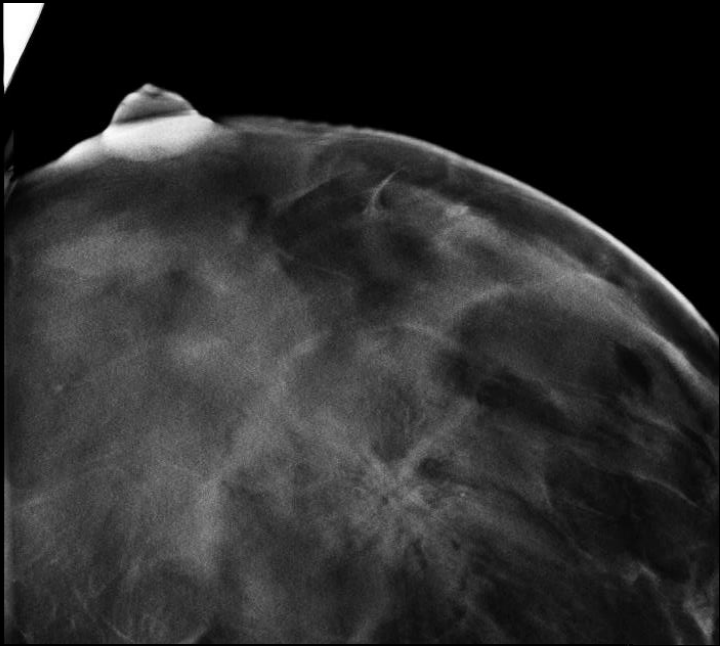
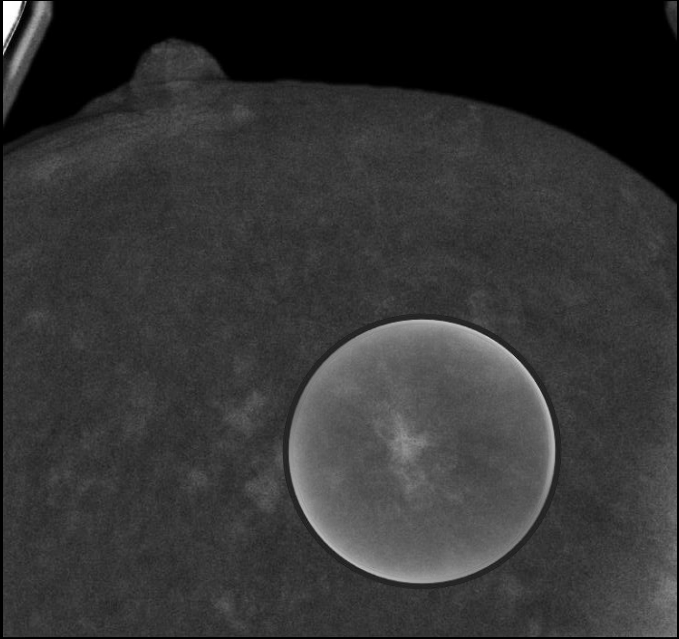
+15°







Alternation with
Tomosynthesis



Vertical vs. Horizontal



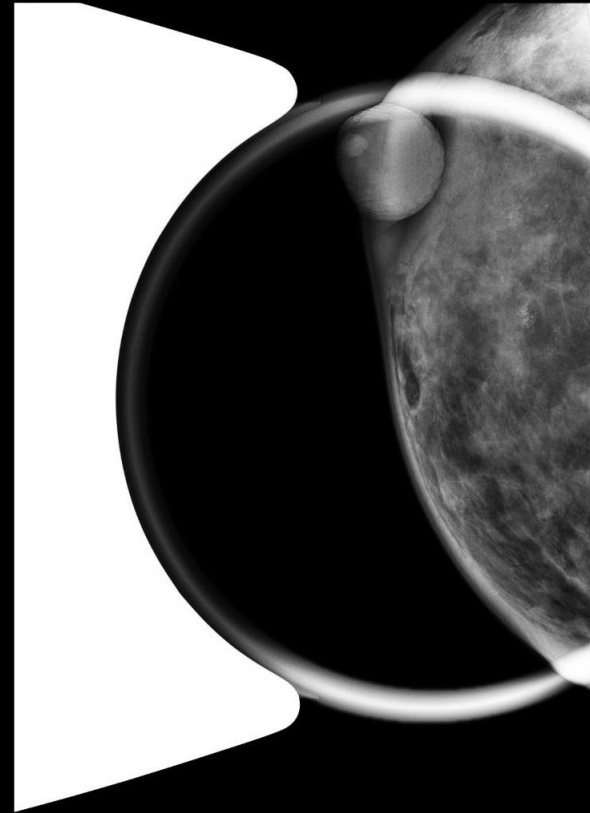

Has Patient Removed Gum/Candy Prior to Procedure

Breast Compressed Thickness = 10.3 mm X = -2.2 Y = 6.0 Z = 4.0

OFF SET _____

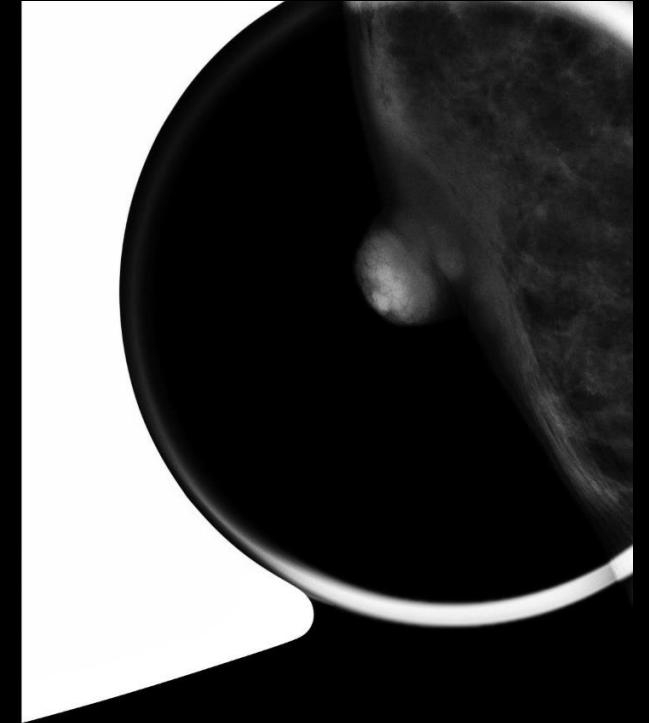
| X | Y | Z | Number Taken |
|---|---|----|--------------|
| 0 | 0 | -2 | ✓ |
| 0 | 0 | 0 | ✓ |

Vacuum Assist 9 Gauge or 12 Gauge
 Standard Petite



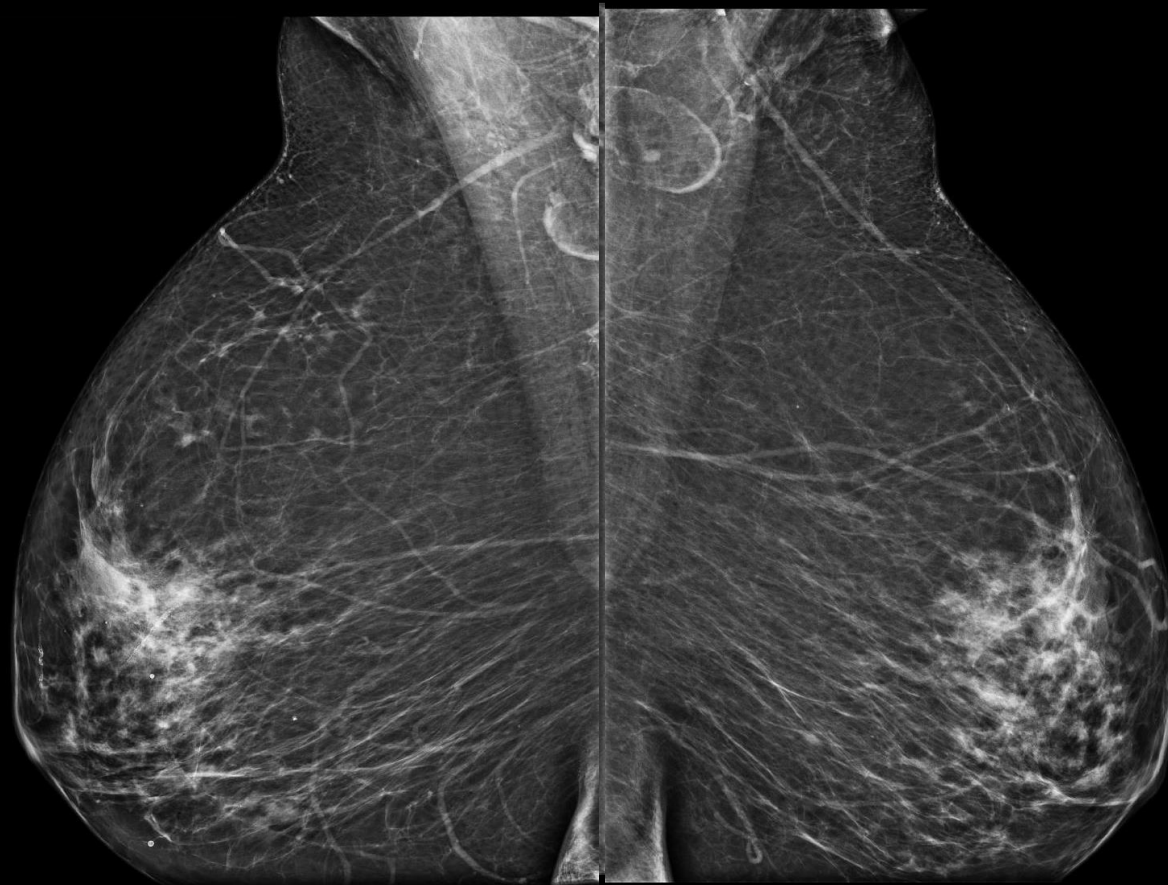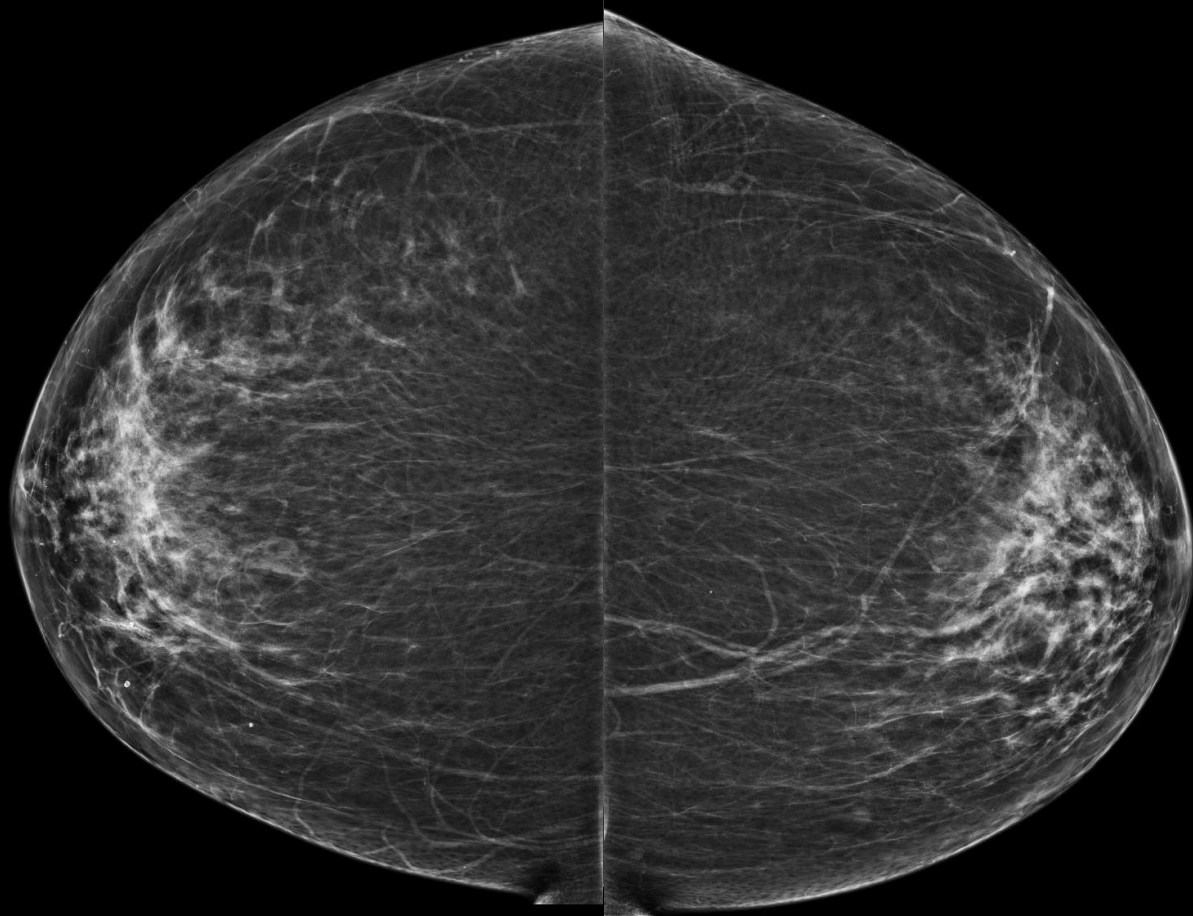
RMSCC

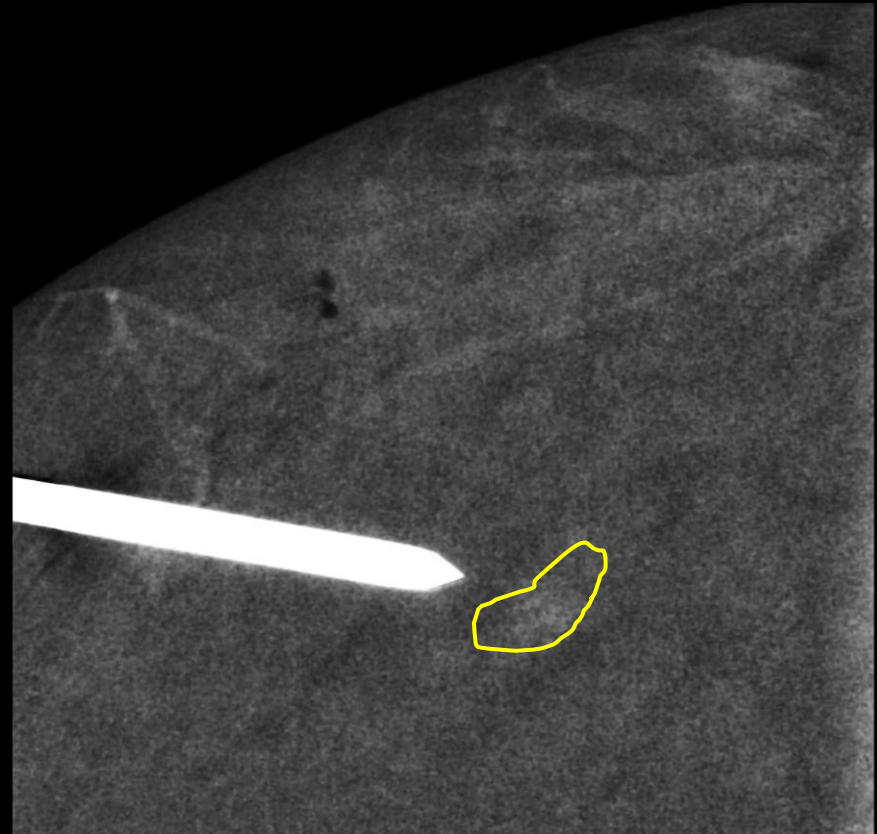
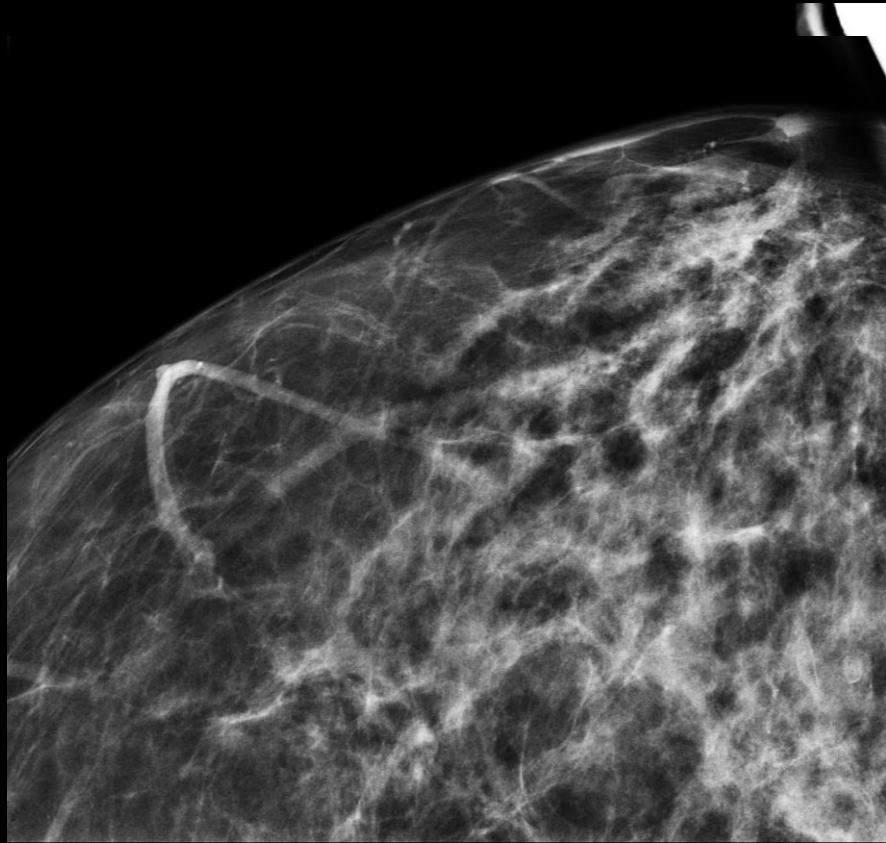
Compression Force: 8.05 krf
Body Part Thickness: 13 ←
Degree of Obliquity: 0
FOV Dimension: 229\191
KVP:28.99
mAs:15
Target:MOLYBDENUM
F/u mammo + us Obsp

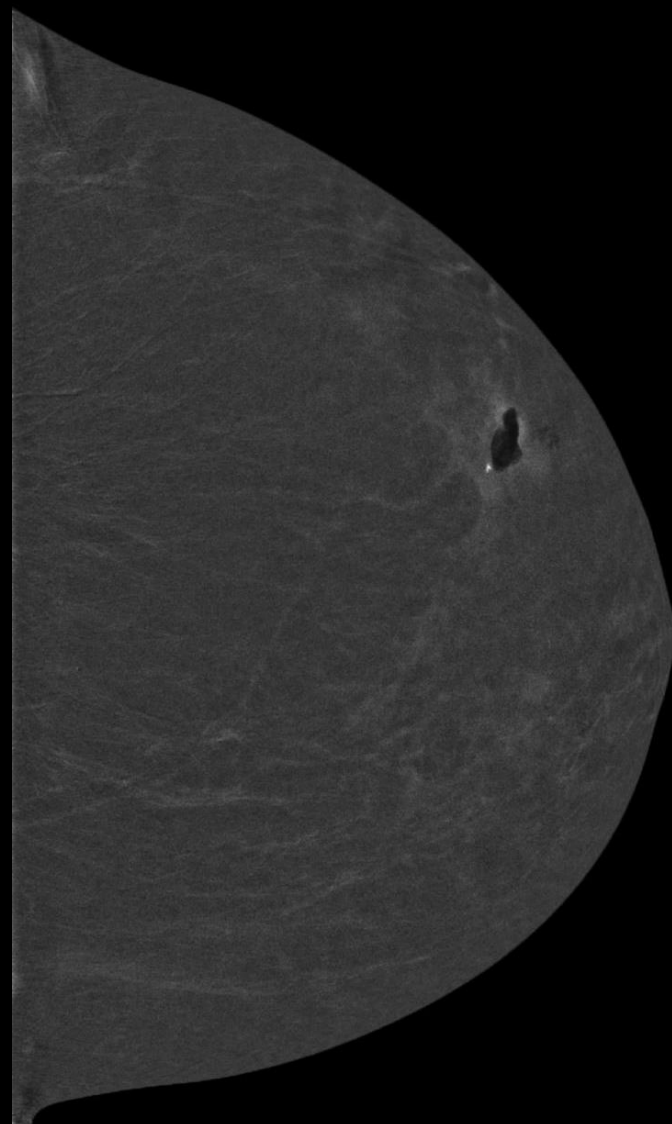
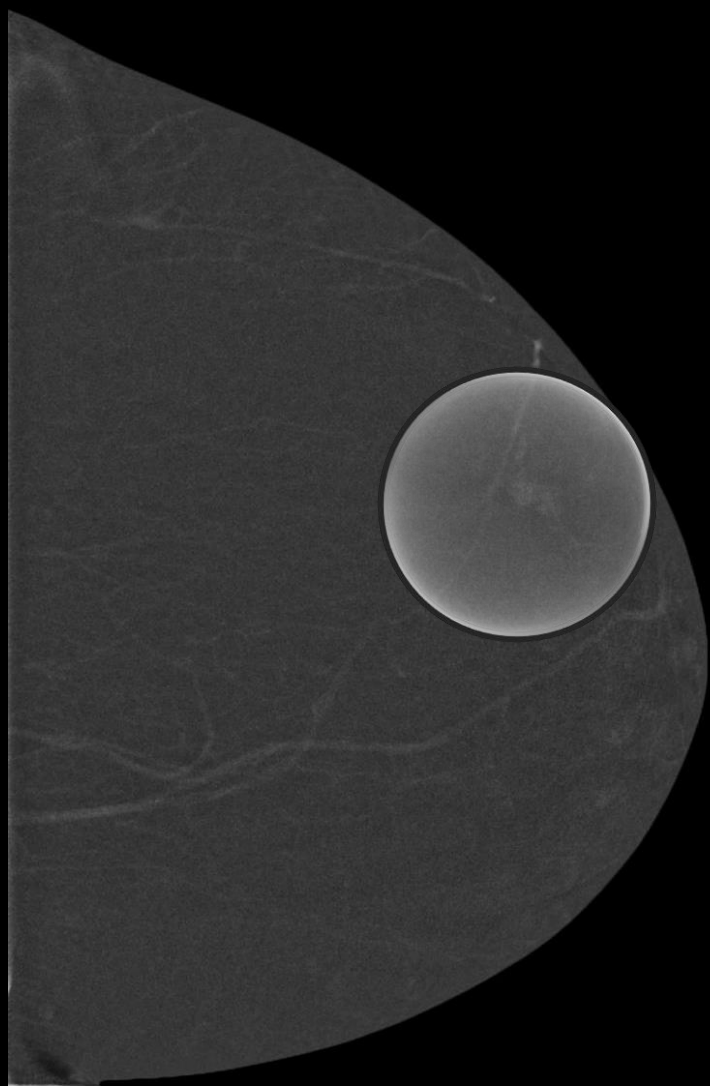


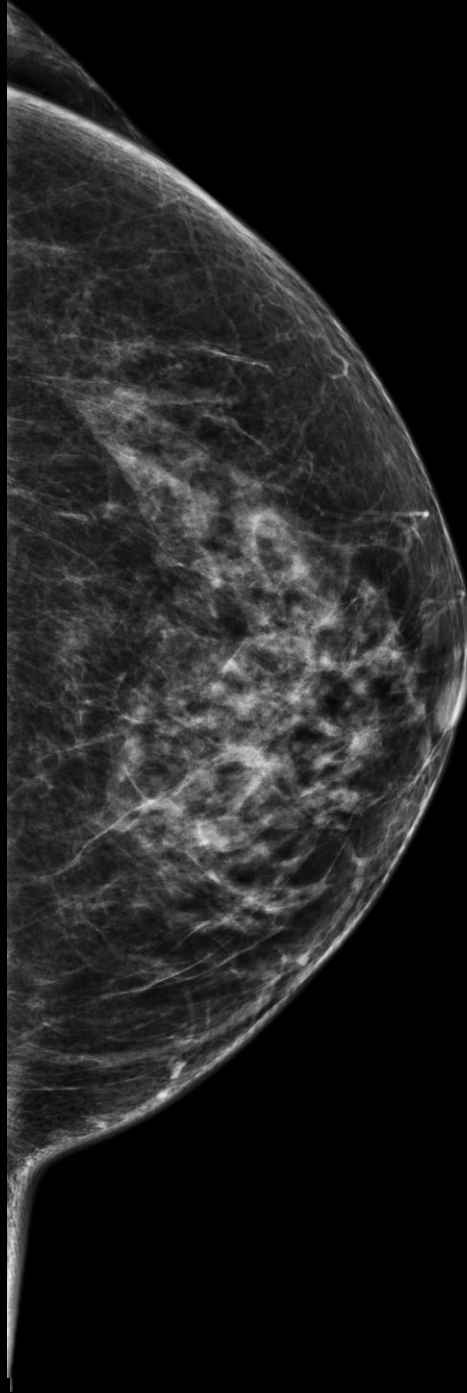
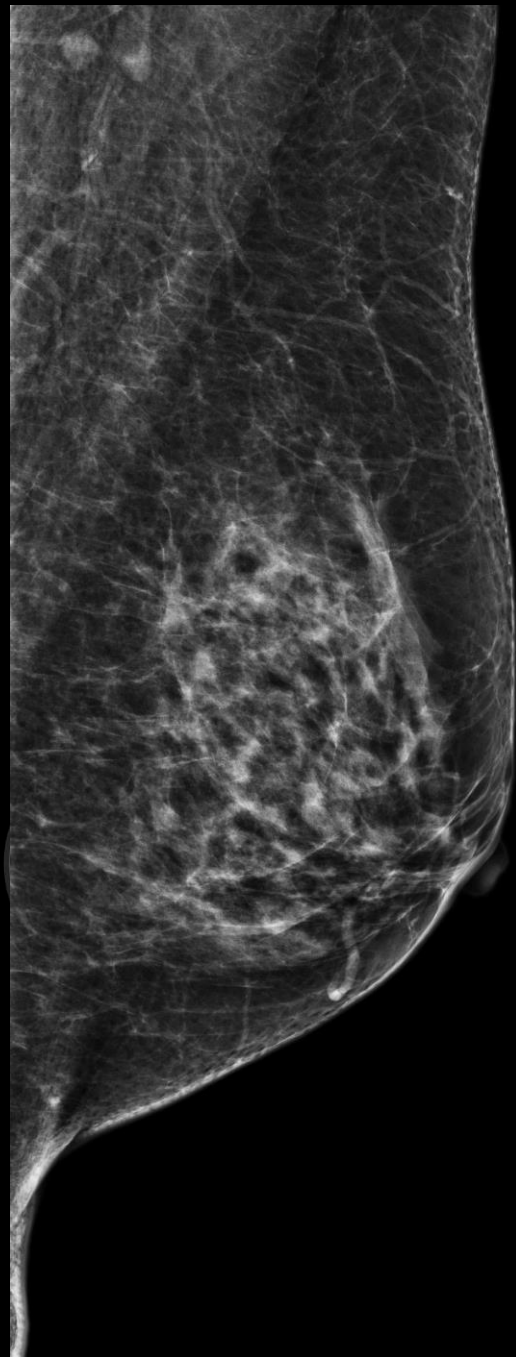
RMSML

Compression Force: 8.36 krf
Body Part Thickness: 9.7 ←
Degree of Obliquity: 90
FOV Dimension: 229\191
KVP:28.99
mAs:11
Target:MOLYBDENUM
F/u mammo + us Obsp

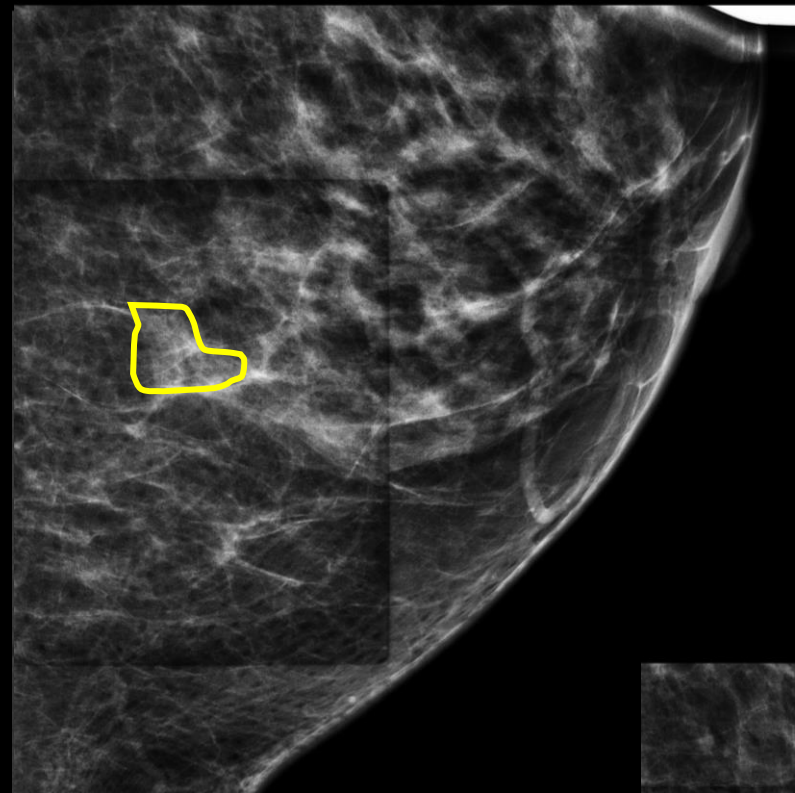
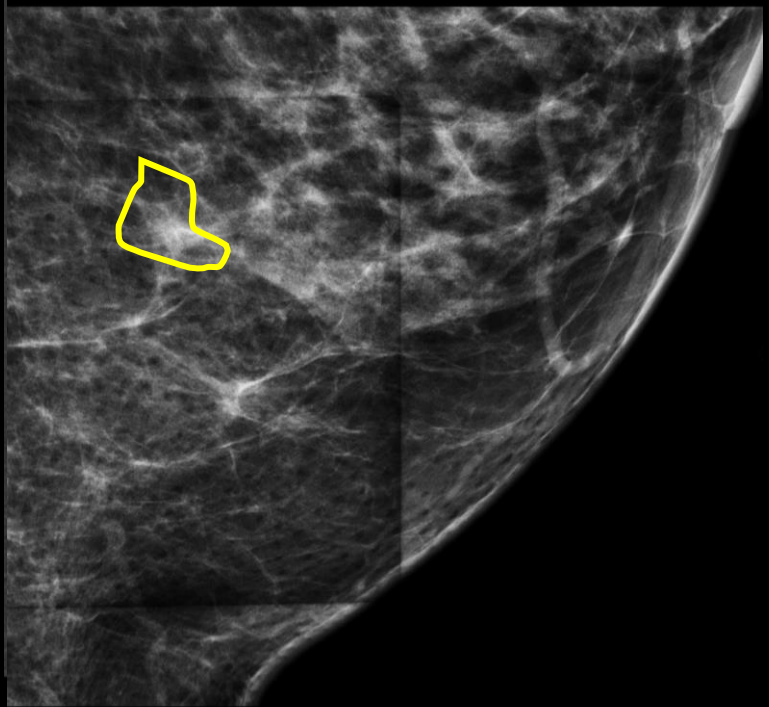




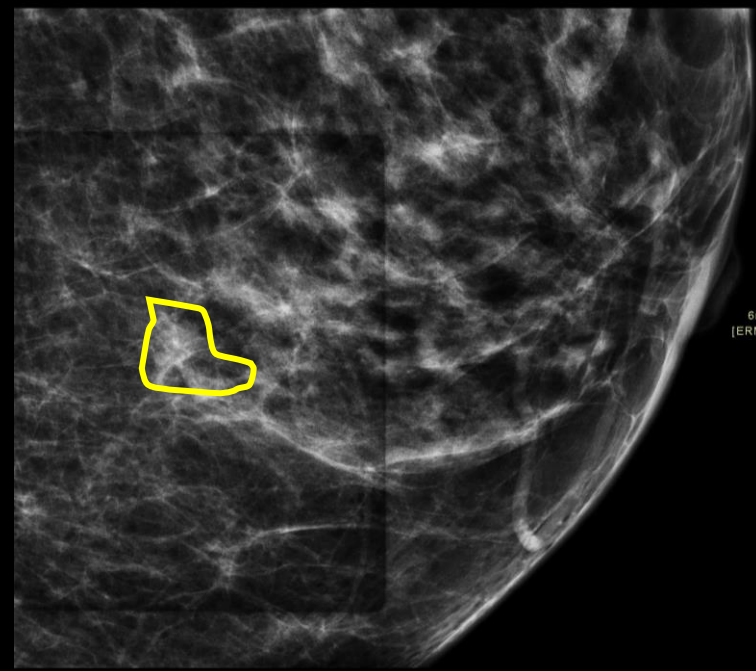


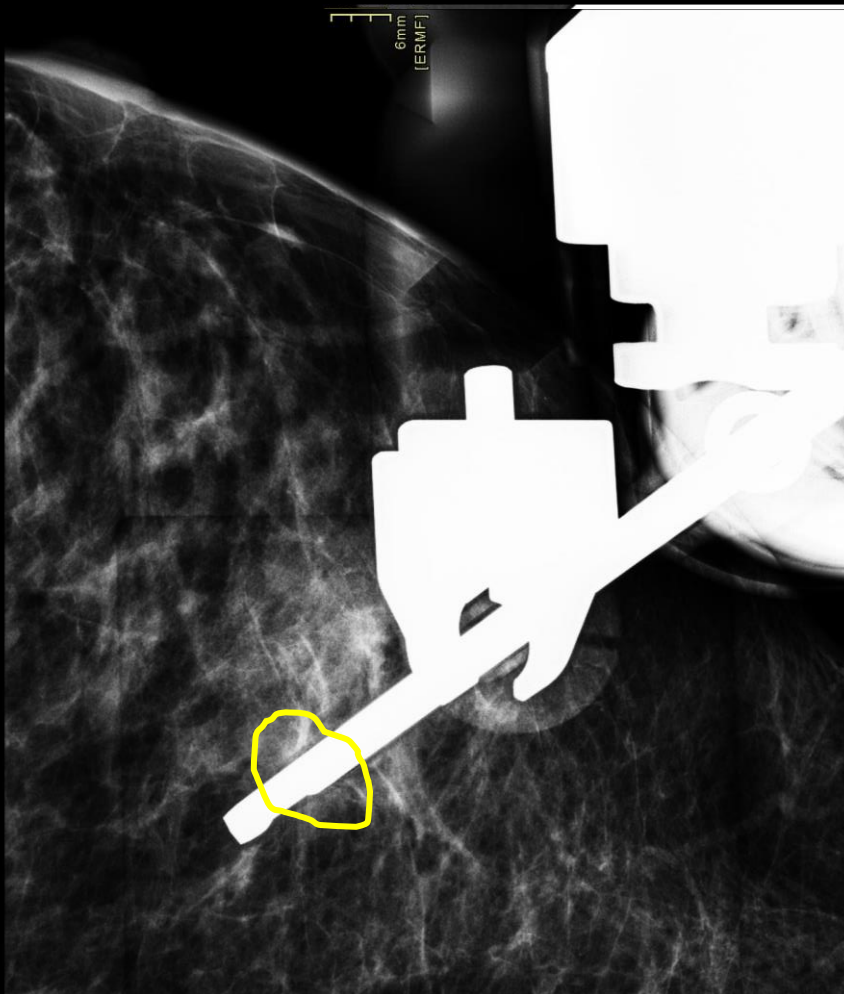
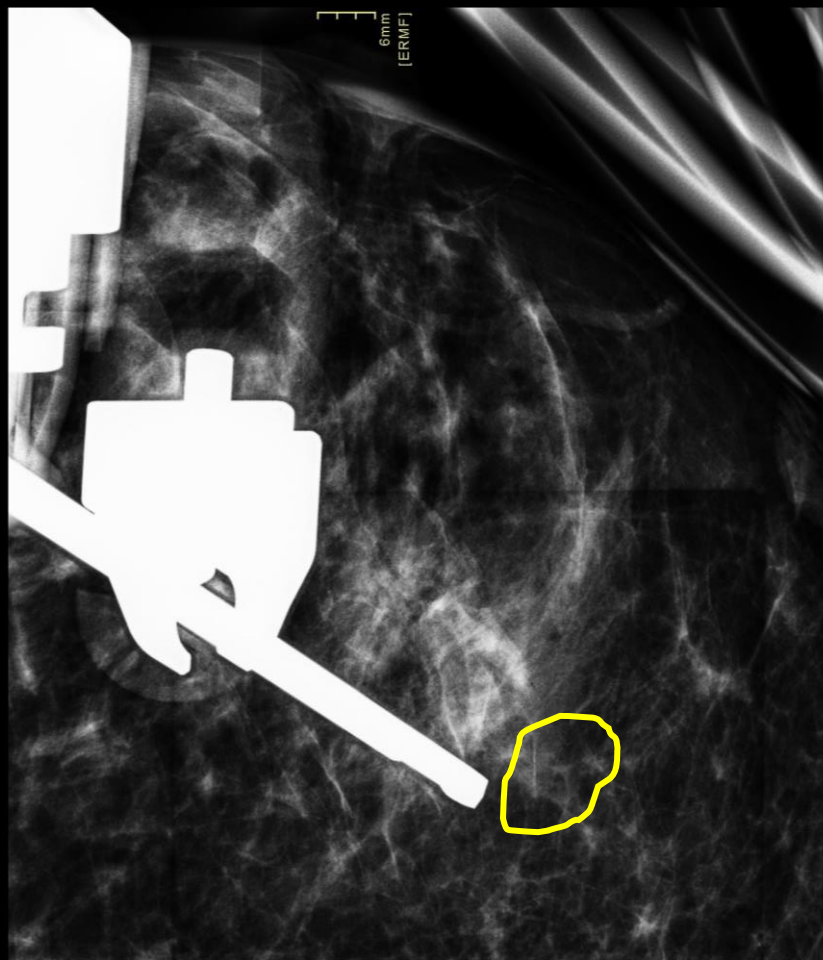


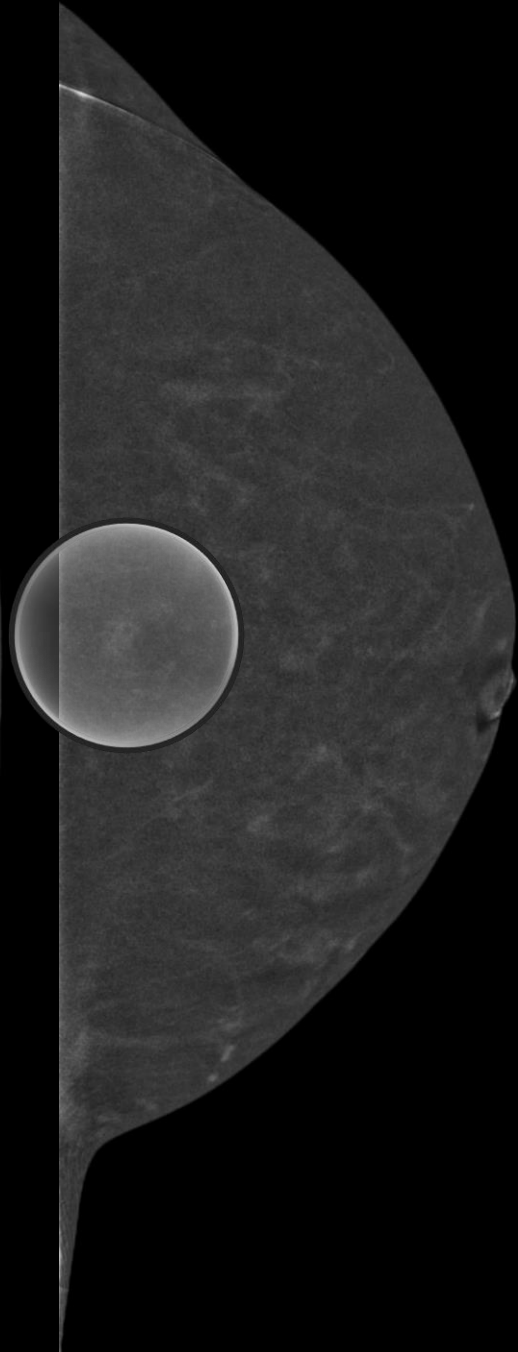
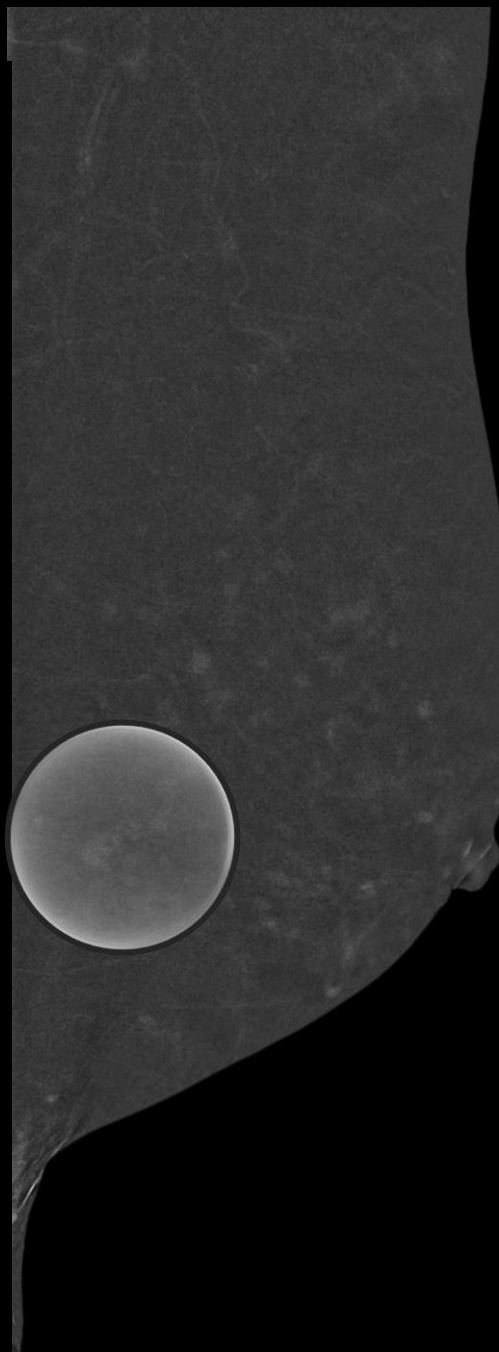
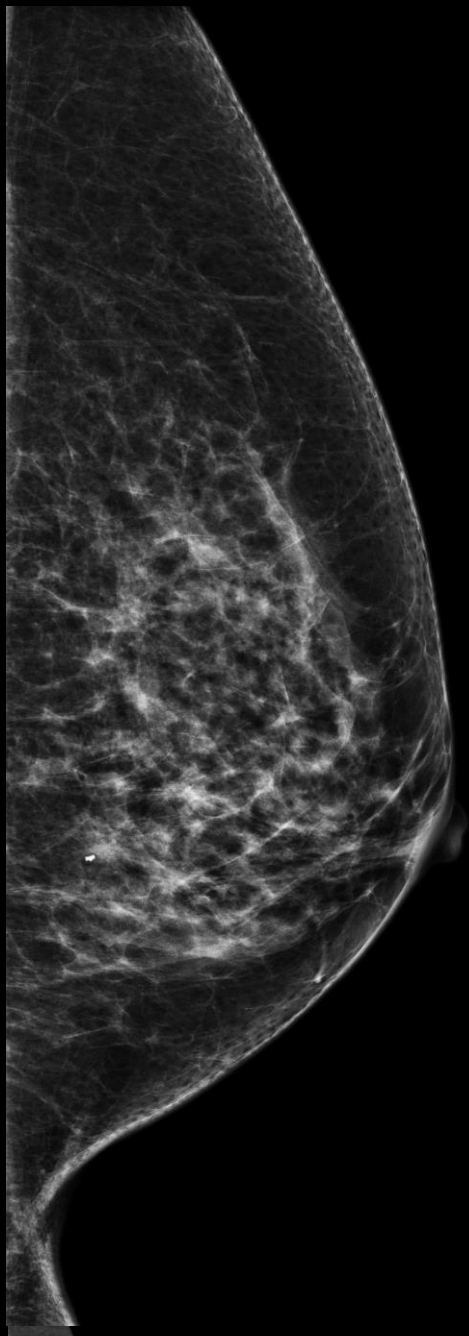
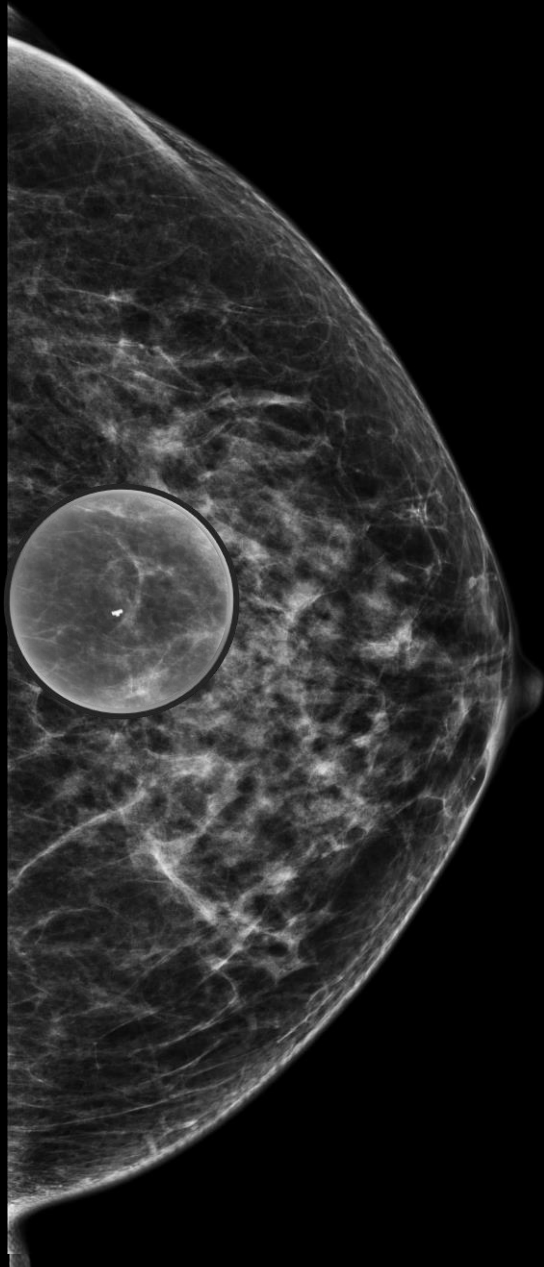
+15°

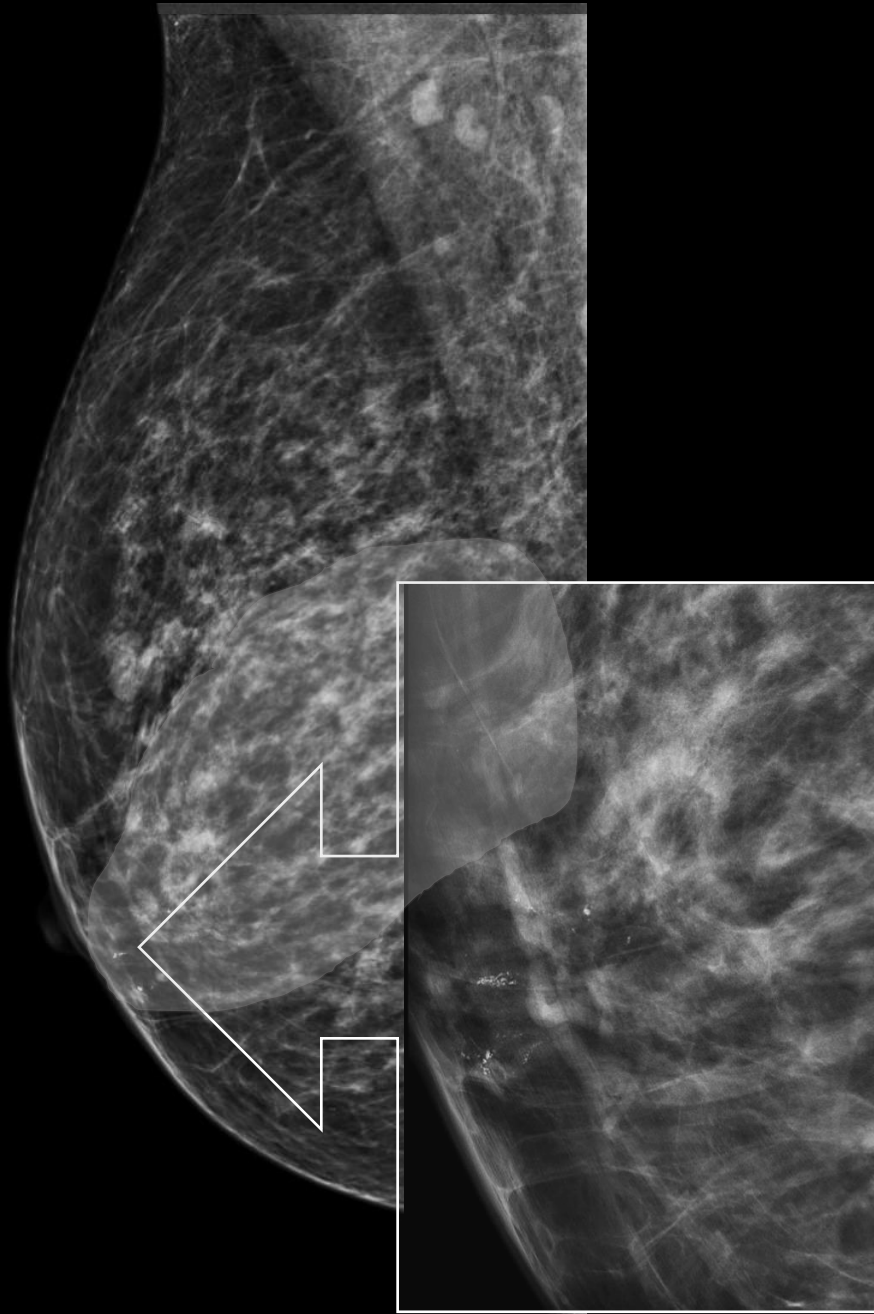
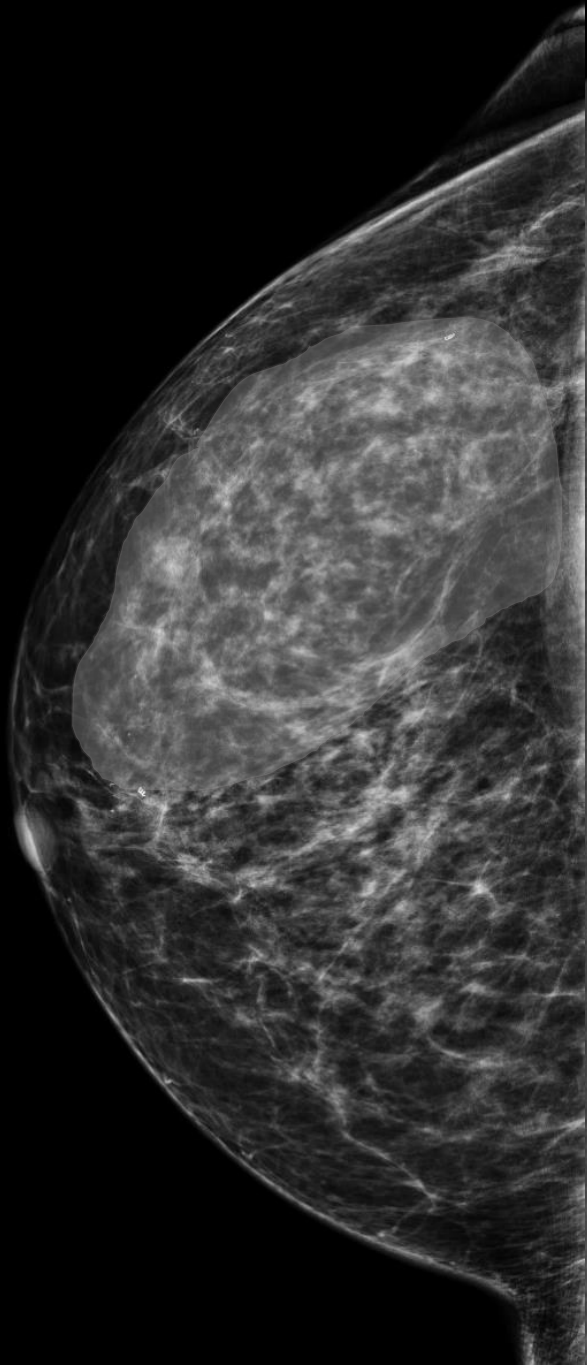


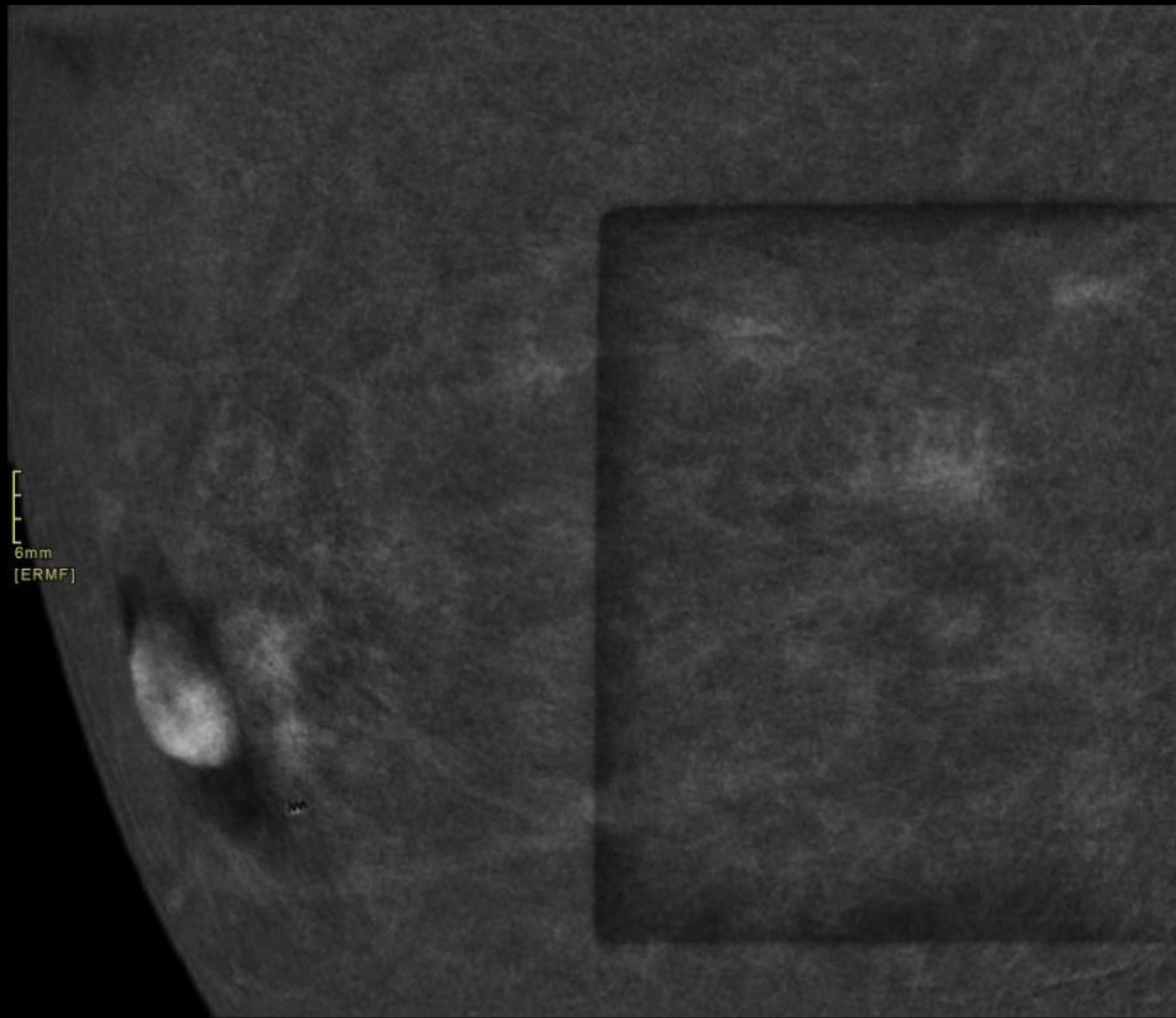
-15°

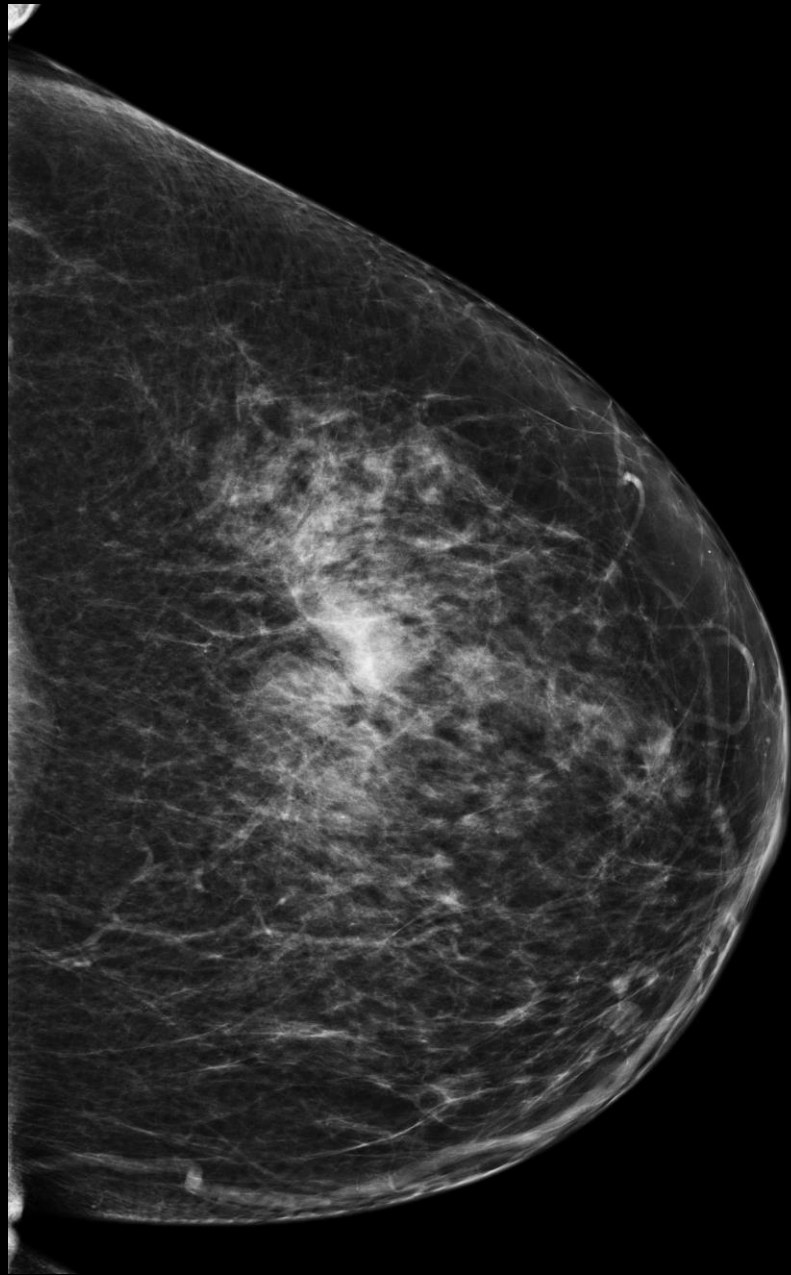
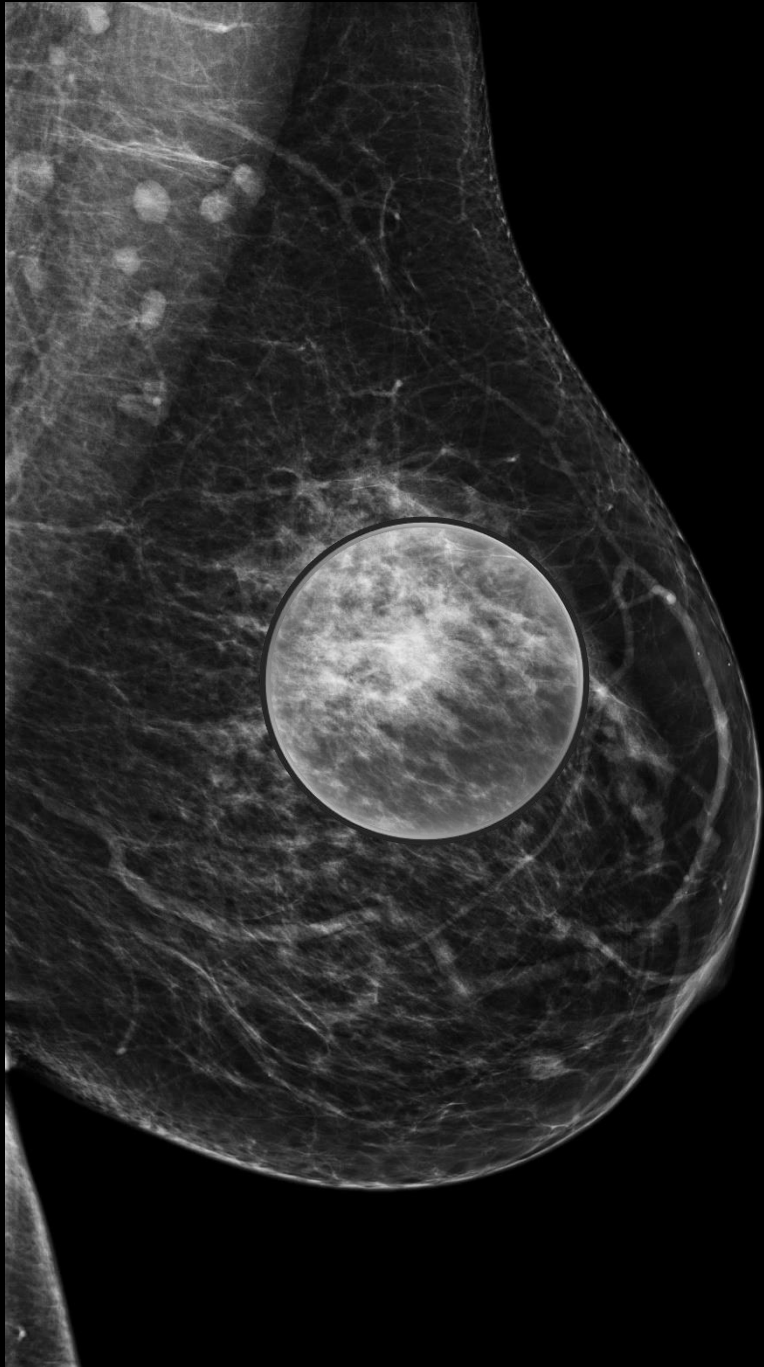


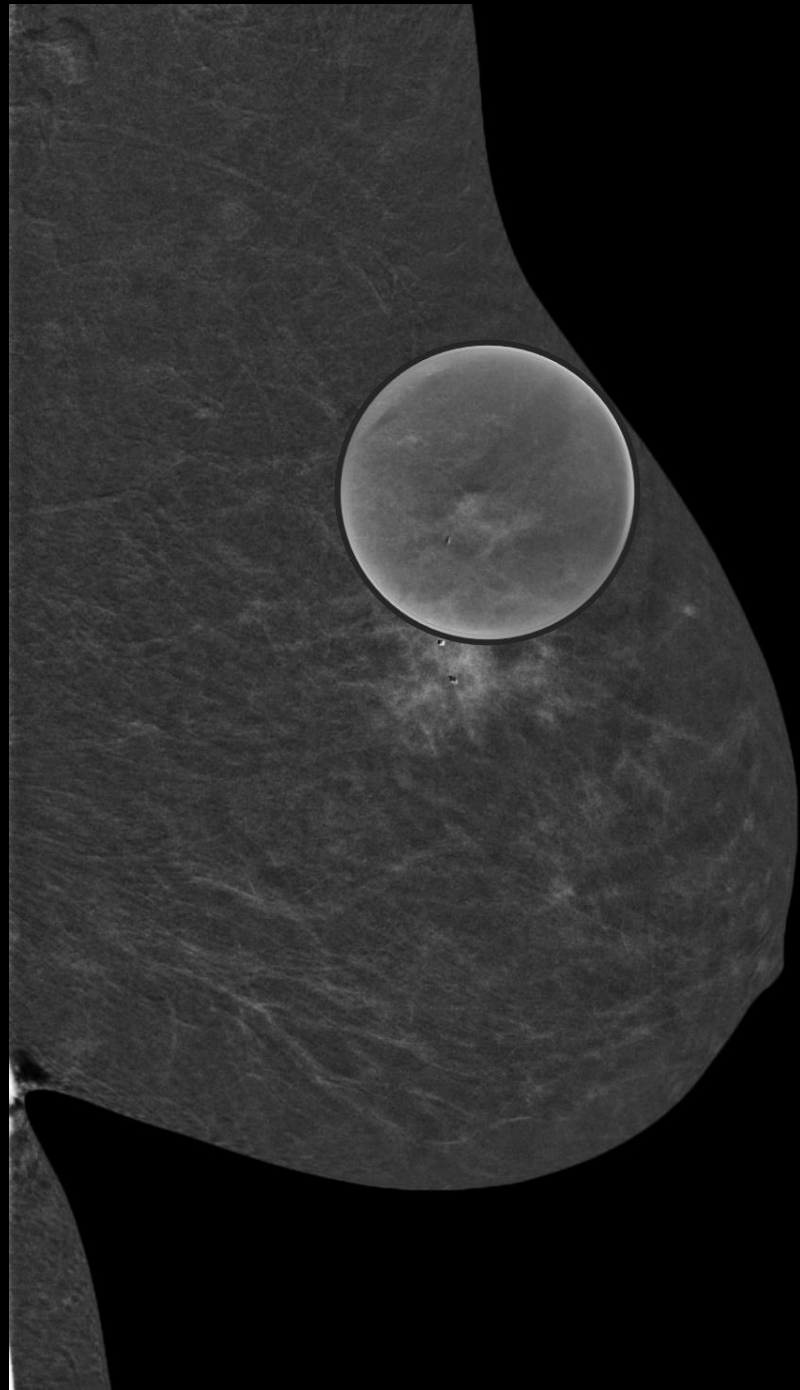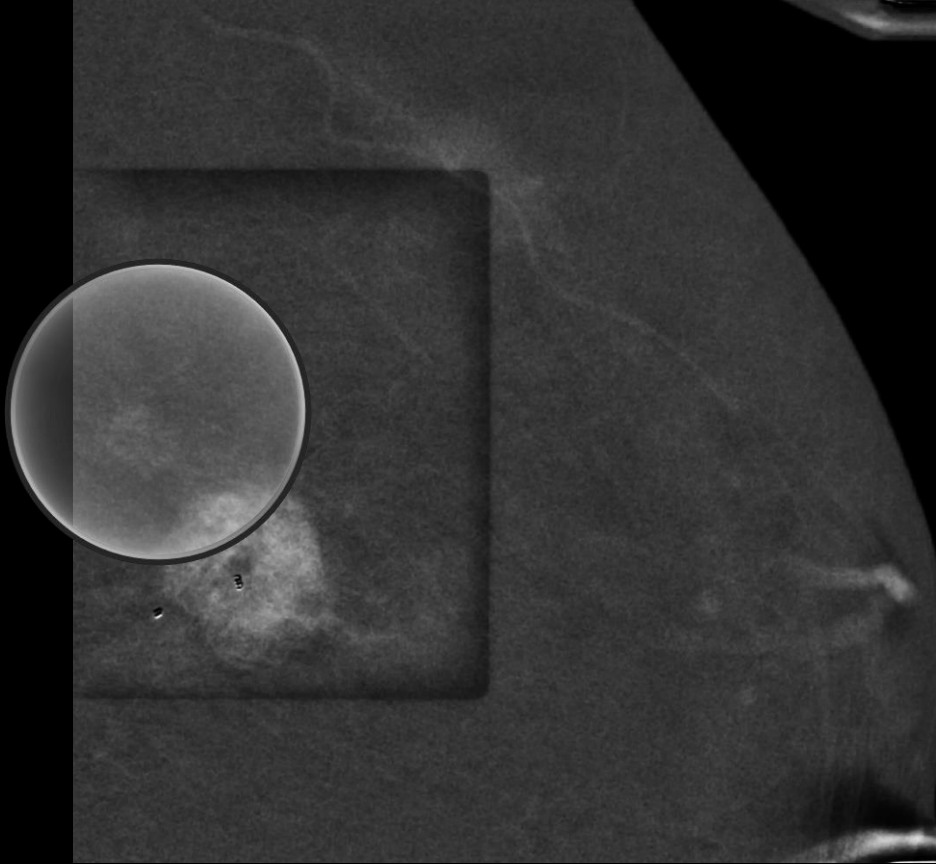






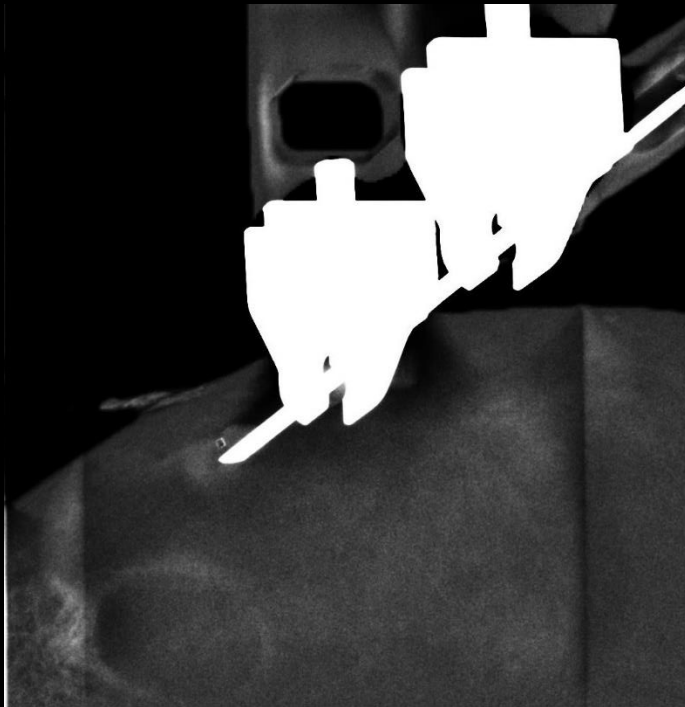
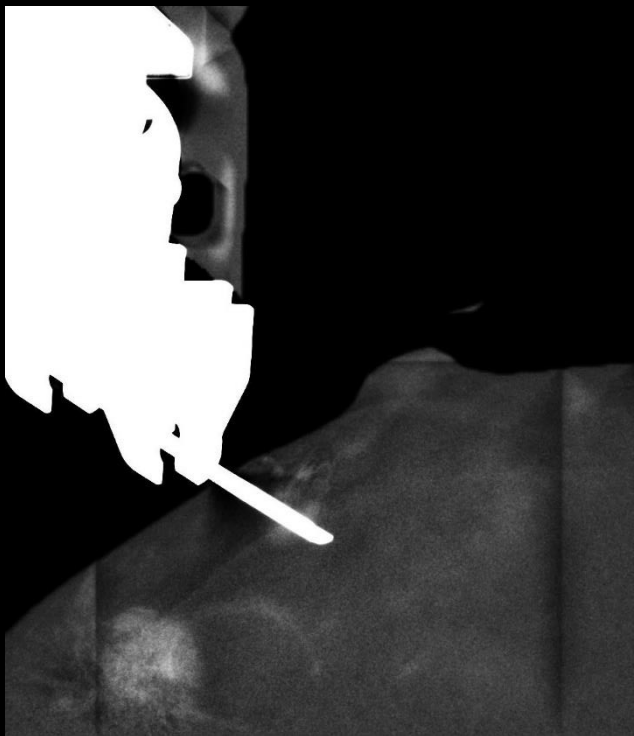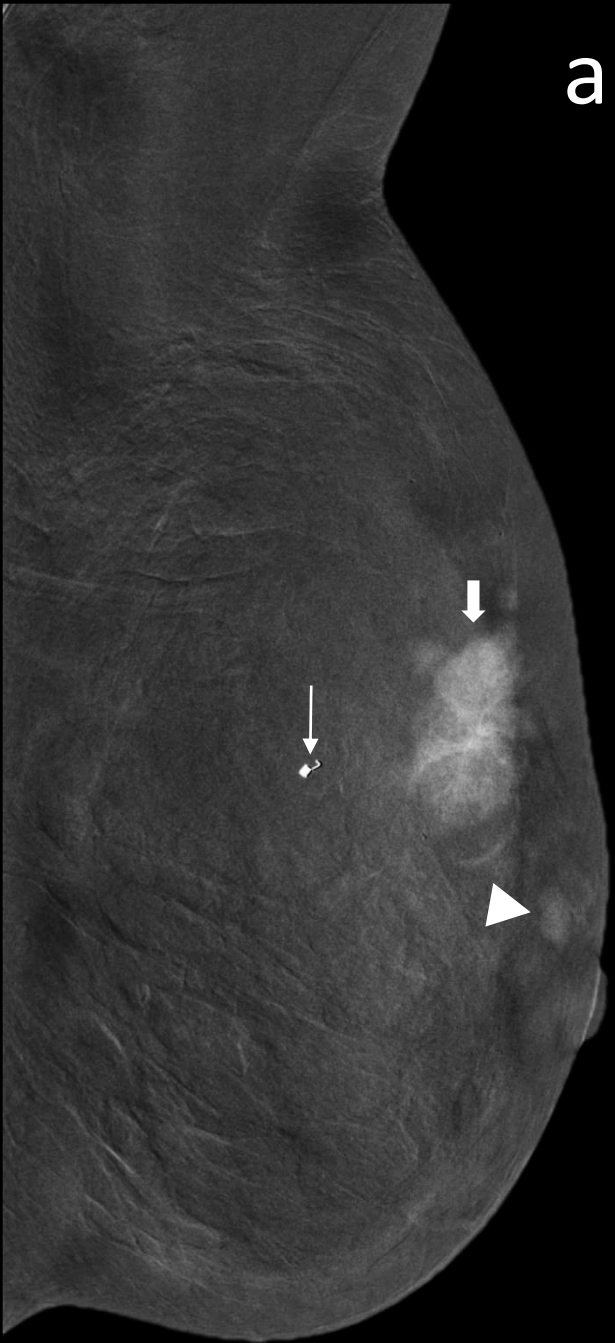




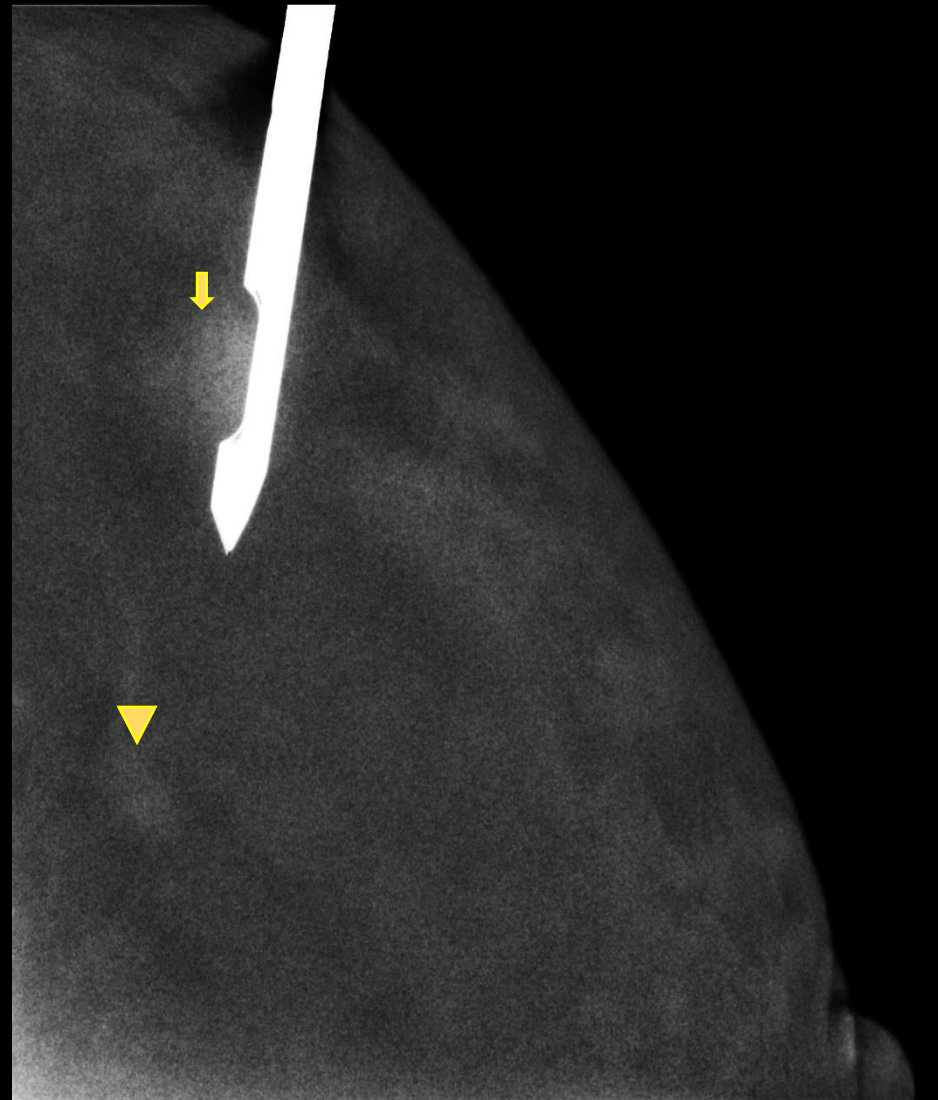
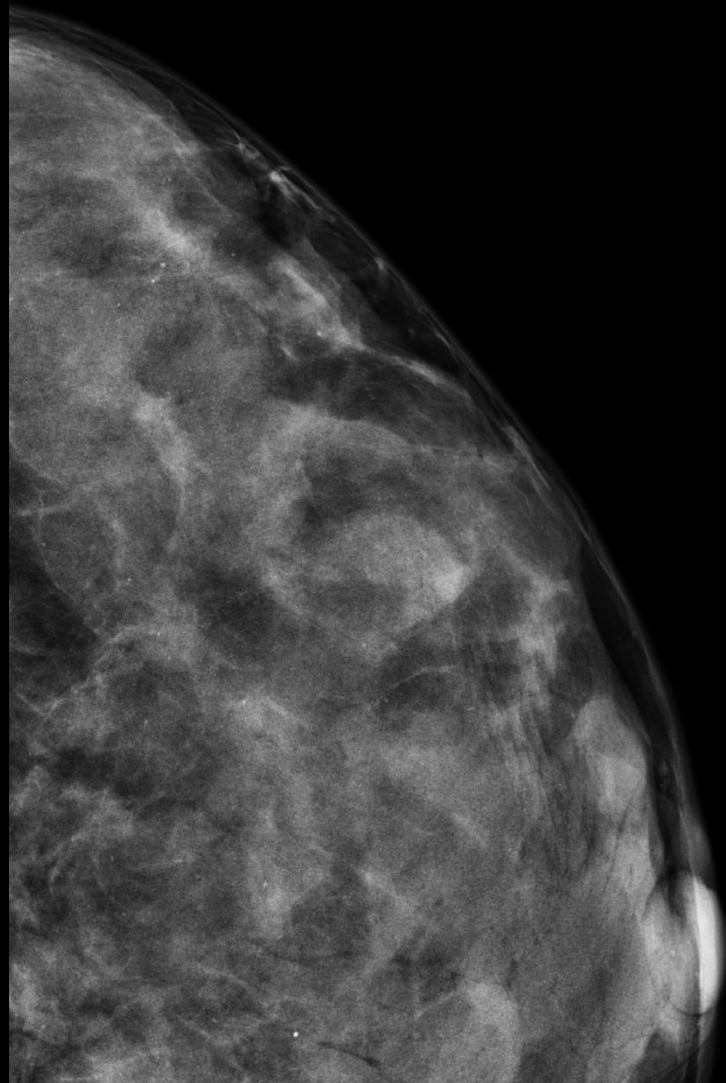


Needle size

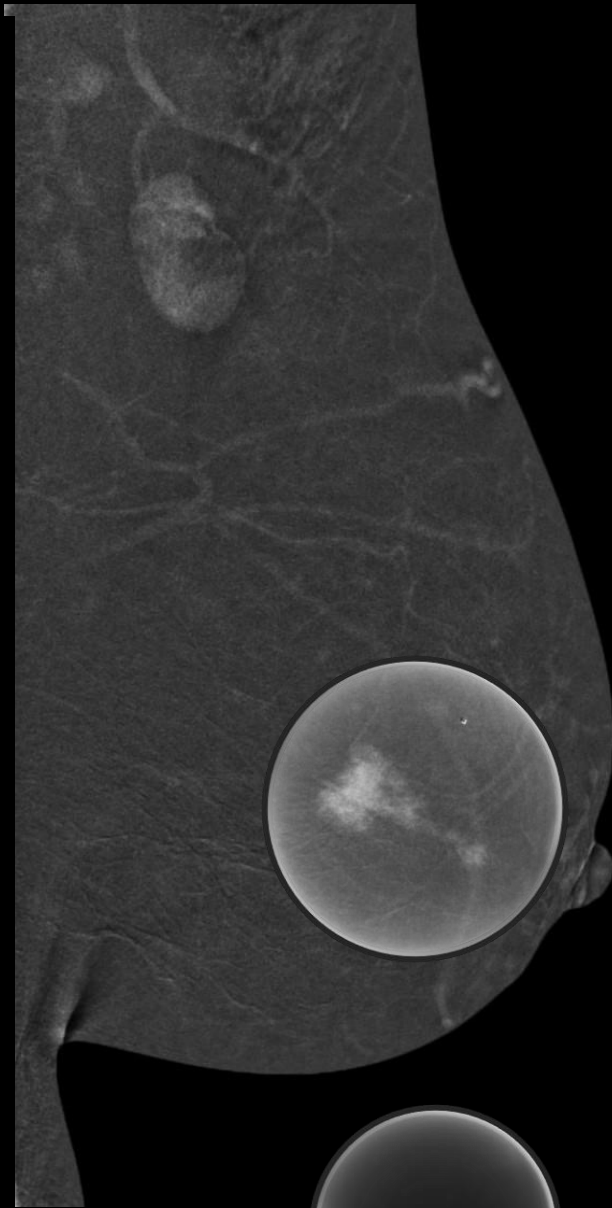
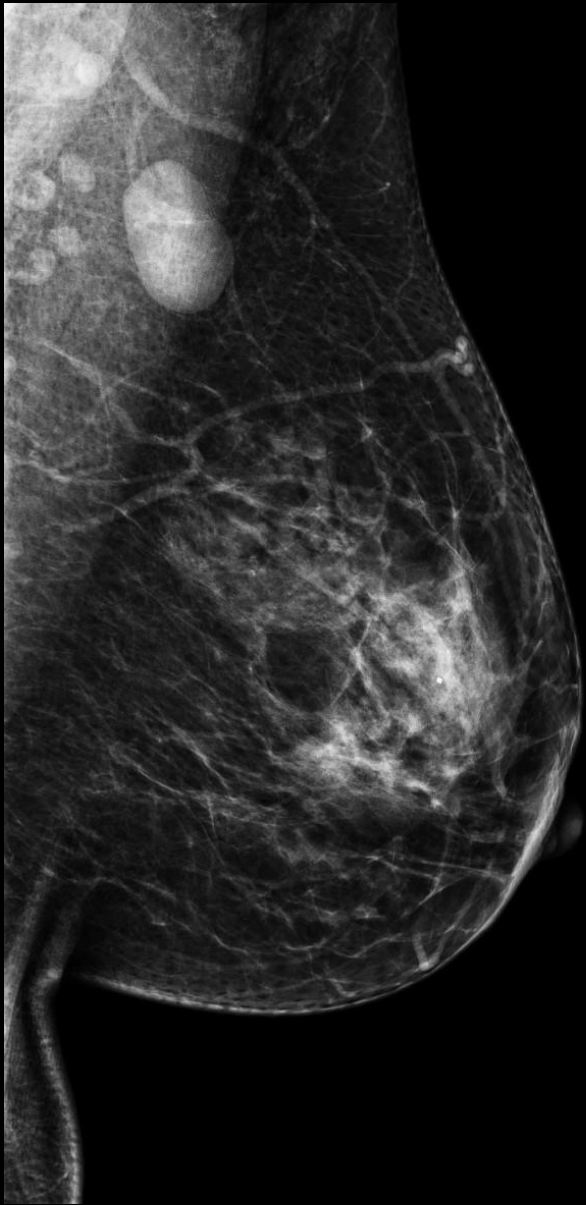
a



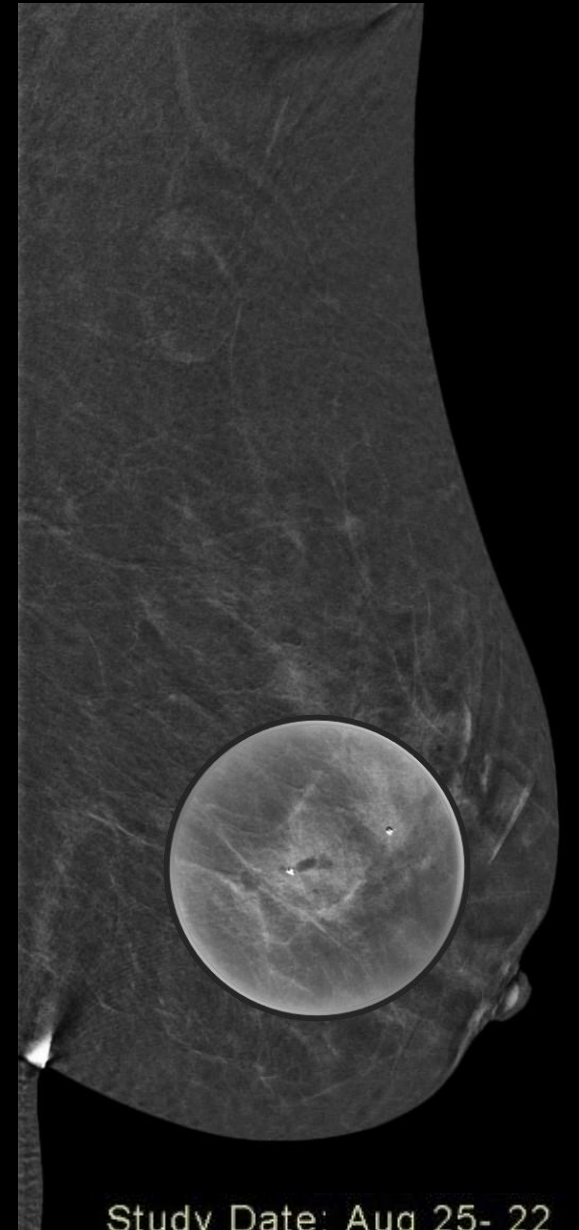
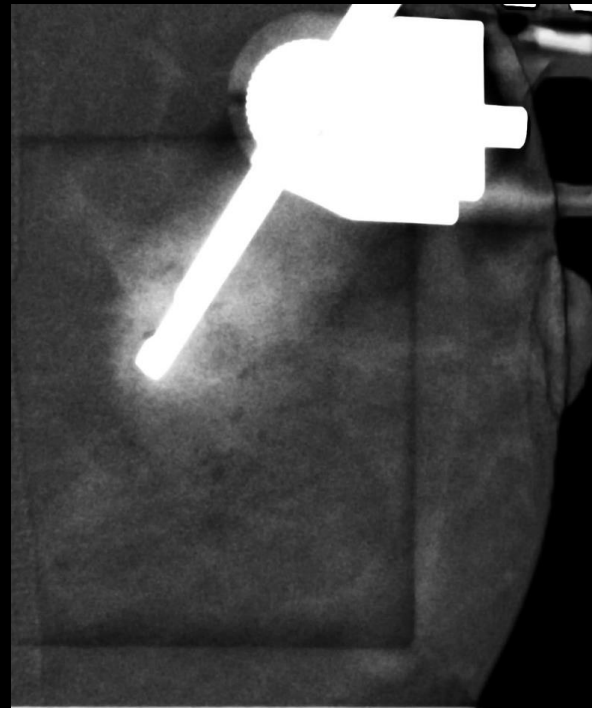
Biopsy of 2 Lesions



Same day Biopsy as CEM
Exam

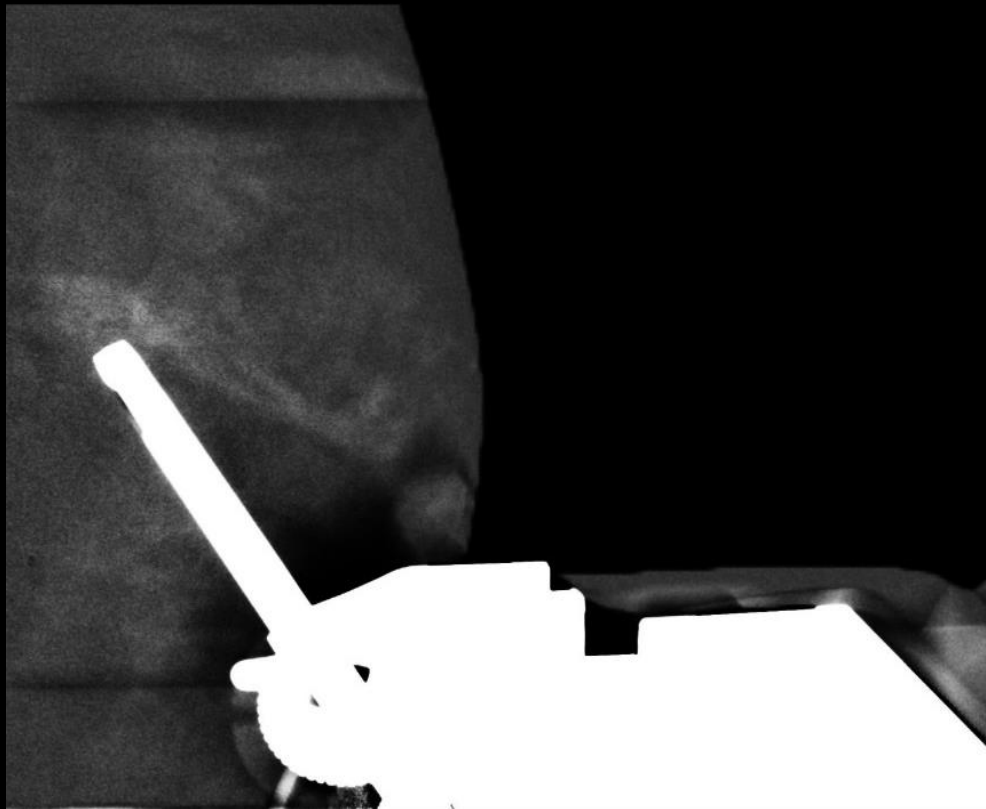
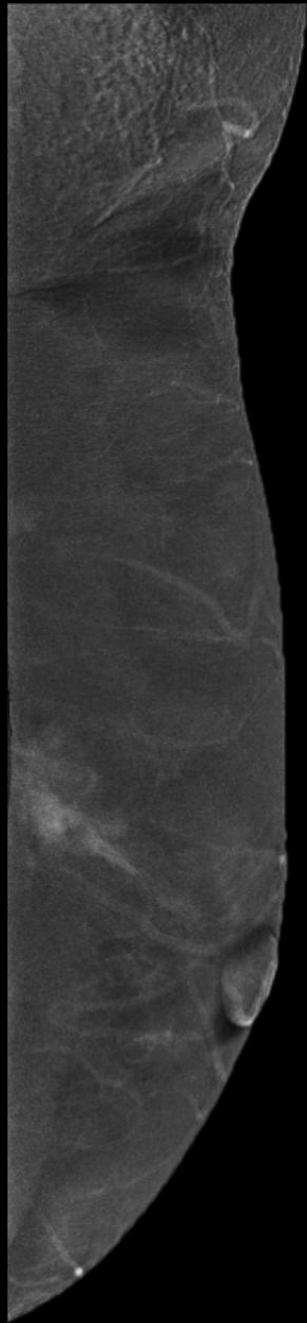
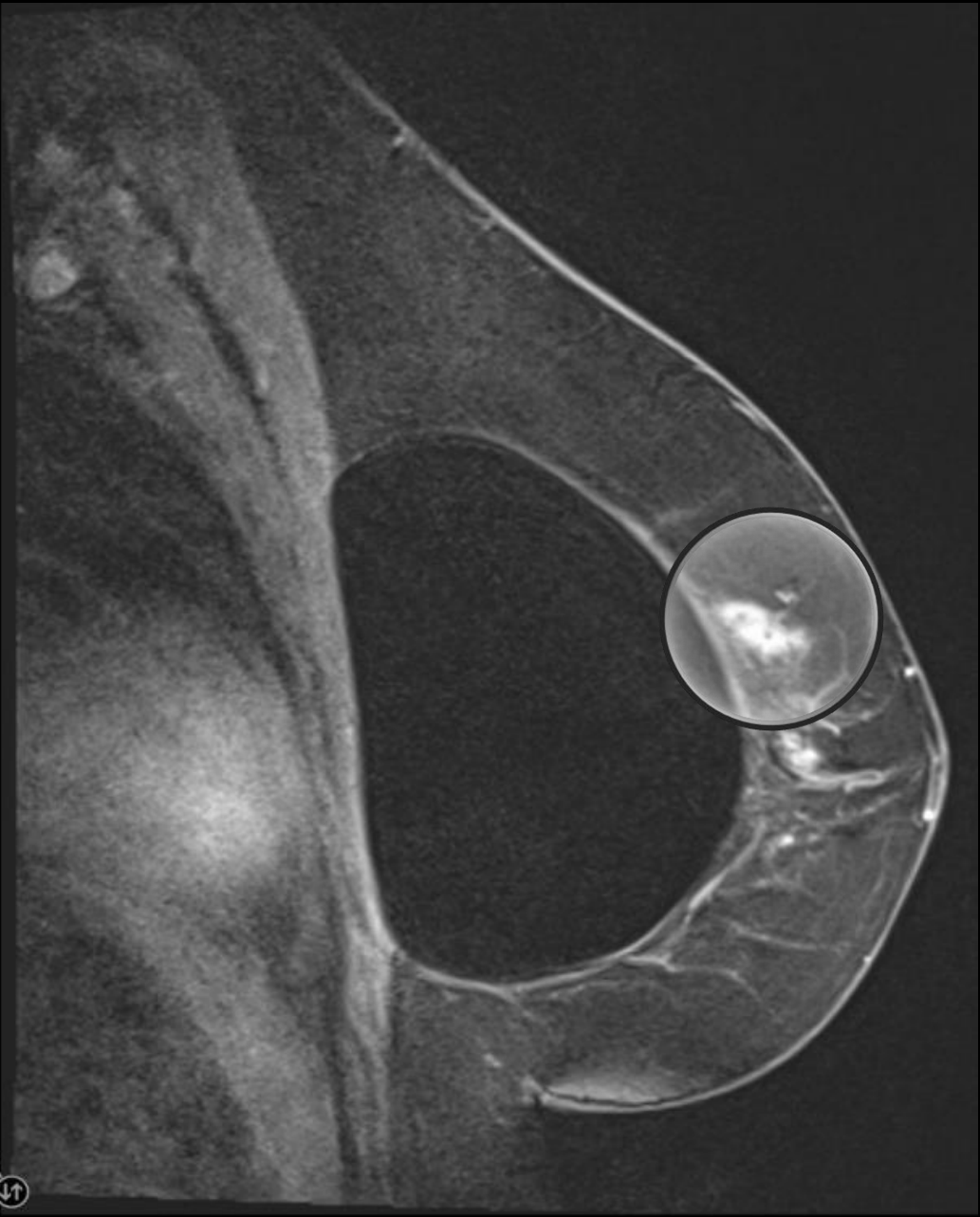


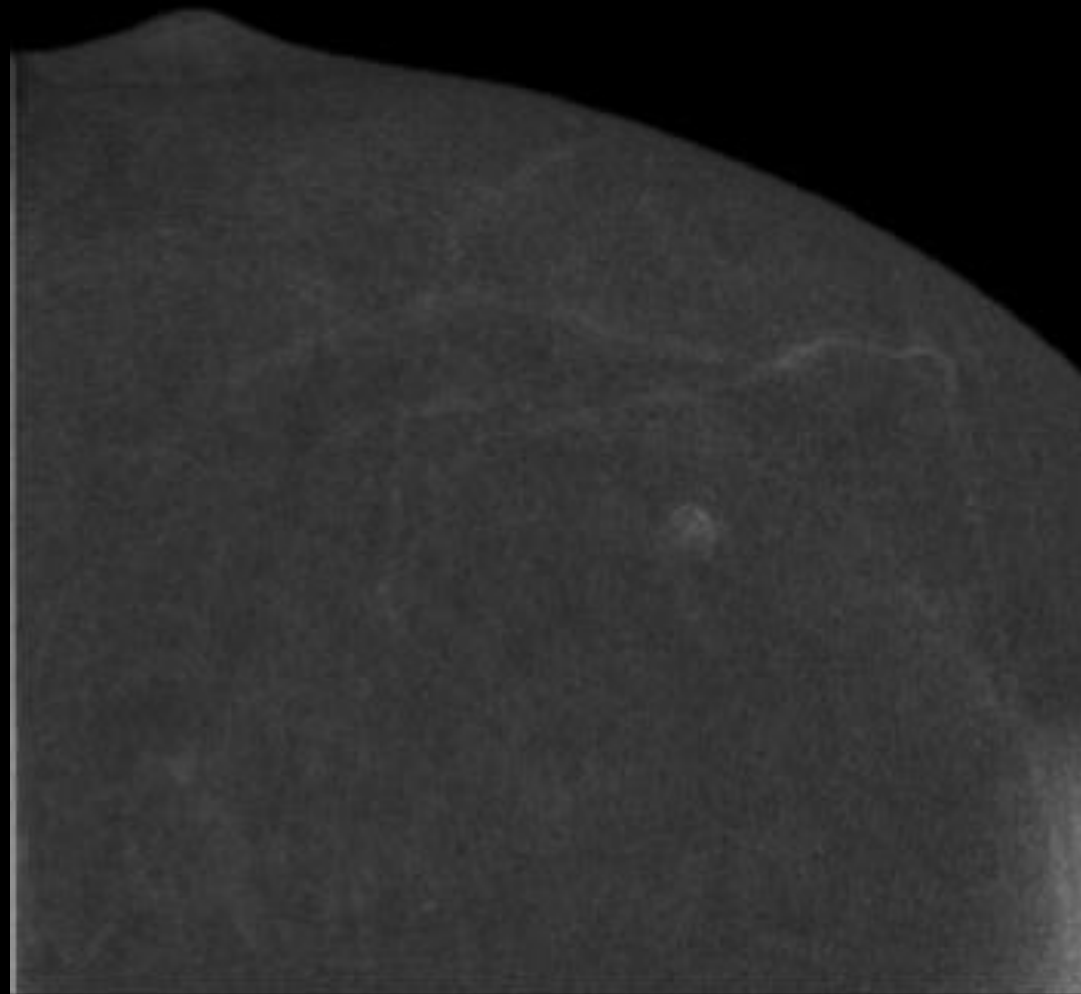
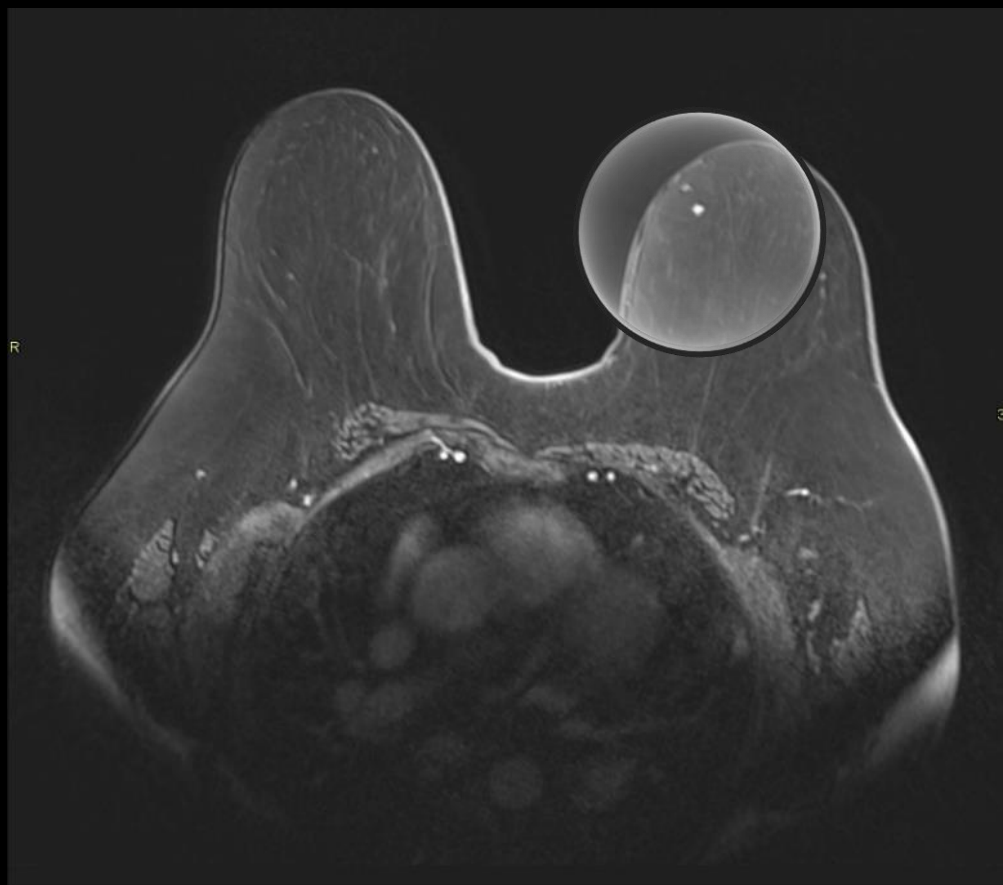
Study Date: Aug 25- 22
01:35 PM



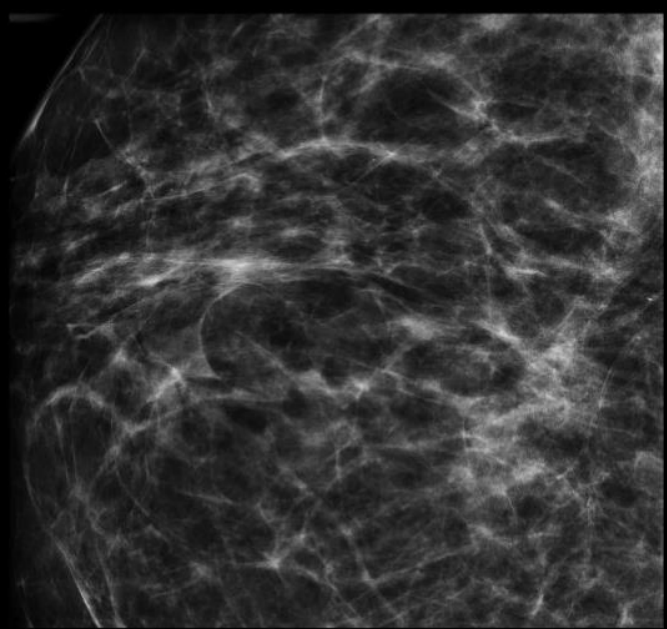
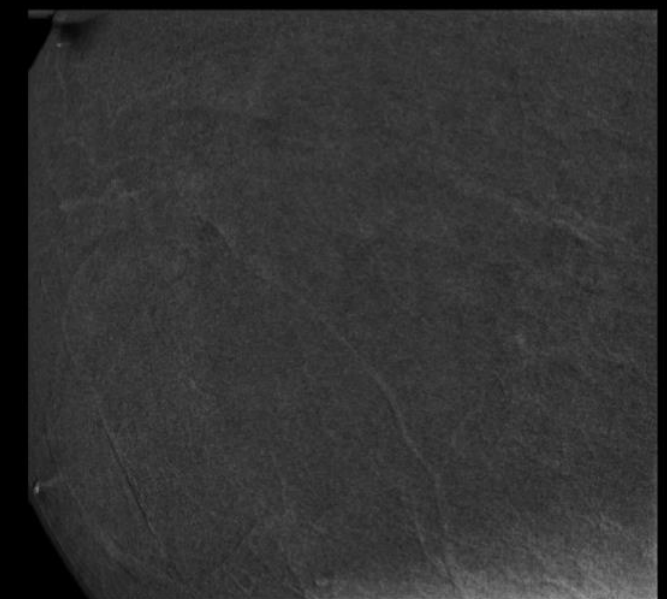
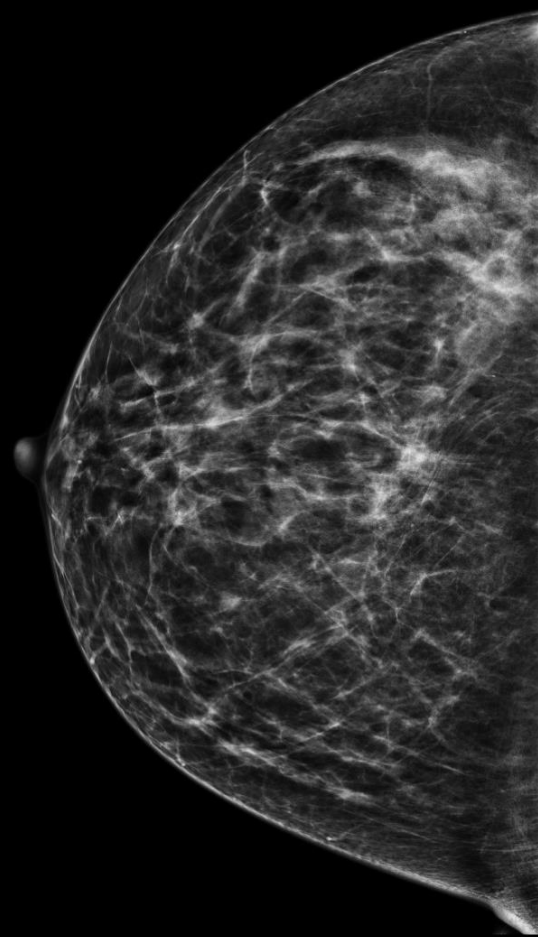
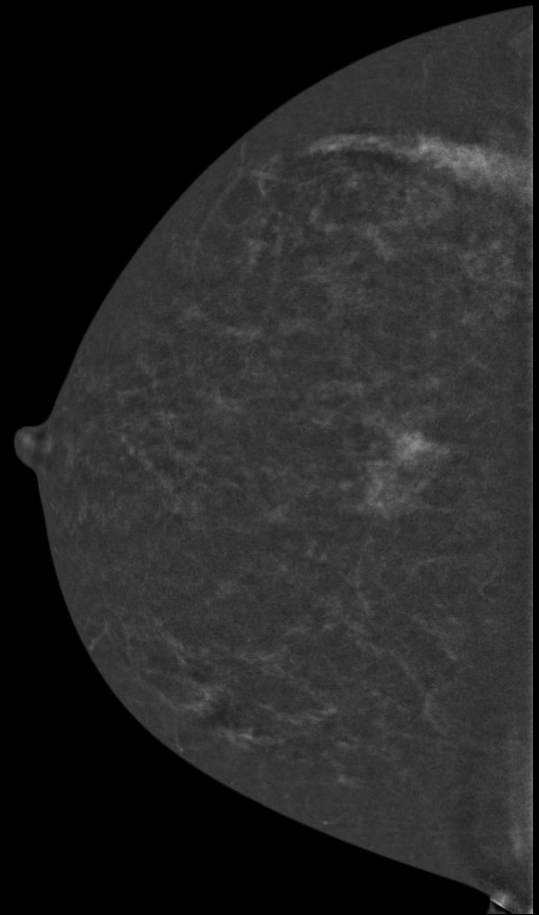
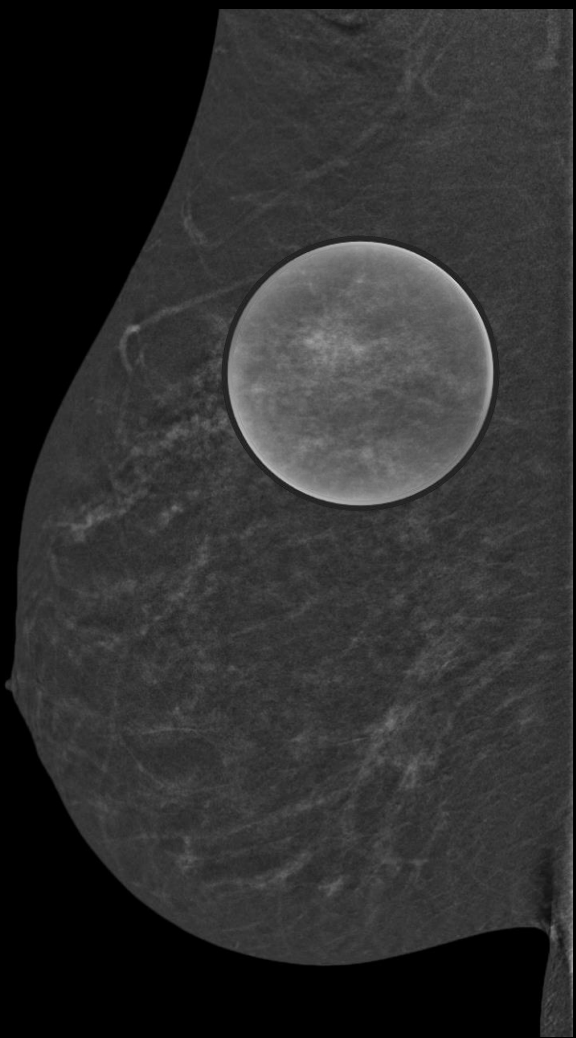
Study Date: Aug 25- 22
02:14 PM

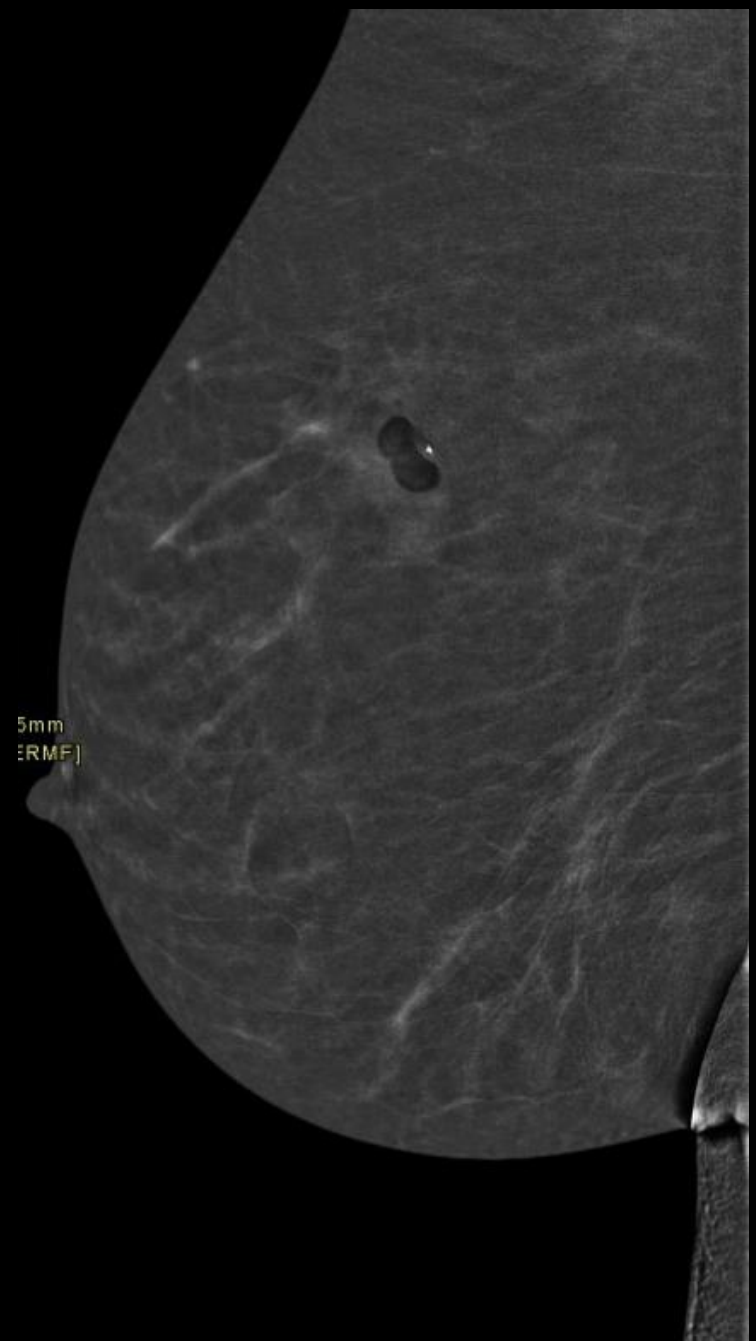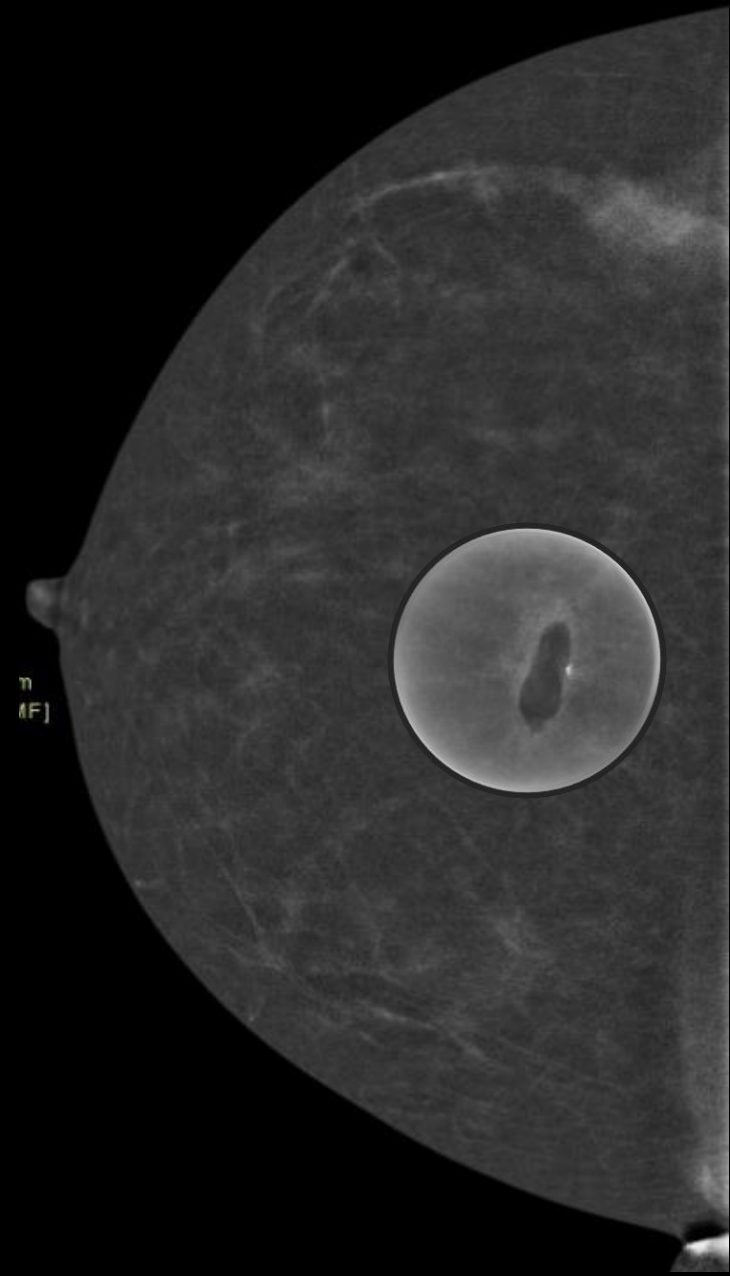
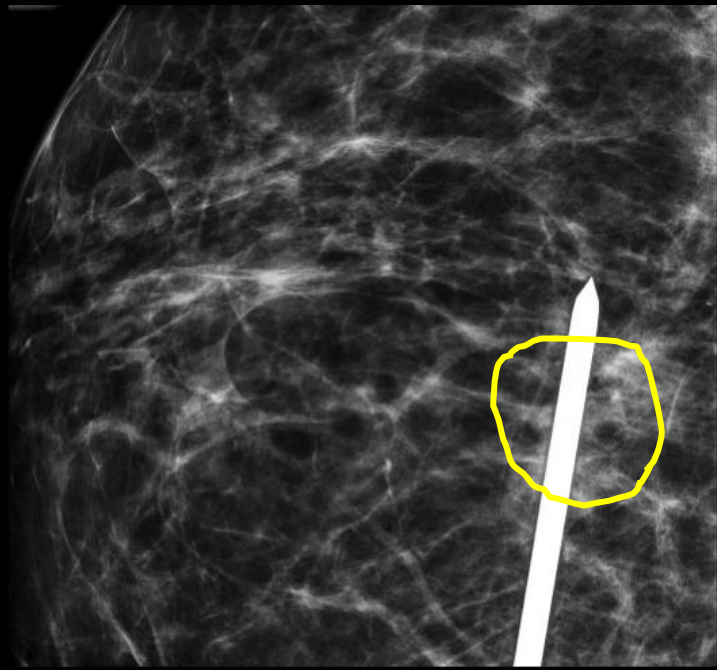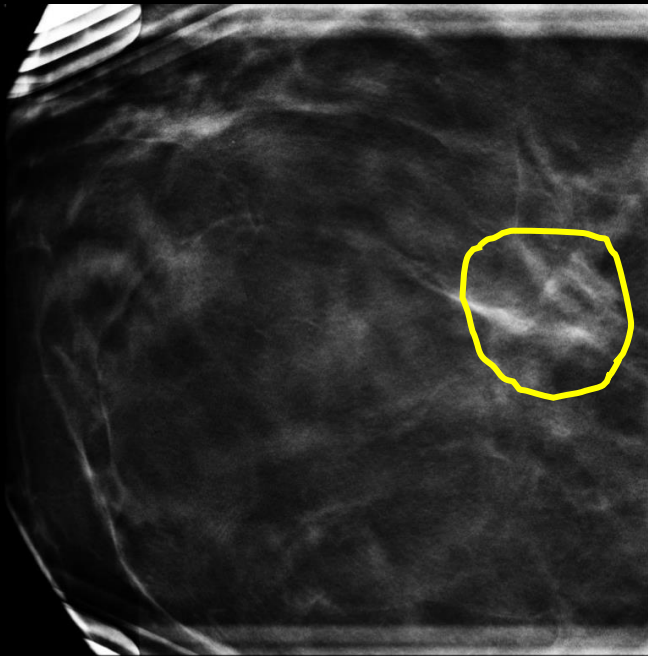
Lesions detected by MRI

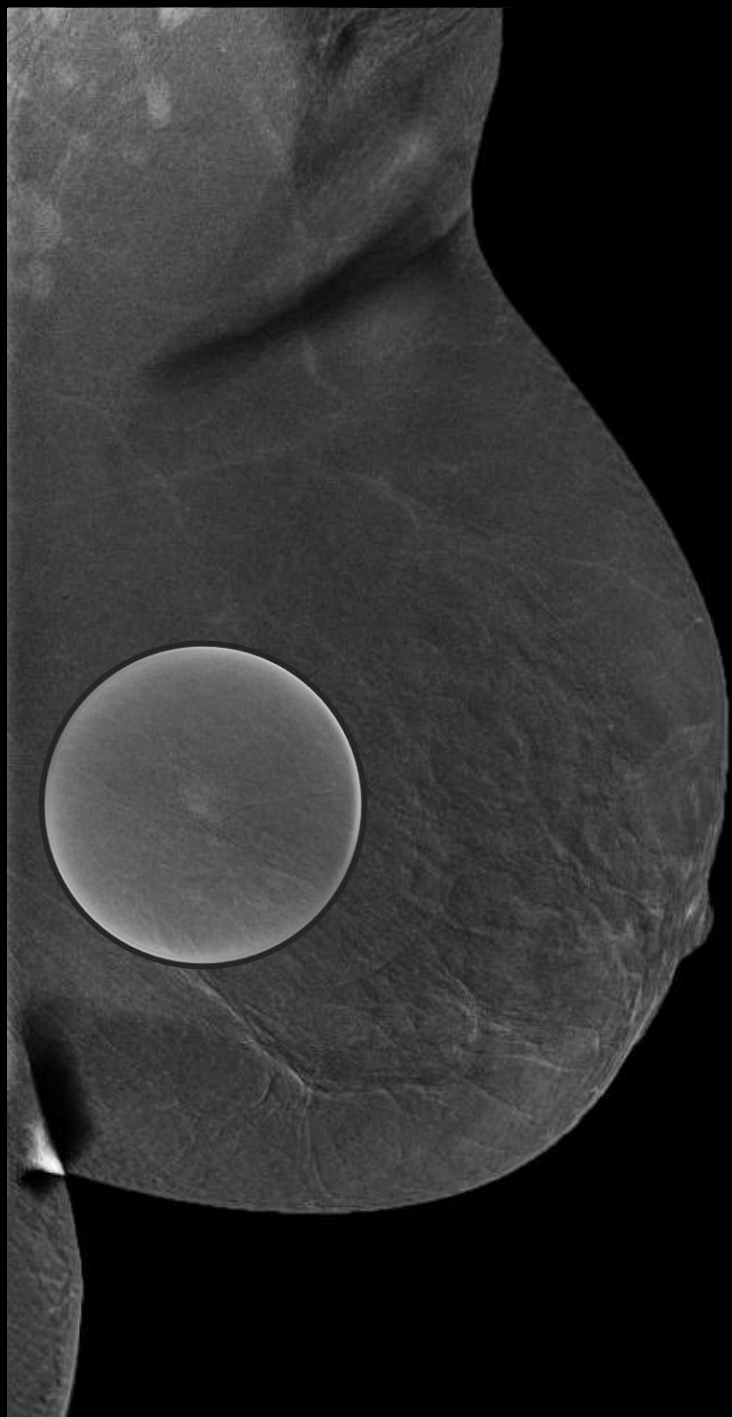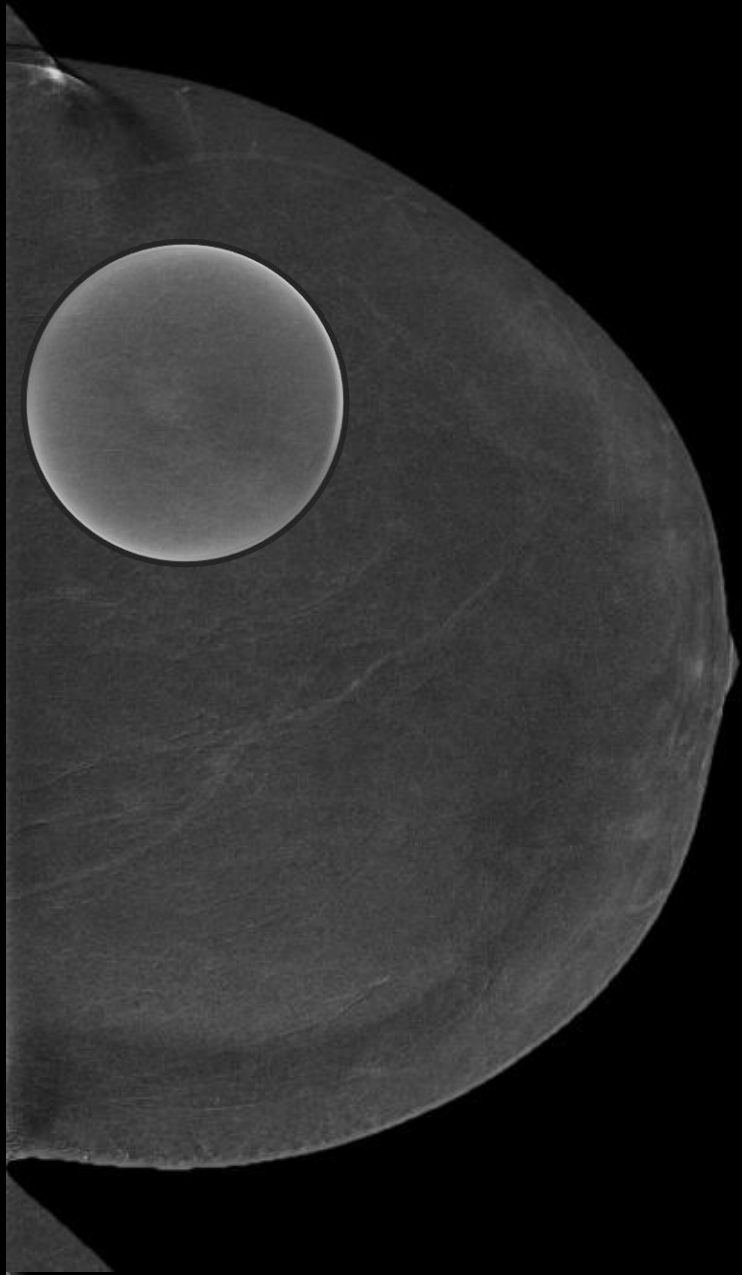



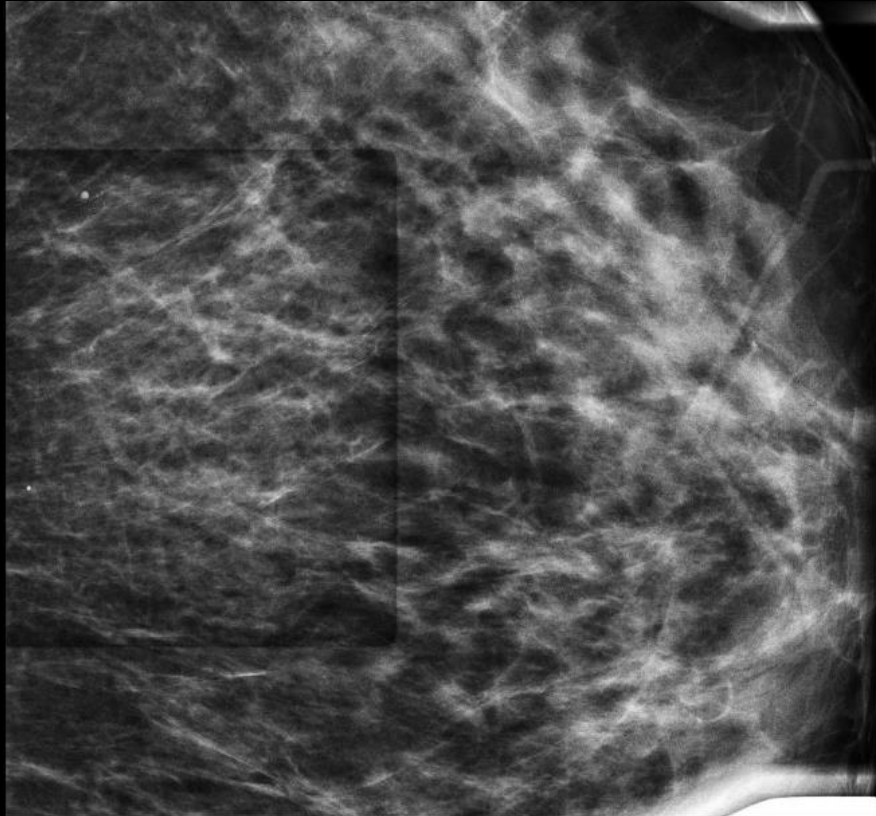


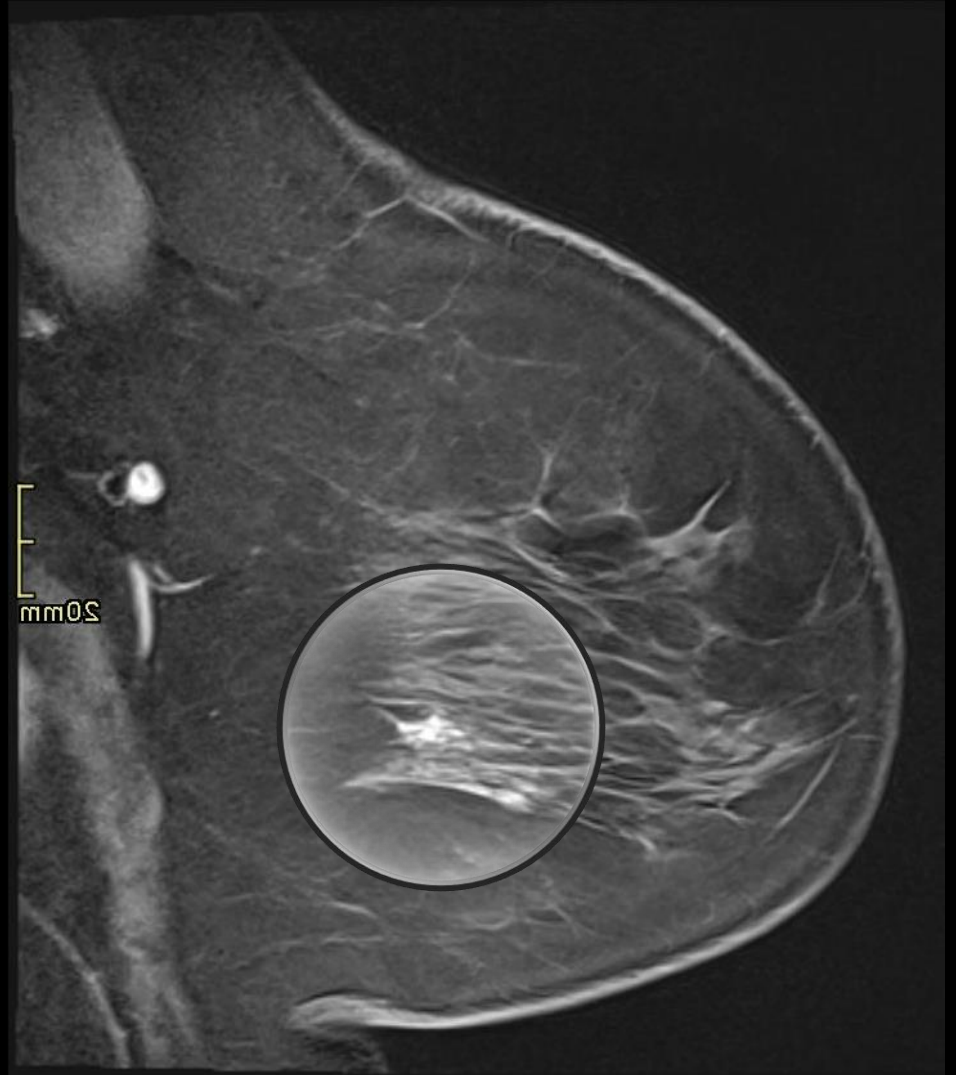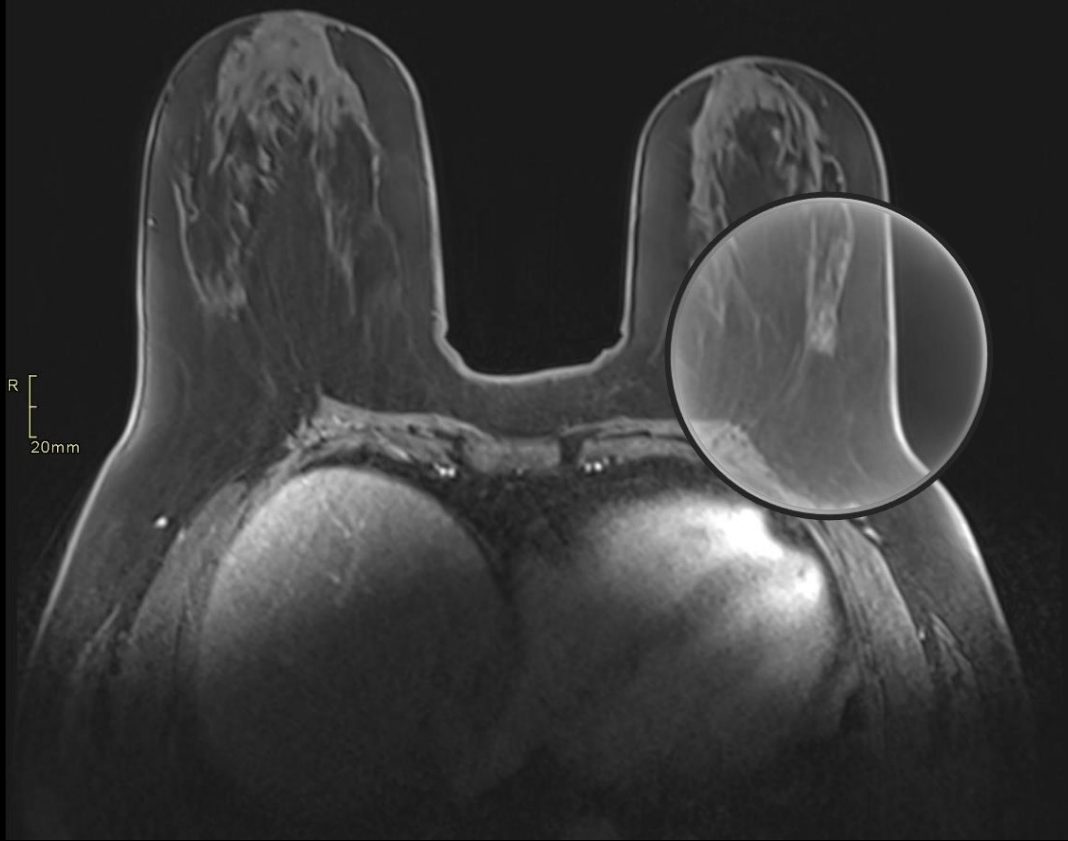
Non-visualized lesions

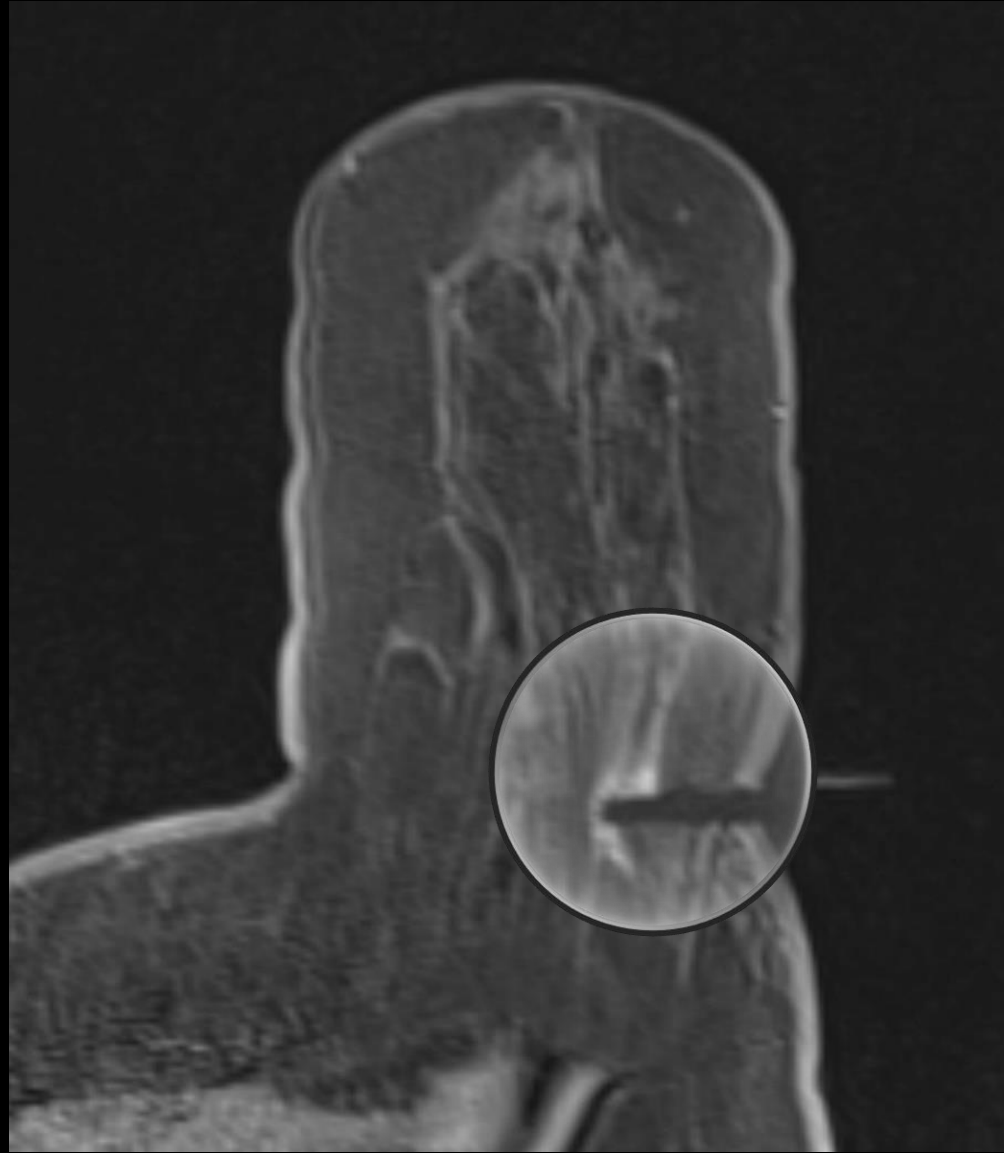



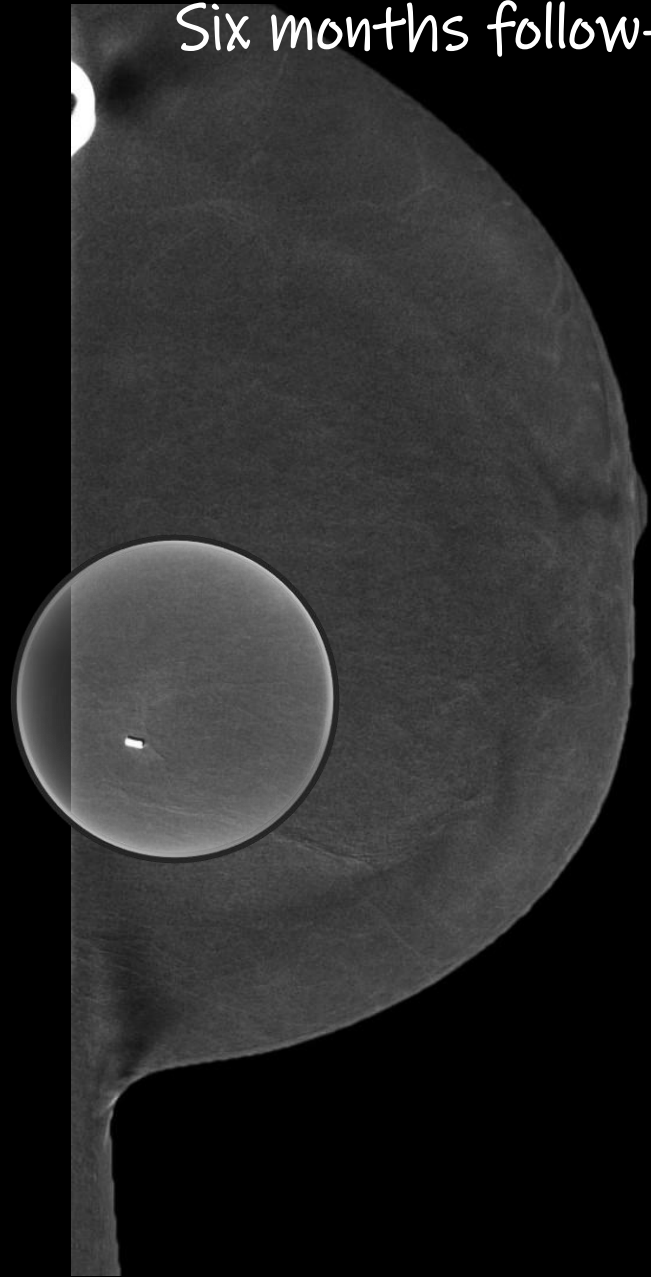








Six months follow-up



Pre-operative localization

