

MULTIMODALITY CASE CORRELATION

Dr. Meredith Lynch, FRCPC, DABR
Associate Professor, McMaster University
OBSP Regional Breast Imaging Lead, Haldimand Niagara Hamilton Burlington Brant
Radiologist, Juravinski Hospital, Hamilton Health Sciences
lynch_meredith@hotmail.com

1

Objectives

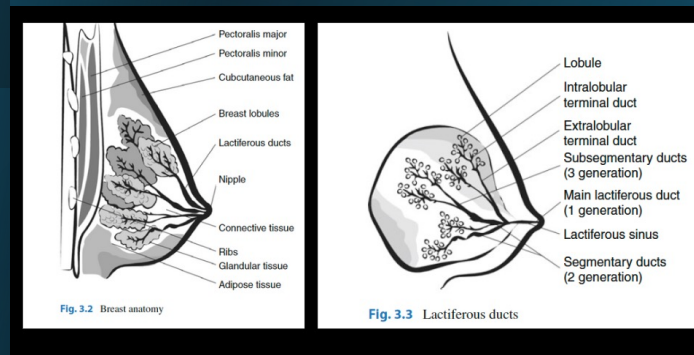
- Correlate breast anatomy and recognize common abnormalities on multiple imaging modalities including mammography, DBT, MRI, CEM
- Describe lesions using BI-RADS lexicon
- Understand role of MRI and CEM in workup of imaging abnormalities

2

Imaging Anatomy Correlation

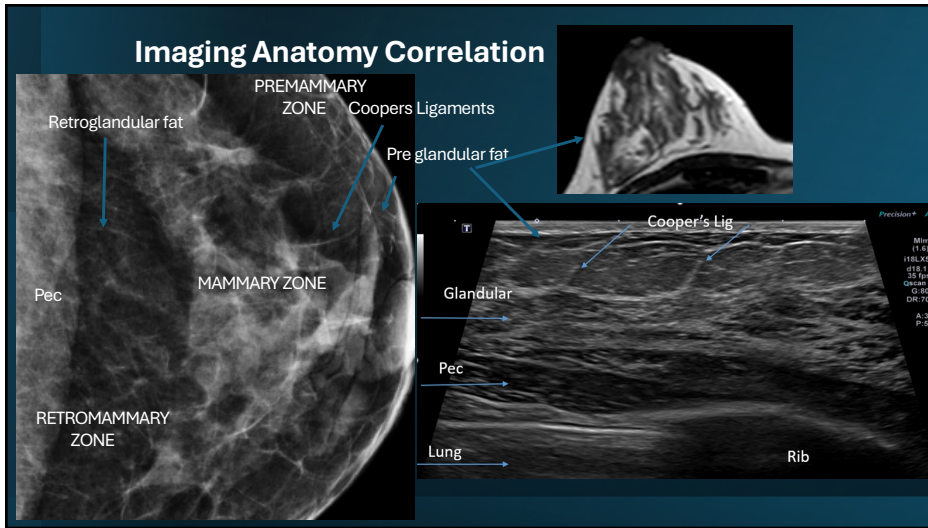
3

Breast Anatomy

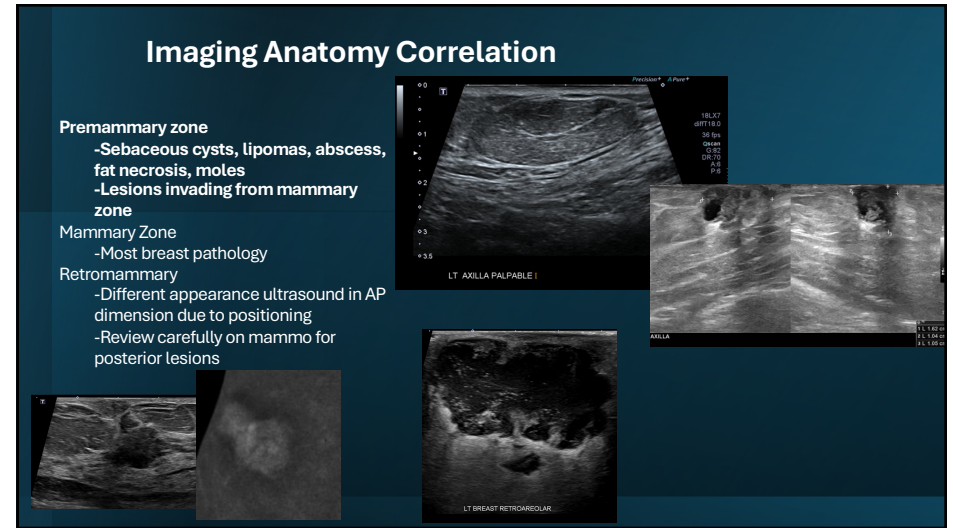


- Up to 20 lobes
- Each has lobules and terminal ducts which join larger ducts
- Lactiferous sinus extends to nipple
- Majority pathology Arises in TDLUs

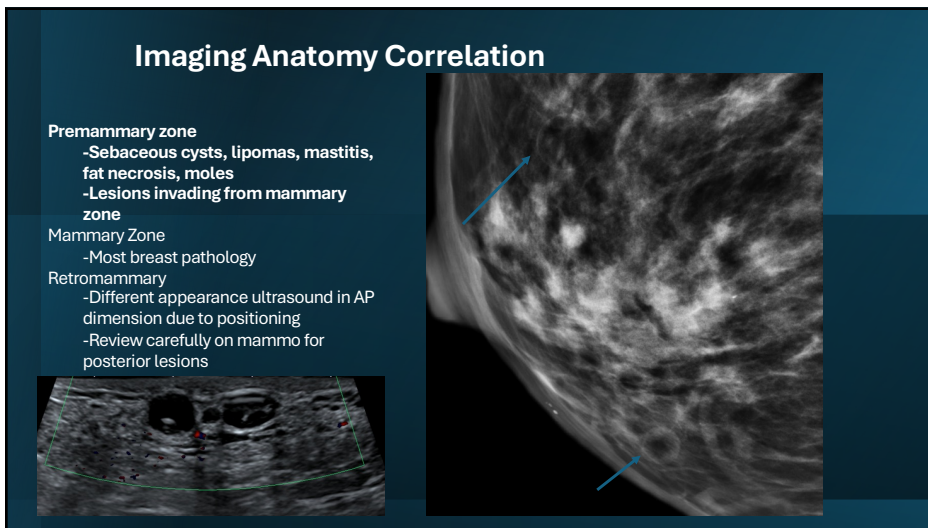
4



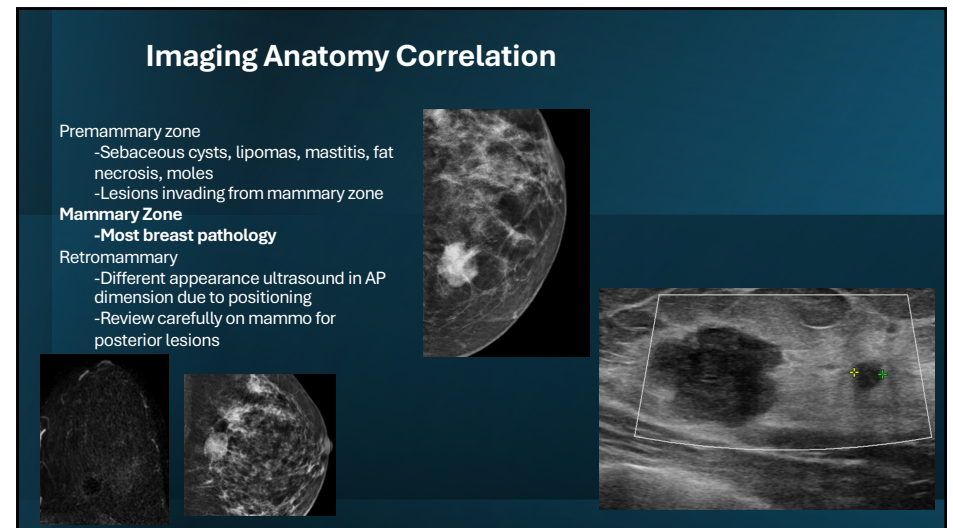
5



6



7



8

Imaging Anatomy Correlation

Premammary zone

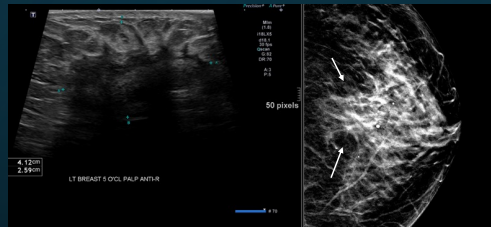
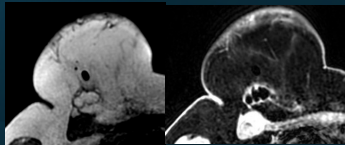
- Sebaceous cysts, lipomas, mastitis, fat necrosis, moles
- Lesions invading from mammary zone

Mammary Zone

- Most breast pathology

Retromammary

- Review mammo carefully for posterior lesions
- Note different appearance ultrasound in AP dimension due to positioning



9

Indications for Breast MR and CESM

10

Indications for Breast MRI

- Preoperative staging
- Problem solving
- Detection of the invasive component in DCIS lesions
- Neoadjuvant chemotherapy response
- Supplemental screening
- High risk screening

11

Indications for Contrast Enhanced Mammography

- Preoperative staging
- Problem solving
- Neoadjuvant chemotherapy response
- Supplemental screening
- Potential alternative to MRI if patient contraindicated or not available

12

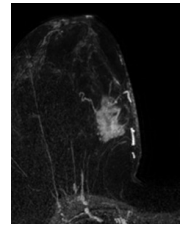
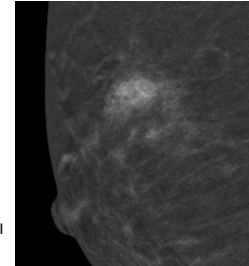
Case Review

Masses

13

Mass Descriptors on MRI and CEM

- Background parenchymal enhancement (BPE)
 - Minimal, mild, moderate, marked
- Masses
 - Shape
 - Round, oval, irregular
 - Margins
 - Circumscribed, not circumscribed (irregular or spiculated)
- Enhancement pattern
 - Homogeneous, Heterogeneous, Rim
 - Dark internal septation specific to MRI
- Lesion conspicuity relative to BPE
 - Low, moderate, high
 - *Specific to CEM

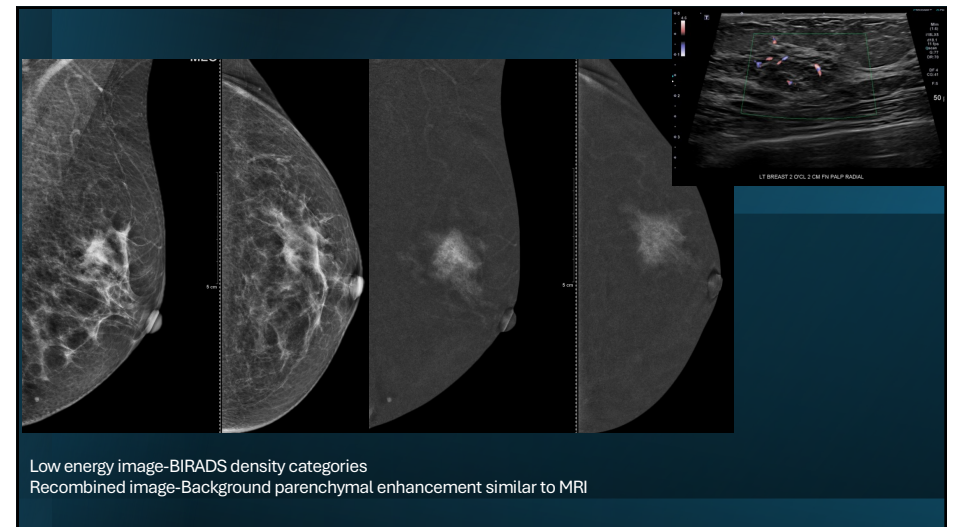


14

Case 1

Abnormality on screening mammogram

15



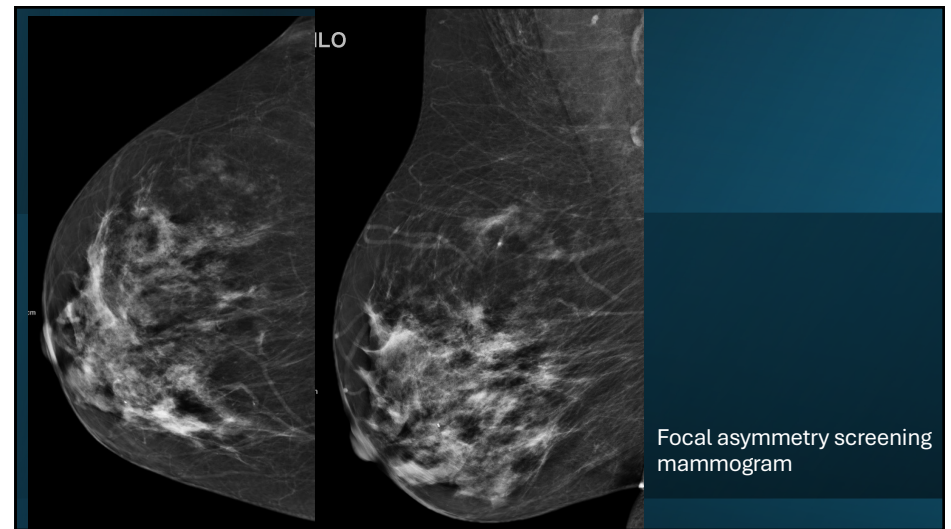
Low energy image-BIRADS density categories
Recombined image-Background parenchymal enhancement similar to MRI

16

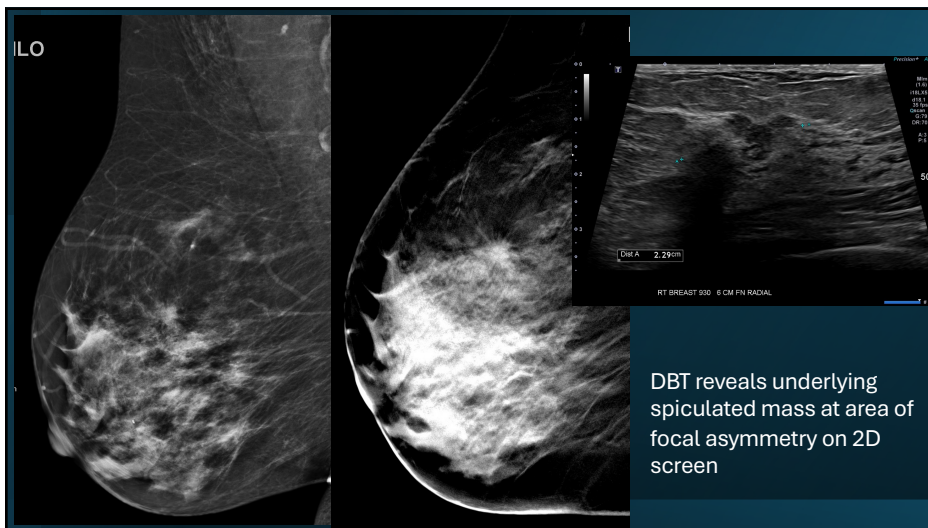
Case 2

Focal asymmetry on screening mammogram

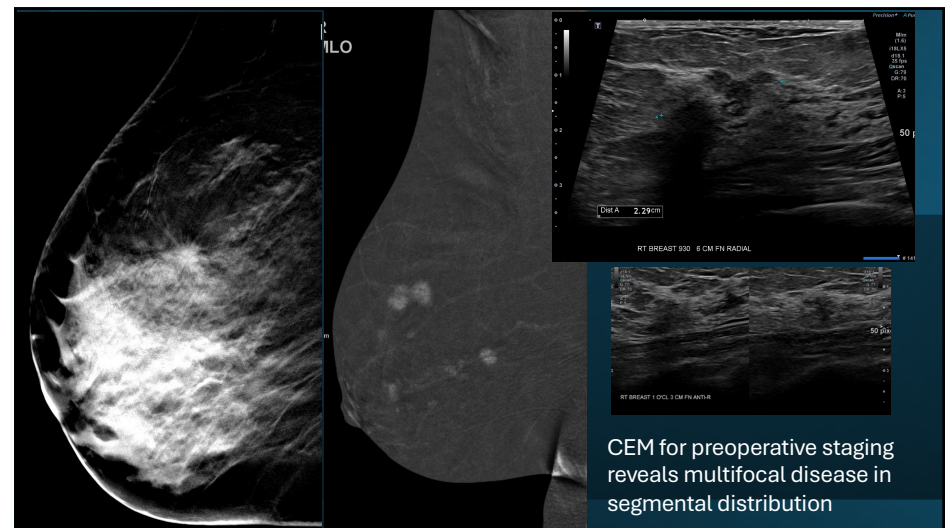
17



18



19

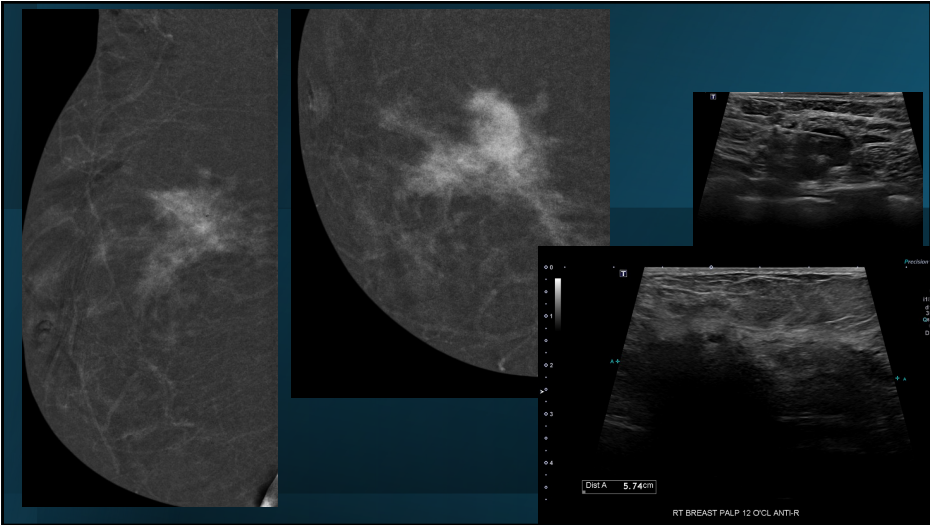


20

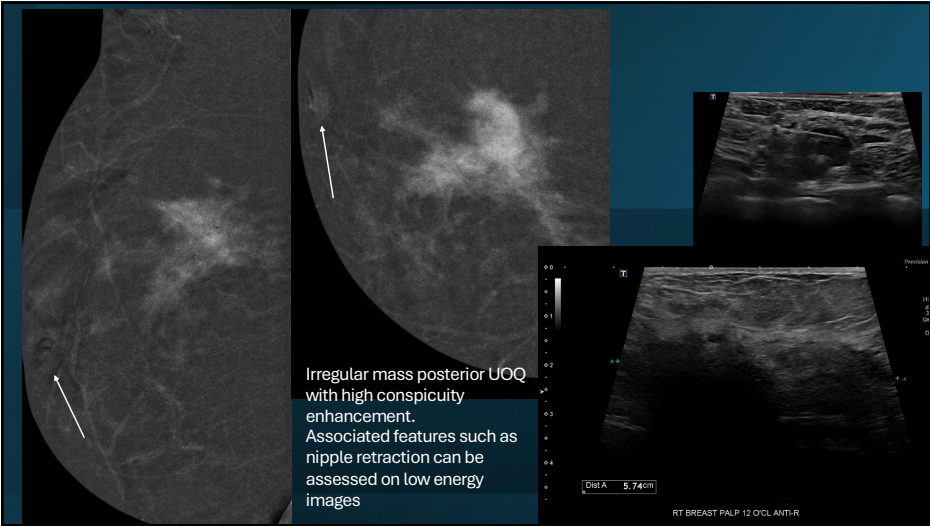
Case 3

Palpable right breast mass

21



22

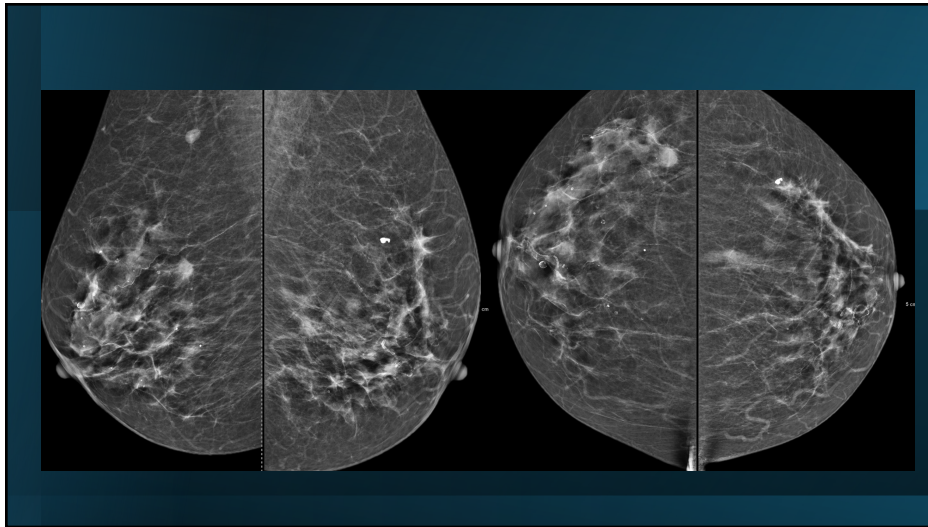


23

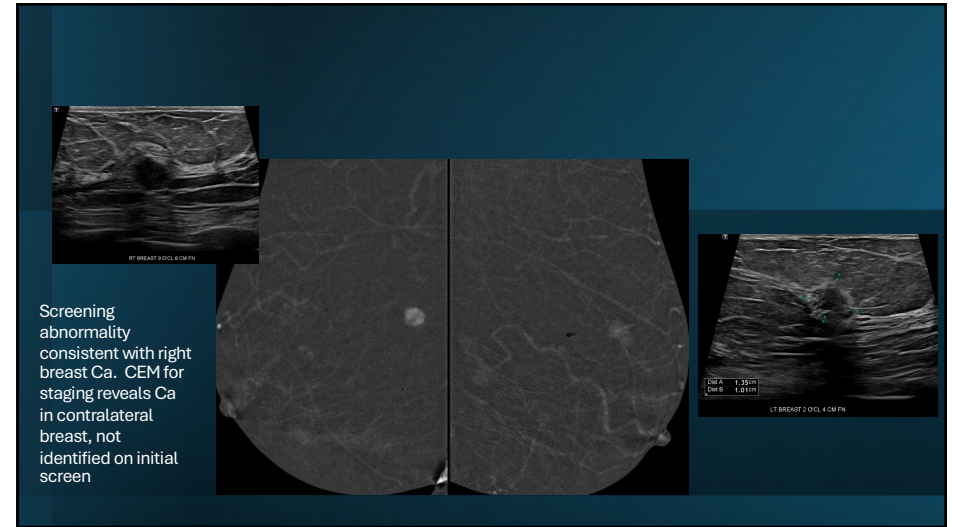
Case 4

Abnormal screening mammogram

24



25



26

Non Mass Descriptors on MRI and CEM

DISTRIBUTION

- Focal
 - Confined area less than quadrant
- Linear
 - Enhancement in line or branching line
- Segmental
 - Triangular/cone shaped with apex at nipple
- Regional
 - Enhancement encompassing more than single ductal system
- Diffuse
 - Distributed randomly throughout the breast

INTERNAL ENHANCEMENT CHARACTERISTICS

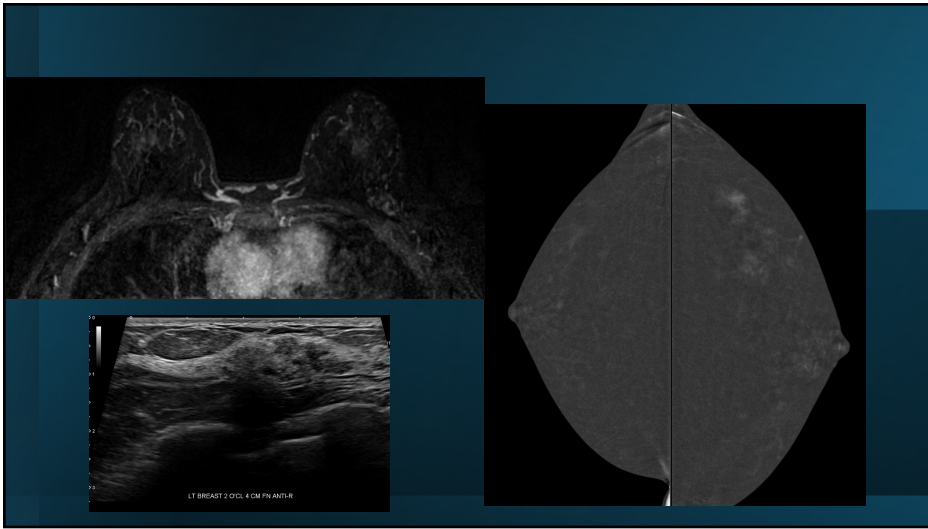
- Homogeneous, heterogeneous, clumped
- *Clustered ring specific to MRI

27

Case 5

Non mass enhancement

28

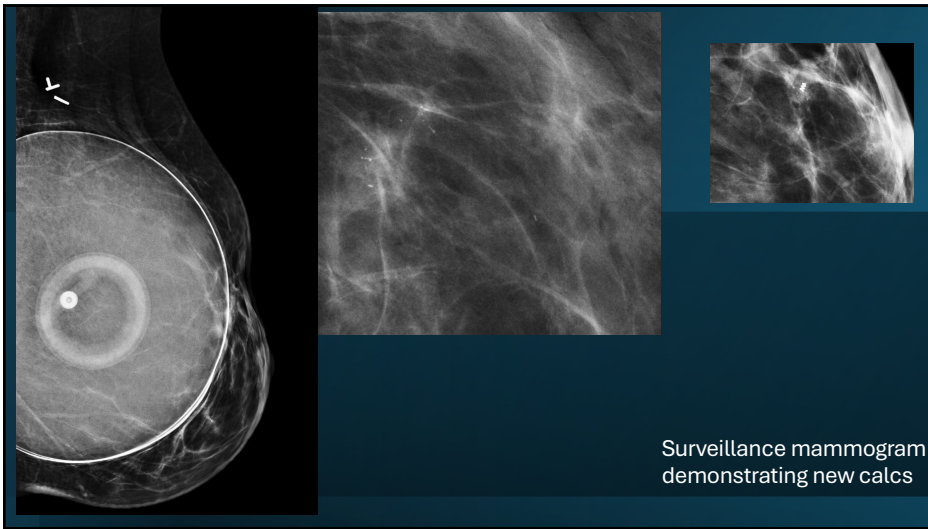


29

Case 6

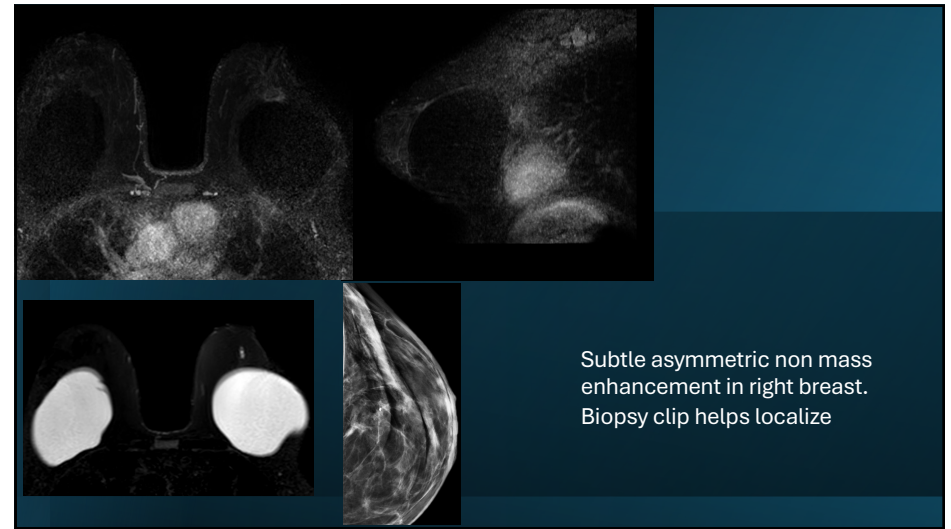
Calcifications on screening mammogram

30



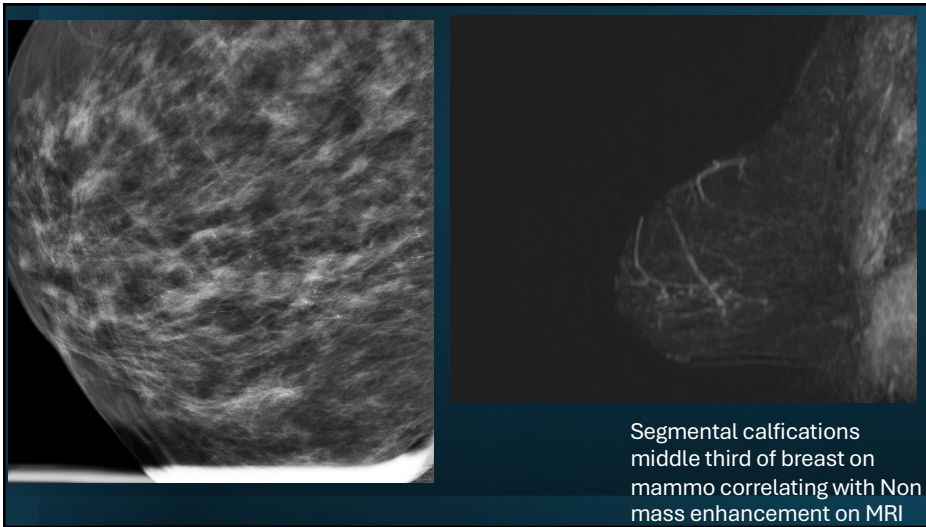
Surveillance mammogram demonstrating new calcs

31

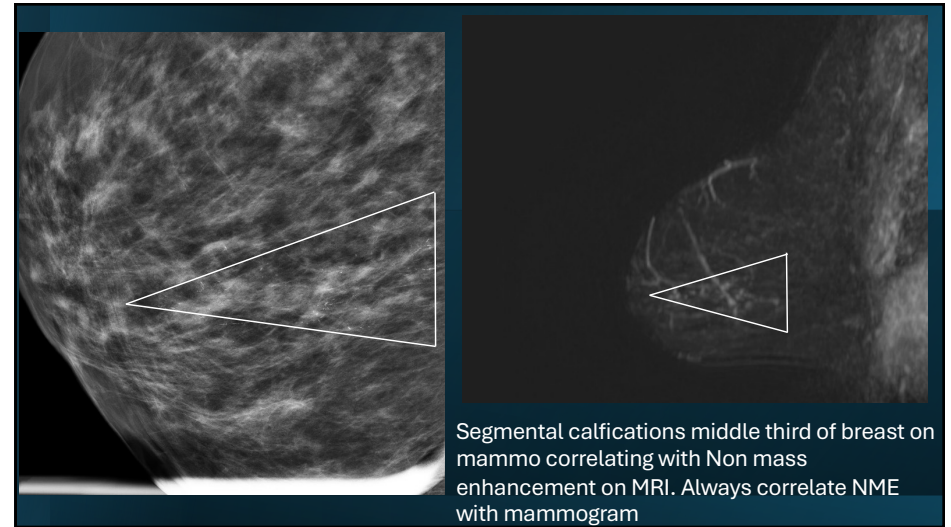


Subtle asymmetric non mass enhancement in right breast. Biopsy clip helps localize

32



33

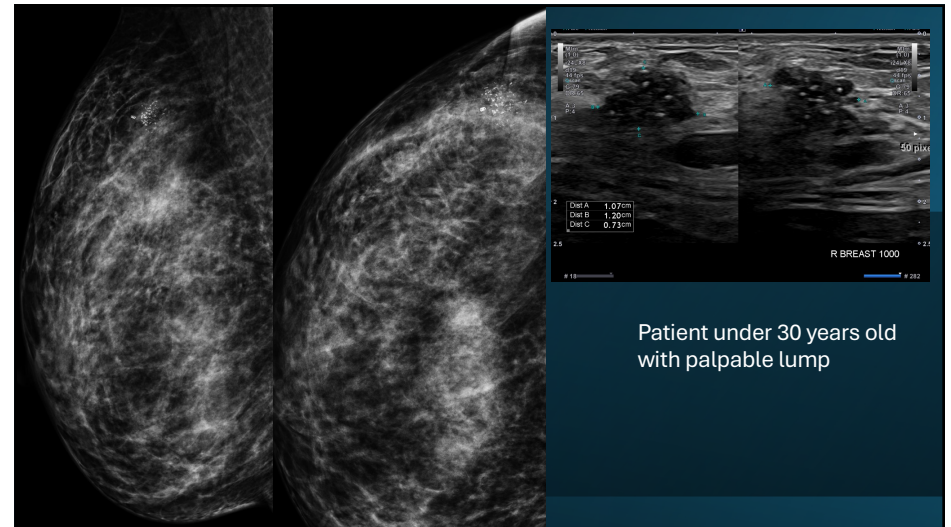


34

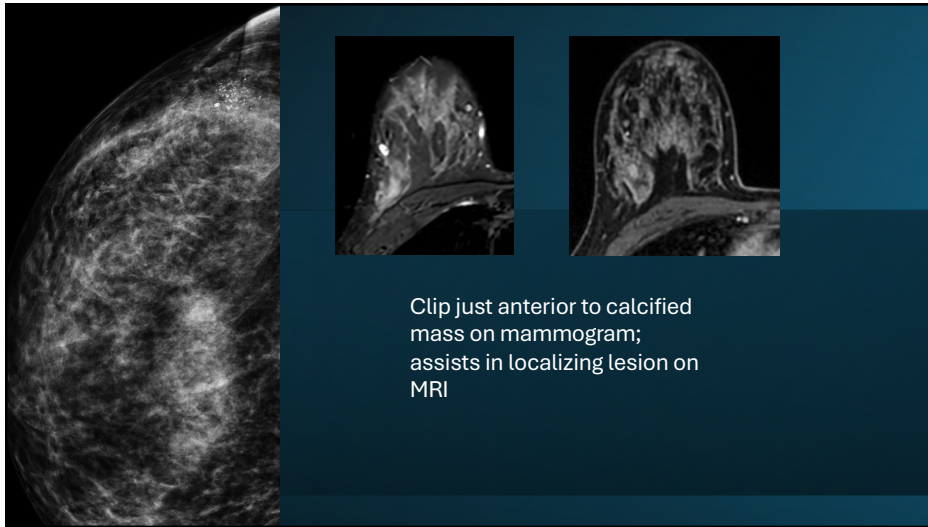
Case 7

- Young woman presenting with palpable lump

35



36



37

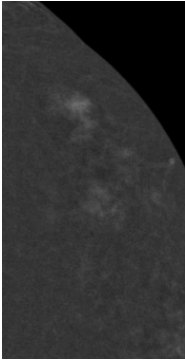
Case 7

- Architectural Distortion

38

Architectural distortion

- DBT improves detection compared to 2D mammo
- May not enhance or demonstrate ultrasound correlate
- Differential includes
 - IDC
 - ILC
 - Radial scar/complex sclerosing lesions
 - Scar



39

Persistent distortion on DBT. No definite enhancement on CEM or MRI. No ultrasound correlate. Mammo guided biopsy showed Complex Sclerosing Lesion with atypia

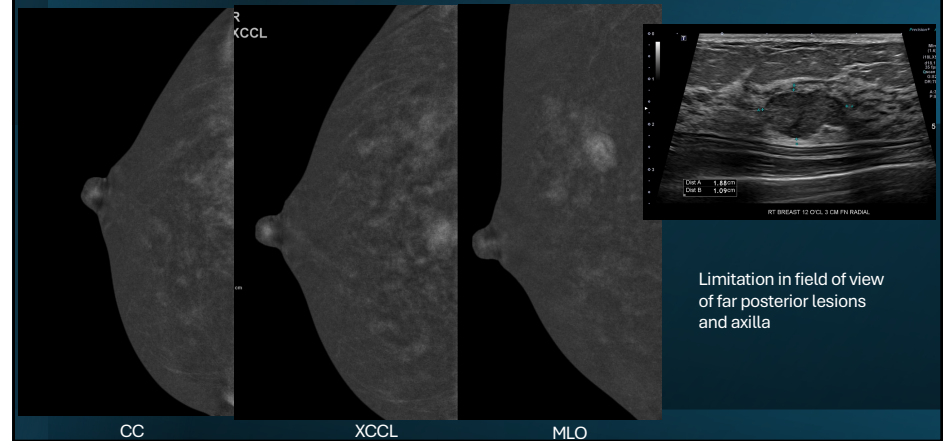
40

Case 8

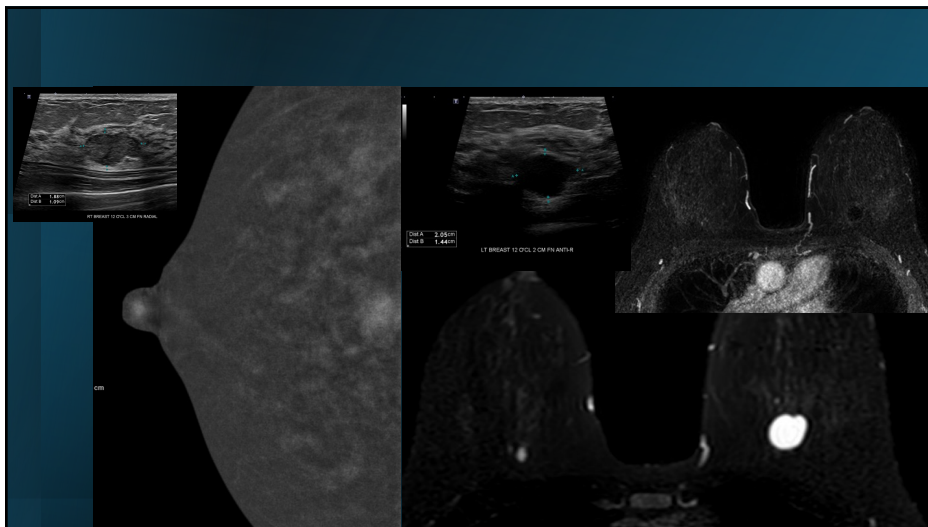
- Lesion characterization

41

Lesion characterization



42



43

Summary

- Multiple modalities available for breast screening and diagnostic imaging including mammogram, DBT, ultrasound, CEM, and Breast MRI
- MRI most sensitive modality for breast cancer detection
- CEM has similar indications and BIRADS lexicon – limitations in posterior lesions and axilla evaluation
- DBT improves lesion conspicuity compared to 2D mammo, especially architectural distortion
- Describe lesions and enhancement according to BIRADS
- Lesion shape and margins most important
- If lesion suspicious, biopsy using modality on which lesion seen, regardless of enhancement

44

References

- ACR. (2017). Breast Imaging Reporting & Data System. Breast Imaging Reporting & Data System | American College of Radiology. Retrieved July 19, 2022, from <https://www.acr.org/-/media/ACR/Files/RADS/BI-RADS/BIRADS-Reference-Card.pdf> Alt, J., Hoey, E., & Wolstenhulme, S. (2014).
- Chapter 3 – Principles of Imaging Techniques. In Undergraduate Diagnostic Imaging Fundamentals . essay, Open Textbook Library, Deng, F. (2019, March 28).
- Breast lesion localization (mnemonic): Radiology reference article. Radiopaedia Blog RSS. Retrieved July 27, 2022, from <https://radiopaedia.org/articles/breast-lesion-localisation-mnemonic-1> Kawamura, D. M., & Carr-Hoefer, C. (2018).
- The Breast. In Diagnostic medical sonography: Abdomen and superficial structures (pp. 471–524). essay, Wolters Kluwer, Sencha, A. N., Evseeva, E. V., Mogutov, M. S., & Patrunov, Y. N. (2013).
- Technique of Breast Ultrasound. In Breast Ultrasound. essay, Springer, Zexo. (2019, August 25). The recalled patient: Now what? Radiology Key. Retrieved July 26, 2022, from <https://radiologykey.com/the-recalled-patient-now-what/>

Thank you!

lynch_meredith@hotmail.com