An accolade for Ms. Louise C. Miller's life-time achievement

Louise C. Miller, R.T.(R)(M)(ARRT), CRT(M), FSBI, FNCBC

László Tabár, MD, FACR (Hon)

1

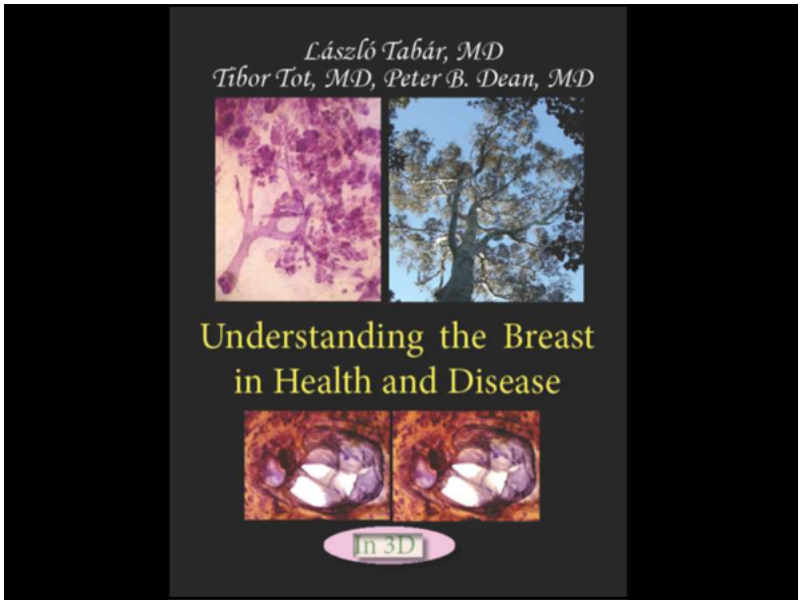

2

3

Narrated book: https://www.dropbox.com/scl/fi/fu6d9jl78mjaftewsxbns/PARTS-I-IV-MERGED.mp4.patched.mp4?rlkey=ohw509twformiz52pfh4enf0r&dl=0

ENGLISH

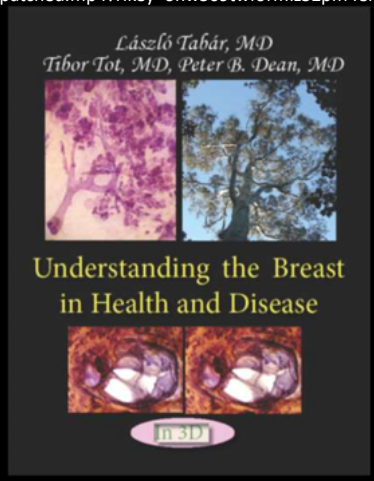

The book page by page: https://www.dropbox.com/scl/fi/alp5pxw3i0pvdxojsburq/Vol-I-High-qual-FINALx.pdf?rlkey=pj3pvif3ldn1pyc7gg2fxo0b1&dl=0

4

Narrated book in Spanish PARTs I – IV (see next slide)

The book in Spanish, page by page: https://www.dropbox.com/scl/fi/aldjrsa2tck2co16mymkf/Vol-I-SPANISH.pdf?rlkey=5jb44xbi9215nm8ucl5yvvxqg&dl=0

5

SPANISH

PART I

https://www.dropbox.com/scl/fi/26dfw8fb0xr1hq2gk5fpt/3D-Spanish-Part-I.mp4.patched.mp4?rlkey=mzjvmu9qkcth3jlwuc85xxygs&dl=0

PART II

https://www.dropbox.com/scl/fi/jo9iy8aroilrh43wwzdft/3D-Spanish-Part-II.mp4.patched.mp4?rlkey=9dn2oyzmbzk3q4tev79oj6hif&dl=0

PART III

https://www.dropbox.com/scl/fi/gt0gwj73xq2n5ltjmp6bk/3D-Spanish-Part-III.mp4.patched.mp4?rlkey=by30tw2tj9441453zku47i1st&dl=0

PART IV

https://www.dropbox.com/scl/fi/o1s8jp050jn0l2jzgl9xi/3D-Spanish-Part-IV.mp4.patched.mp4?rlkey=tq5afmd769cexlp1td5vzp6vg&dl=0

6

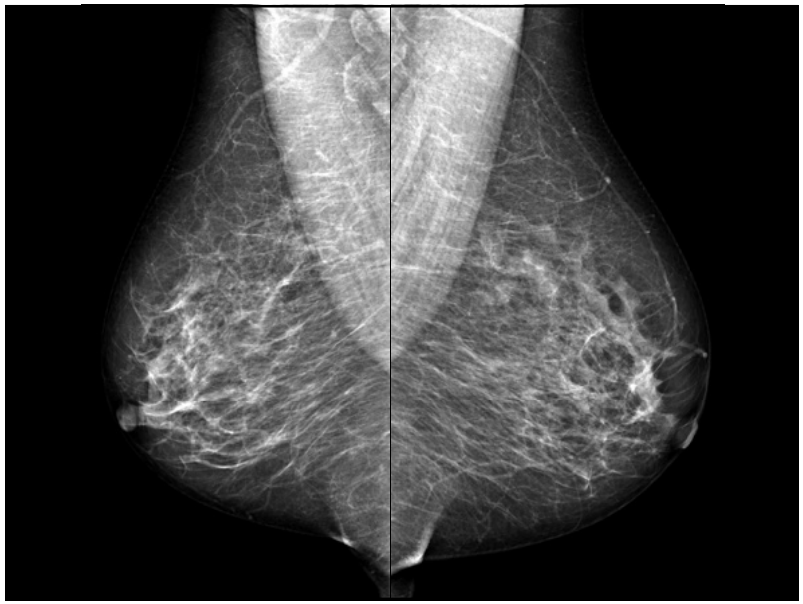

7

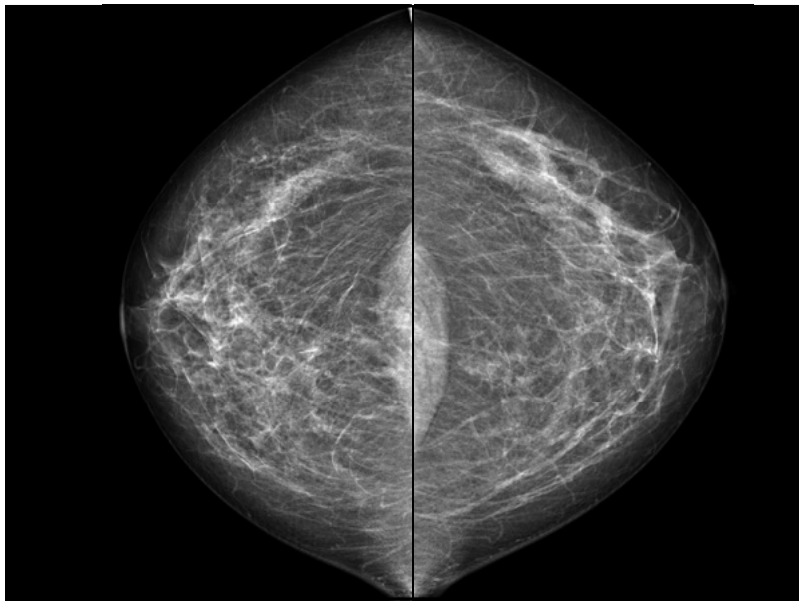

8

It is our firm belief that competence in breast image interpretation can be best achieved by correlating the large format 3D histopathology of the normal and abnormal breast tissue with

- Mammograms
- Ultrasound, MRI and
- Other imaging methods.

9

10

11

12

13

The magical 3-D, subgross, thick section histology

14

The magical 3-D, subgross, thick section histology

15

The magical 3-D, subgross, thick section histology

16



17

18

Progress in histologic-mammographic correlation can only be made by examining a histologic specimen of *greater length, width and depth."*

Tot, T, L. Tabar, P.B. Dean

Virchows Arch (2000) 437:338-344.

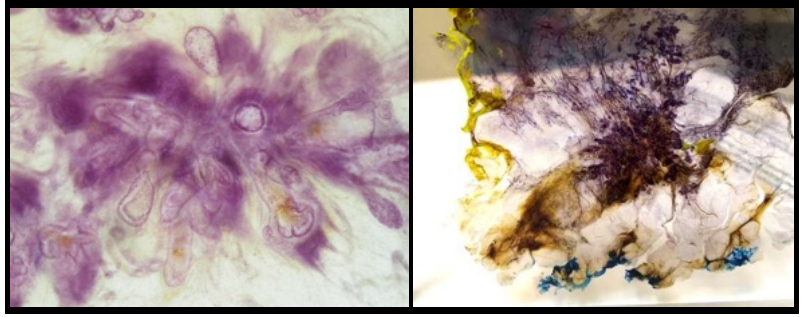

19

12-18 lobes

A drawing of a surgical preparation of a breast by Sir Astley Paston Cooper, who injected wax of different colors into the end of each duct in the nipple to outline the individual lobes.

20

The normal breast contains 12-15 lobes, each composed of a main duct and its branches (as in a tree), terminating in the lobules (like leaves on a tree), all surrounded by supporting fibrous or fatty connective tissue.

21

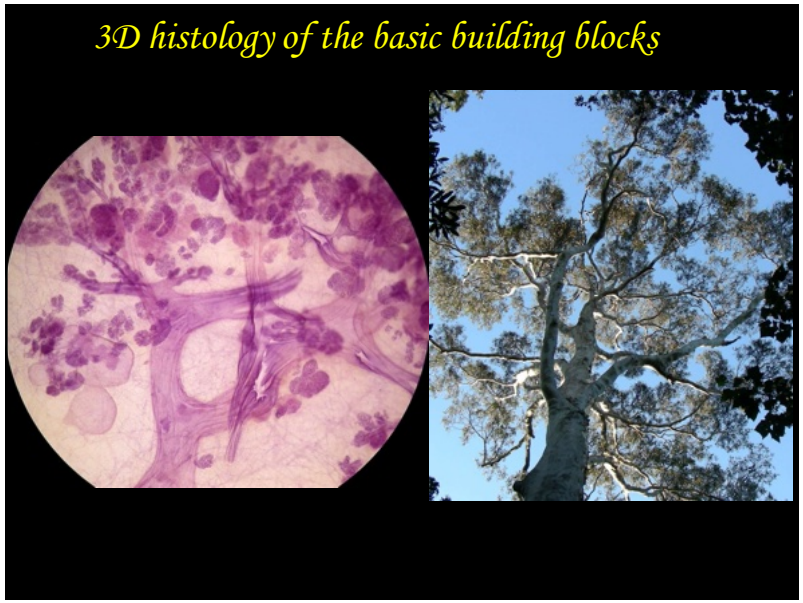

22

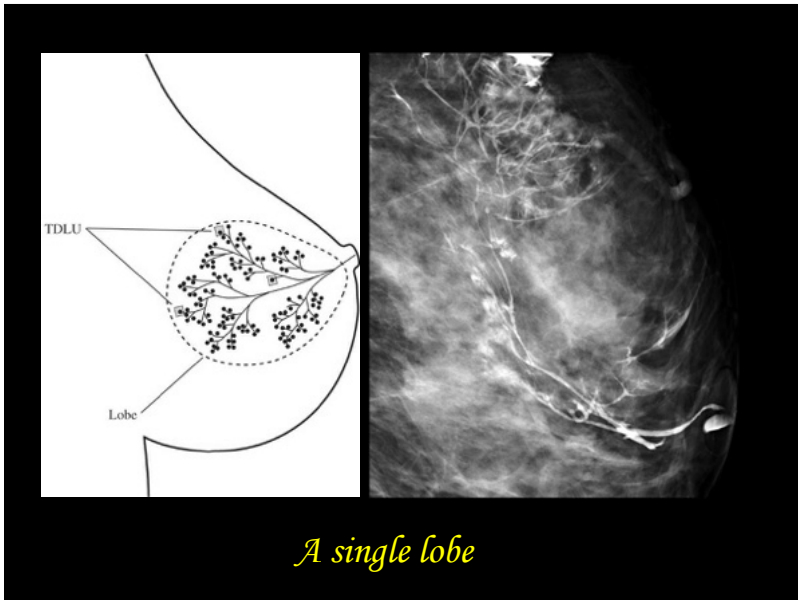

23

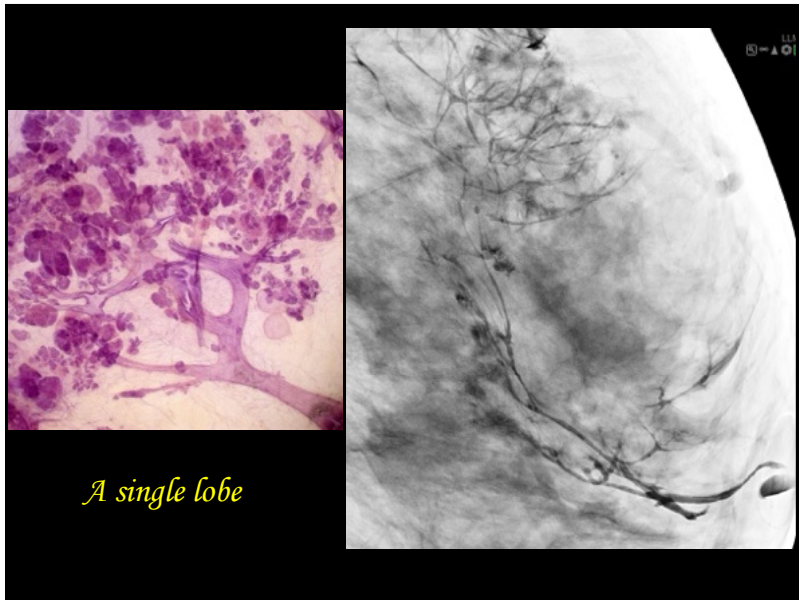

24

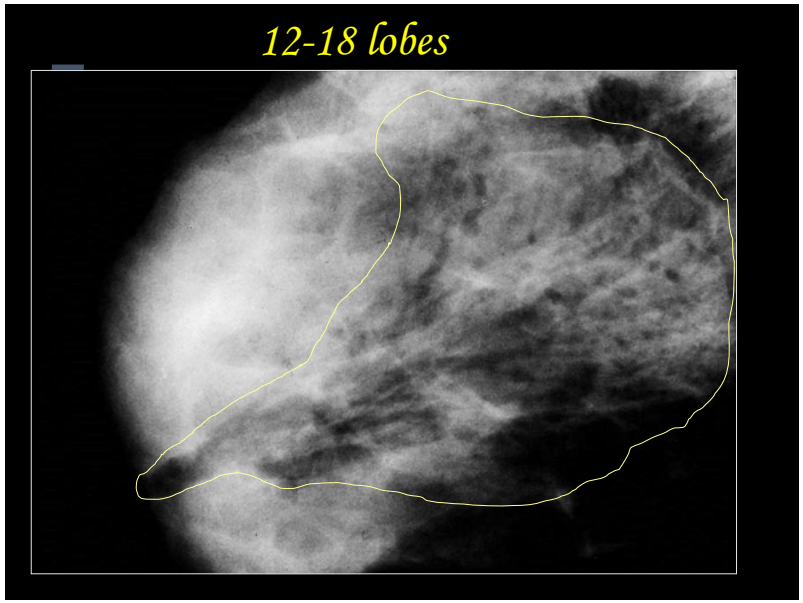
12-18 lobes

25

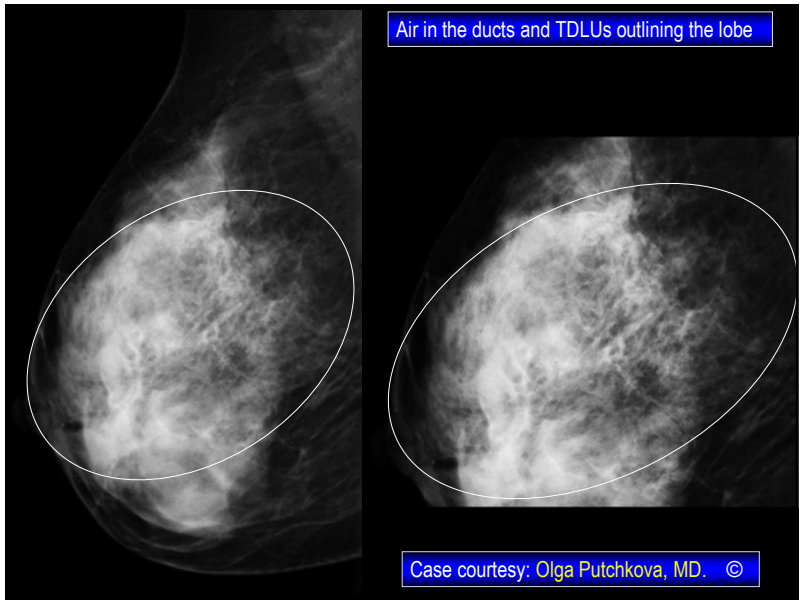
Air in the ducts and TDLUs outlining the lobe
Case courtesy: Olga Putchkova, MD. ©

26

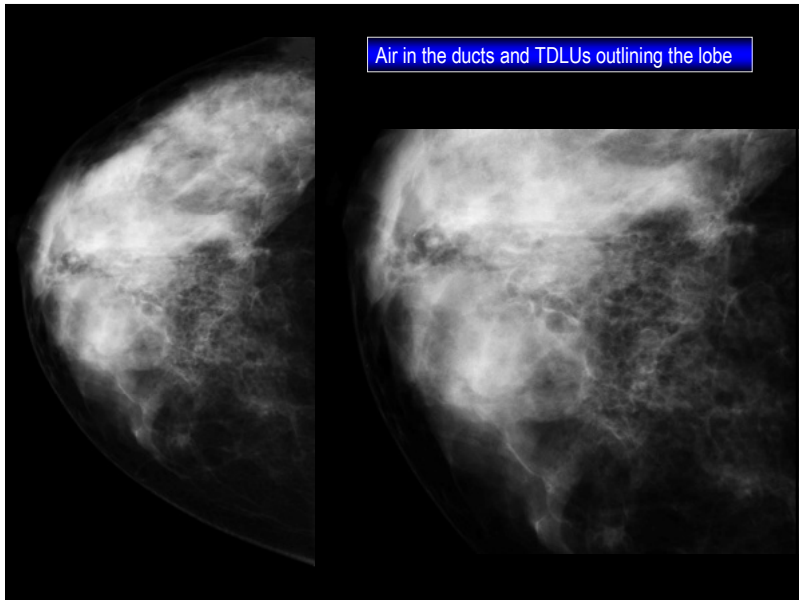
Air in the ducts and TDLUs outlining the lobe

27

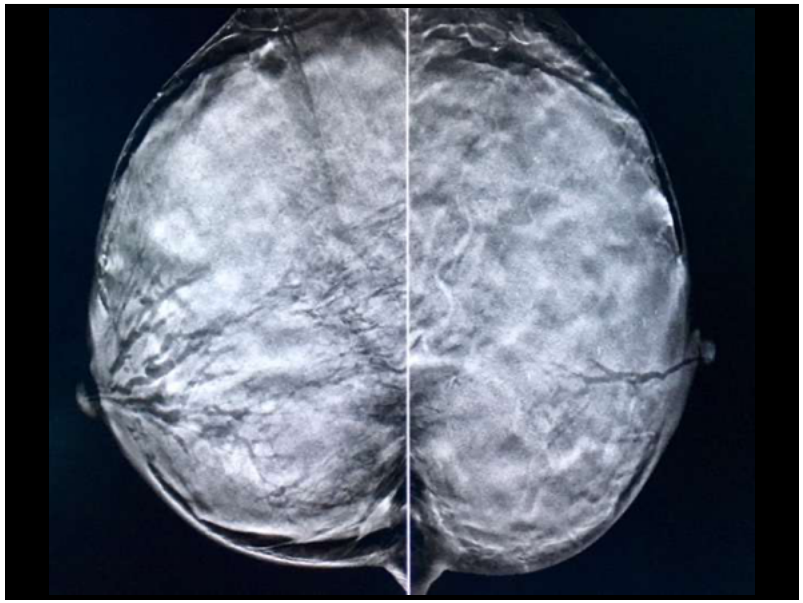

28

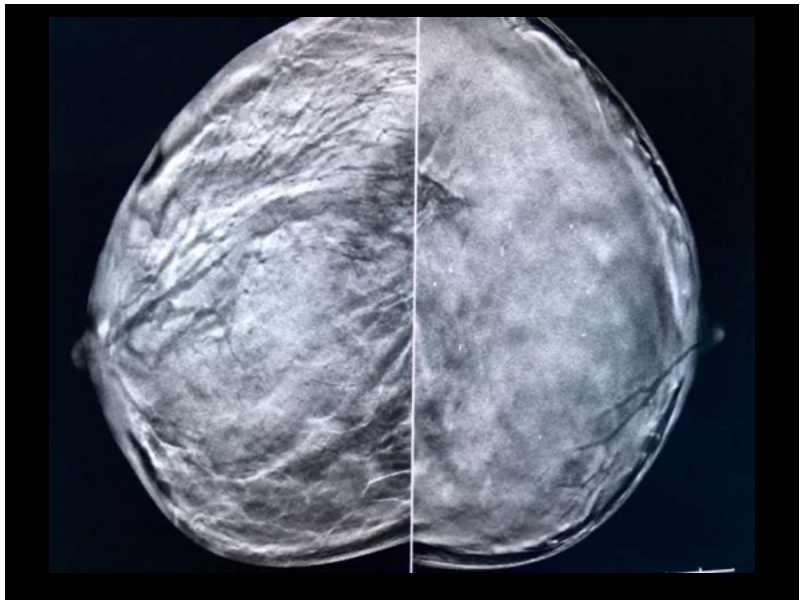

29

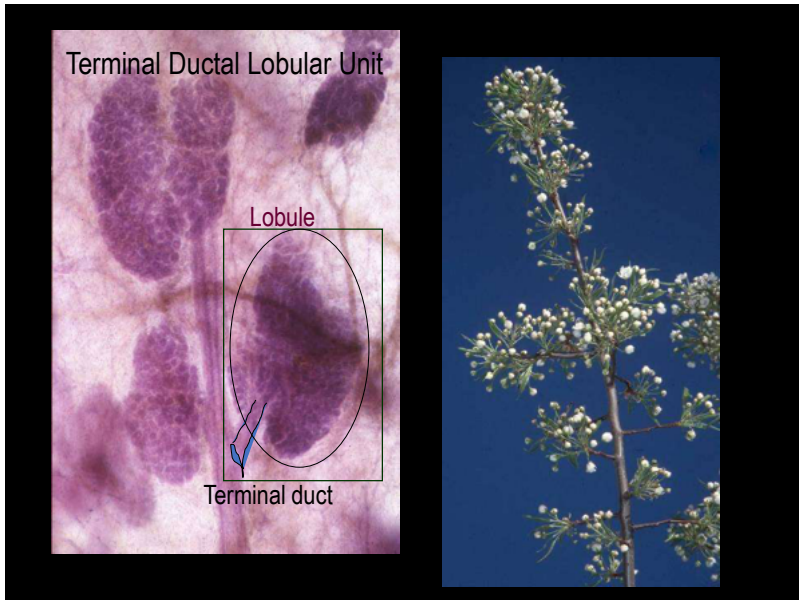
Terminal Ductal Lobular Unit
Lobule
Terminal duct

30


Understanding anatomy, physiology

31

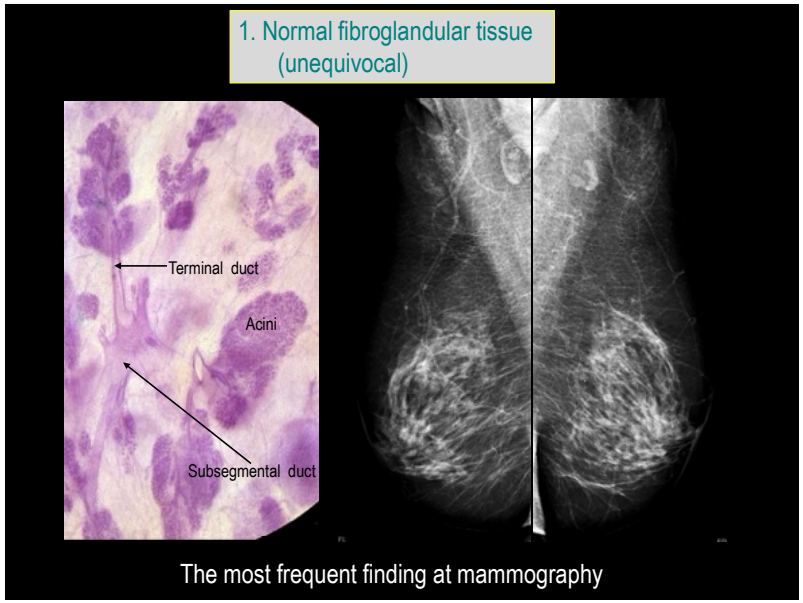
1. Normal fibroglandular tissue (unequivocal)
Terminal duct
Acini
Subsegmental duct
The most frequent finding at mammography

32

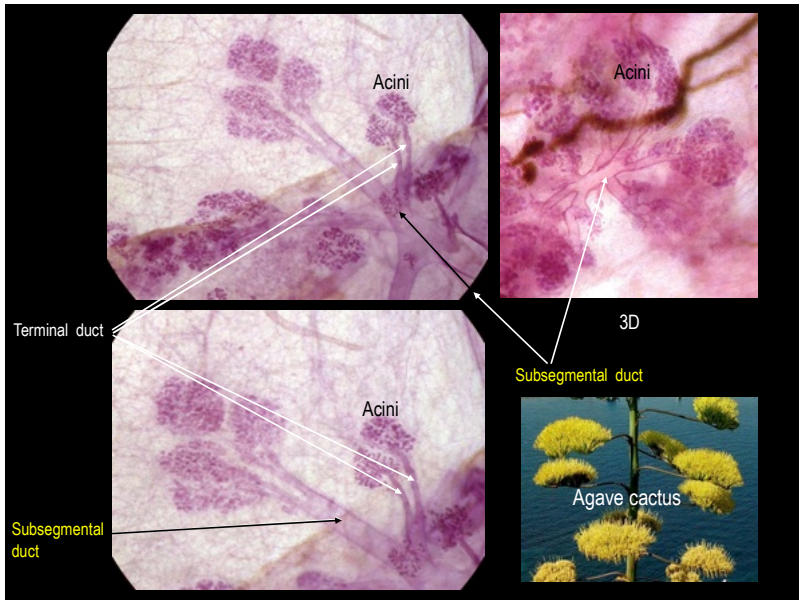
Acini
Acini
Terminal duct
3D
Subsegmental duct
Acini
Agave cactus
Subsegmental duct

33

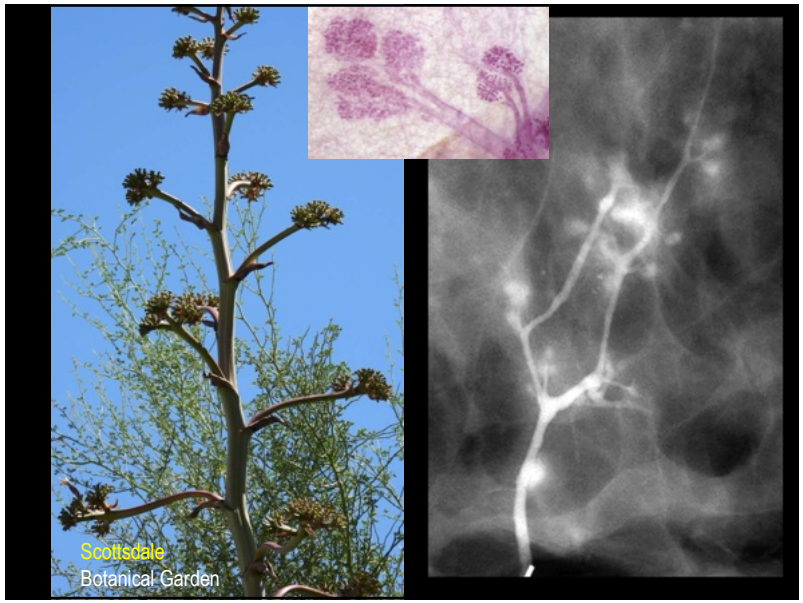
Scottsdale
Botanical Garden

34

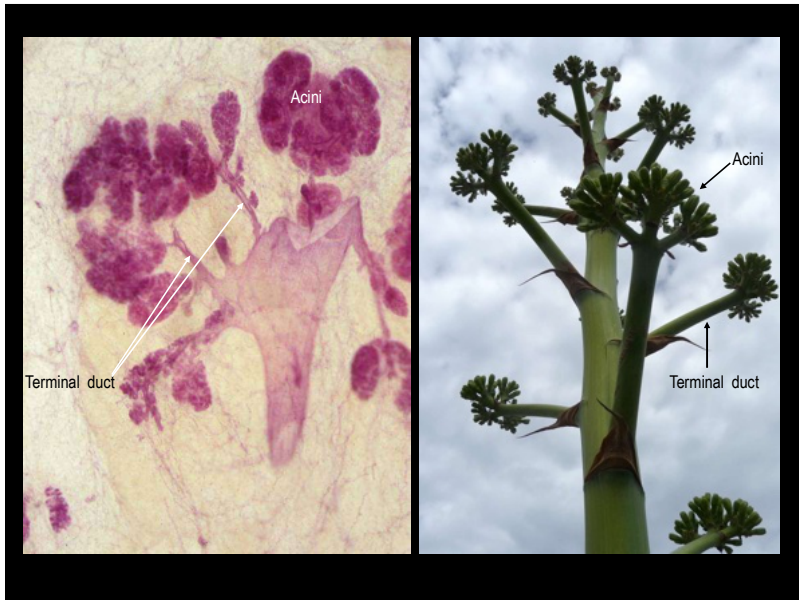
Acini
Terminal duct
Acini
Terminal duct

35

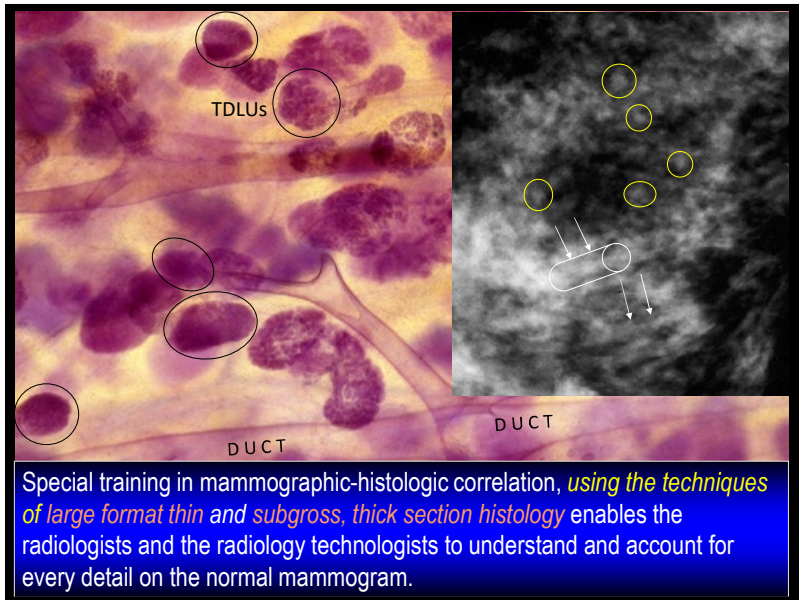
TDLUs
DUCT
DUCT
Special training in mammographic-histologic correlation, using the techniques of large format thin and subgross, thick section histology enables the radiologists and the radiology technologists to understand and account for every detail on the normal mammogram.

36

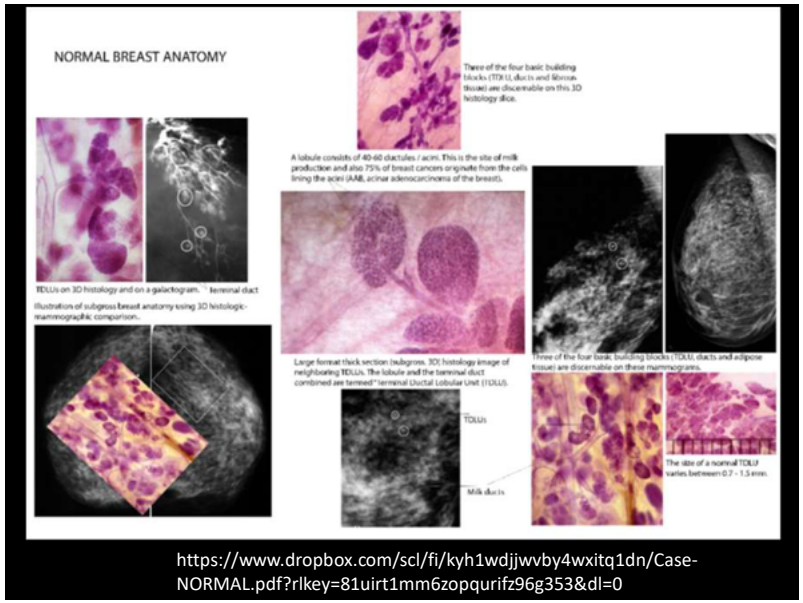
NORMAL BREAST ANATOMY
https://www.dropbox.com/scl/fi/kyh1wdjjwvby4wxitq1dn/Case-NORMAL.pdf?rlkey=81uirt1mm6zopqurifz96g353&dl=0

37

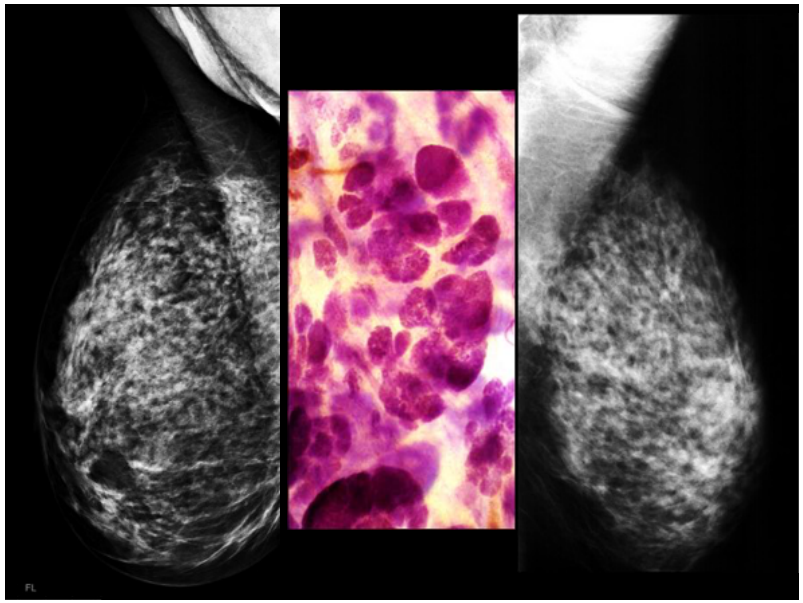

38

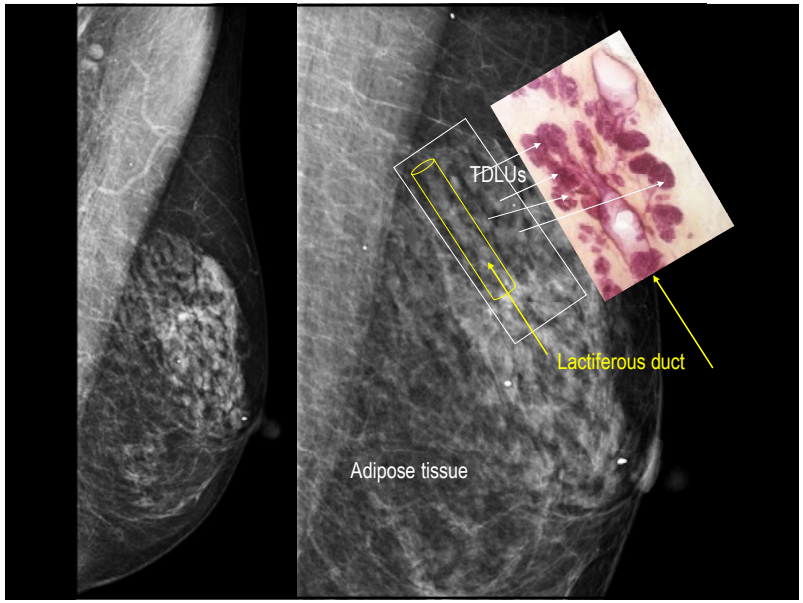
TDLUs
Lactiferous duct
Adipose tissue

39

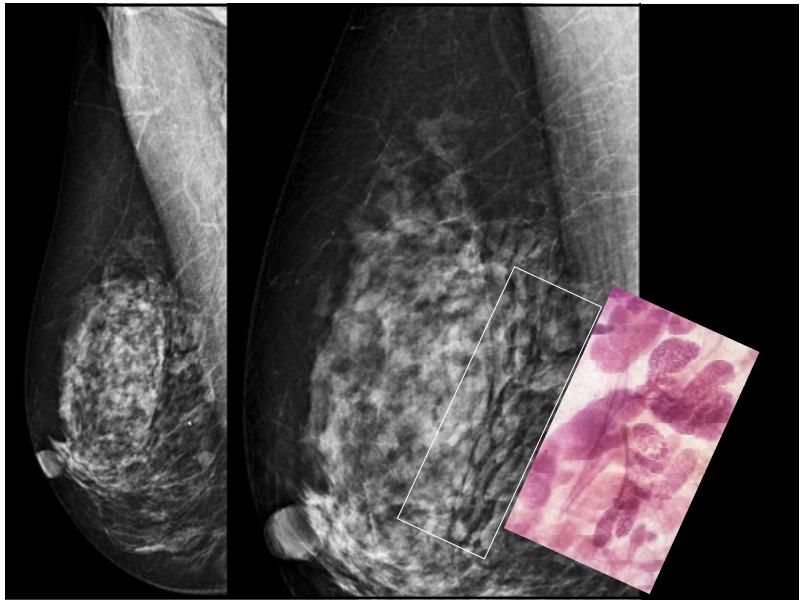

40

Histopathologic-mammographic correlation

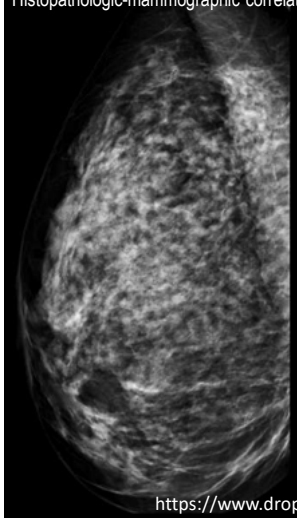

https://www.dropbox.com/scl/fi/c0chkhcobjqxliqfcqz2e/Tdlu-New-W-Music-Copy-1-USE-THIS.mp4?rlkey=7nxln3315p8zfaxi2pd4at4vz&dl=0

41

Contents lists available at ScienceDirect

European Journal of Radiology

journal homepage: www.elsevier.com/locate/ejrad

Breast cancers originating from the terminal ductal lobular units: *In situ* and invasive acinar adenocarcinoma of the breast, AAB

László Tabár [a,*], Peter B. Dean [b], F. Lee Tucker [c], Amy Ming-Fang Yen [d], Jean Ching-Yuan Fann [e], Abbie Ting-Yu Lin [f], Robert A. Smith [g], Stephen W. Duffy [h], Tony Hsiu-Hsi Chen [f]

https://www.dropbox.com/scl/fi/epzhqavxd1syjvsjnnnkm/Article-2.pdf?rlkey=xmb5c2iw0mvgsa1he1zgt0brd&dl=0

AI generated video of the article above:

https://youtu.be/KGZfRQGWLTU?si=VXSVmJqfb20lER7J

42

The lobule and the terminal duct, which drains it, form an integrated functional entity, called the **terminal ductal lobular unit (TDLU)**

Most benign and malignant breast diseases originate from the TDLU, not from the ducts.

43

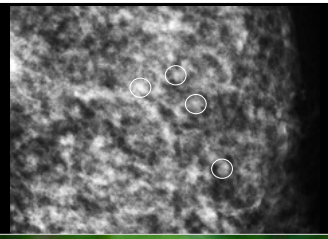

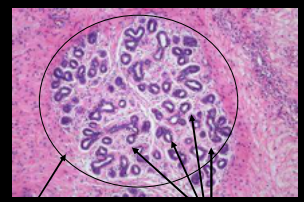

Lobule

Acini

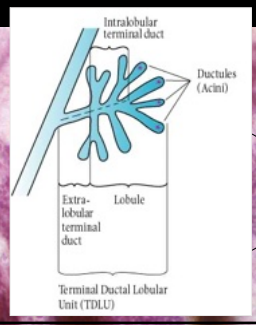

44

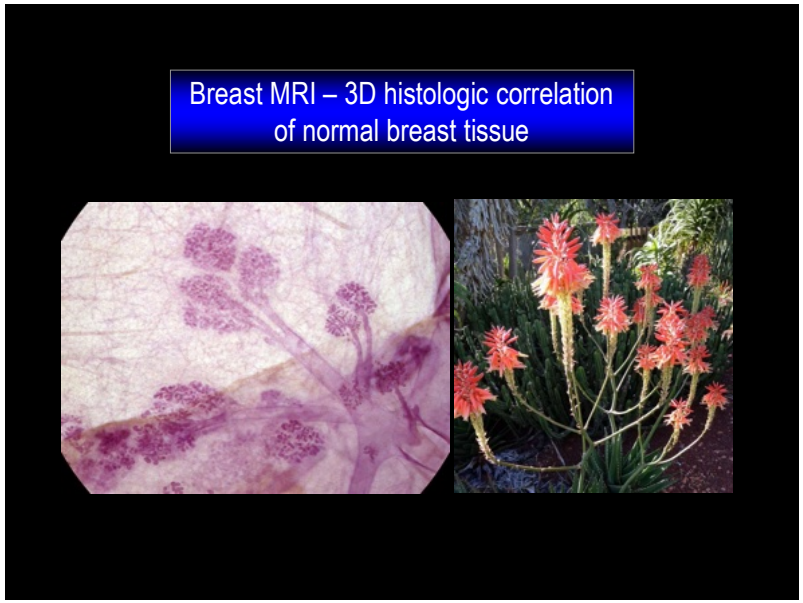
Breast MRI – 3D histologic correlation
of normal breast tissue

45

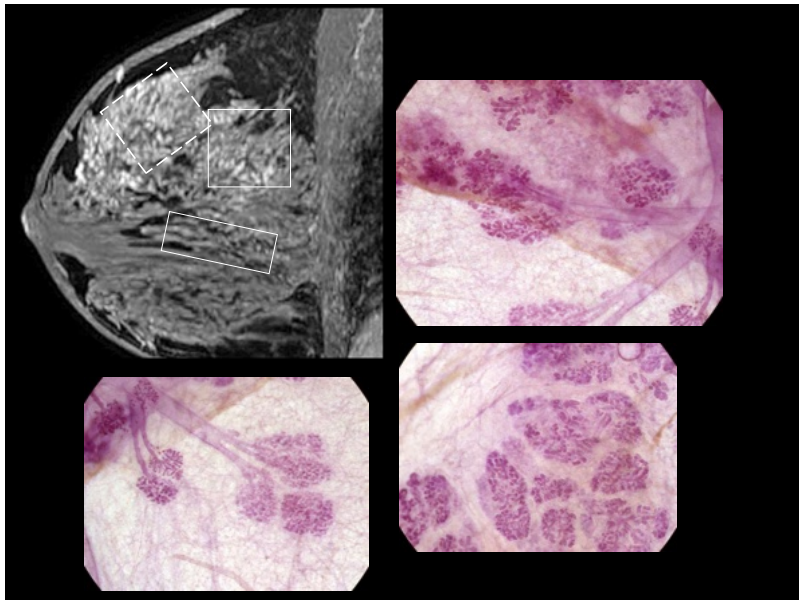

46

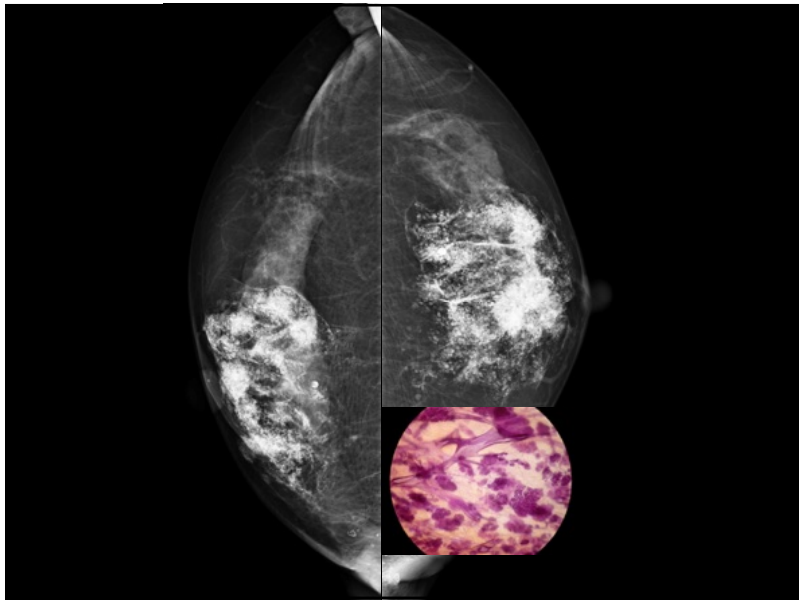

47

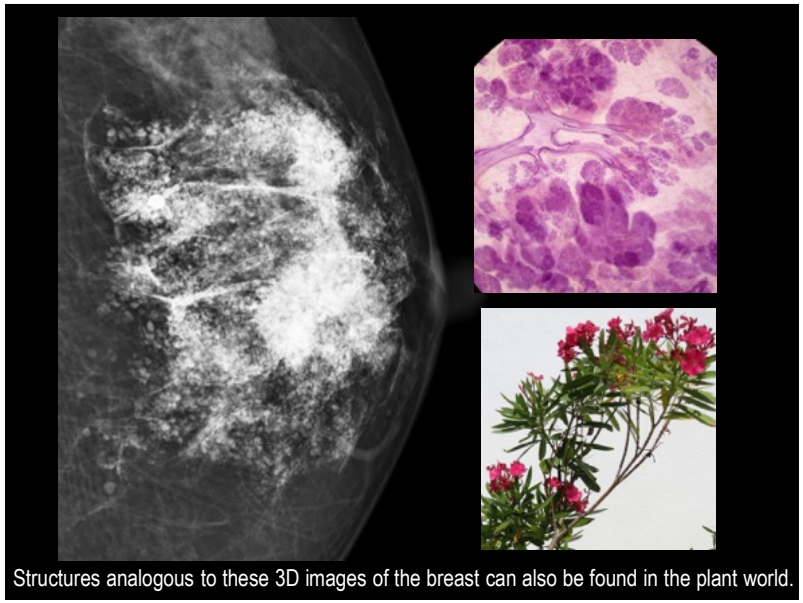
Structures analogous to these 3D images of the breast can also be found in the plant world.

48

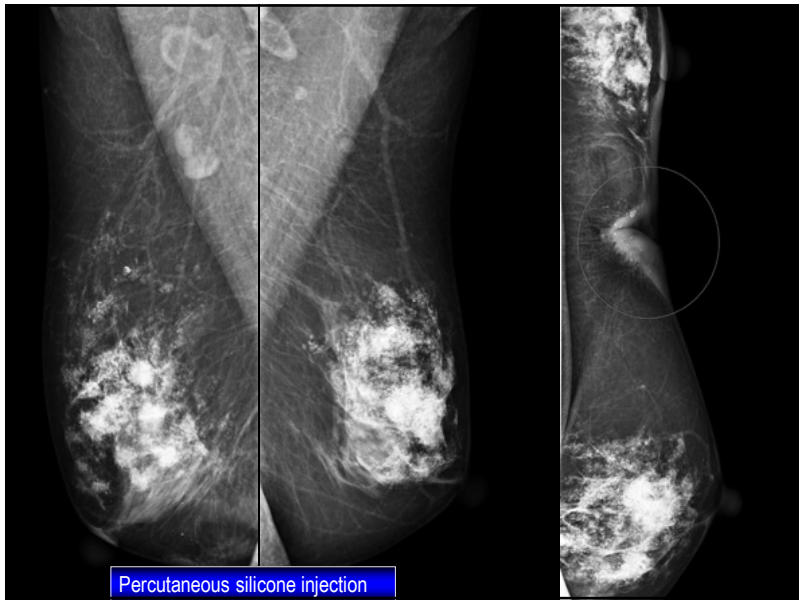
Percutaneous silicone injection

49

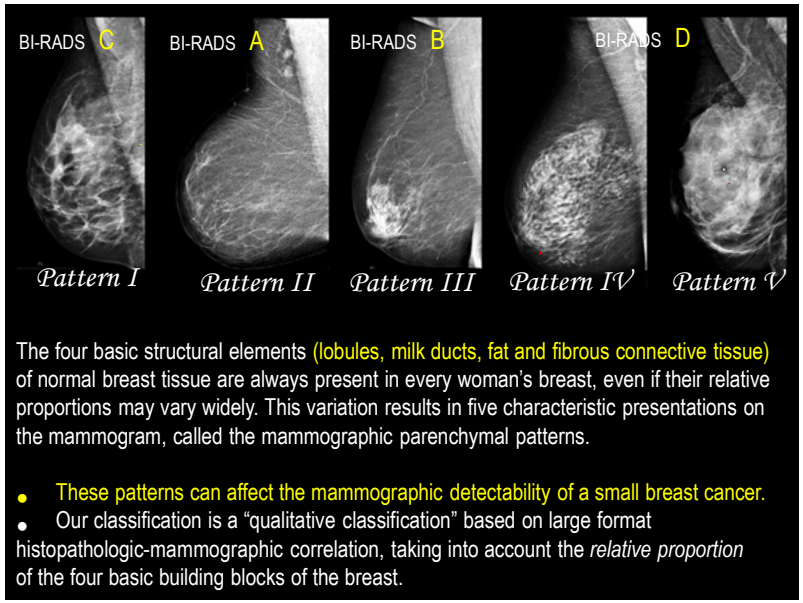
BI-RADS C
BI-RADS A
BI-RADS B
BI-RADS D
Pattern I
Pattern II
Pattern III
Pattern IV
Pattern V
The four basic structural elements (lobules, milk ducts, fat and fibrous connective tissue) of normal breast tissue are always present in every woman's breast, even if their relative proportions may vary widely. This variation results in five characteristic presentations on the mammogram, called the mammographic parenchymal patterns.
These patterns can affect the mammographic detectability of a small breast cancer.
Our classification is a "qualitative classification" based on large format histopathologic-mammographic correlation, taking into account the relative proportion of the four basic building blocks of the breast.

50

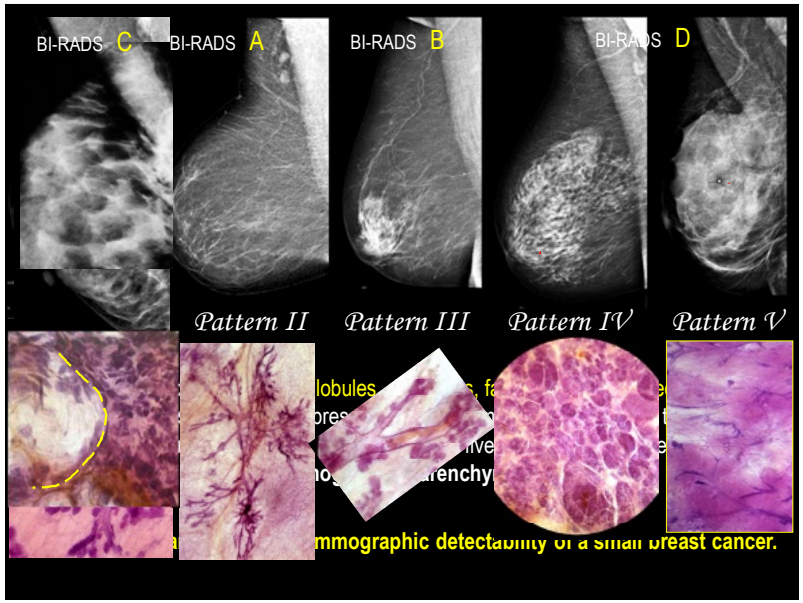
BI-RADS C
BI-RADS A
BI-RADS B
BI-RADS D
Pattern II
Pattern III
Pattern IV
Pattern V

51

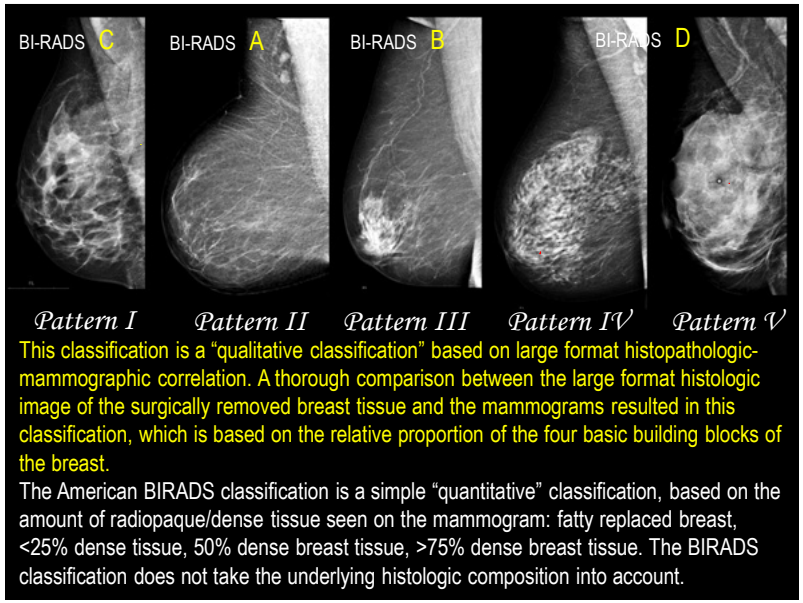
BI-RADS C
BI-RADS A
BI-RADS B
BI-RADS D
Pattern I
Pattern II
Pattern III
Pattern IV
Pattern V
This classification is a "qualitative classification" based on large format histopathologic-mammographic correlation. A thorough comparison between the large format histologic image of the surgically removed breast tissue and the mammograms resulted in this classification, which is based on the relative proportion of the four basic building blocks of the breast.
The American BIRADS classification is a simple "quantitative" classification, based on the amount of radiopaque/dense tissue seen on the mammogram: fatty replaced breast, <25% dense tissue, 50% dense breast tissue, >75% dense breast tissue. The BIRADS classification does not take the underlying histologic composition into account.

52

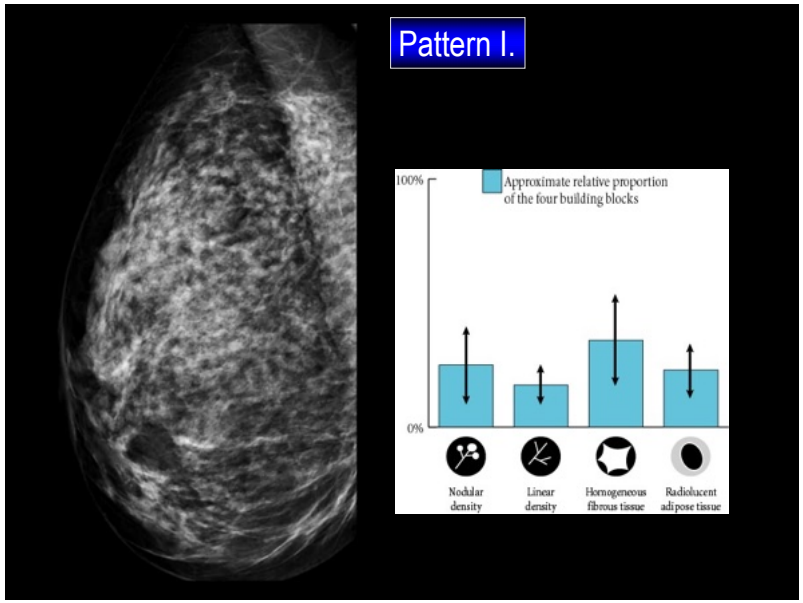
Pattern I.
Approximate relative proportion of the four building blocks
100%
0%
Nodular density
Linear density
Horogeneous fibrous tissue
Radiolucent adipose tissue

53

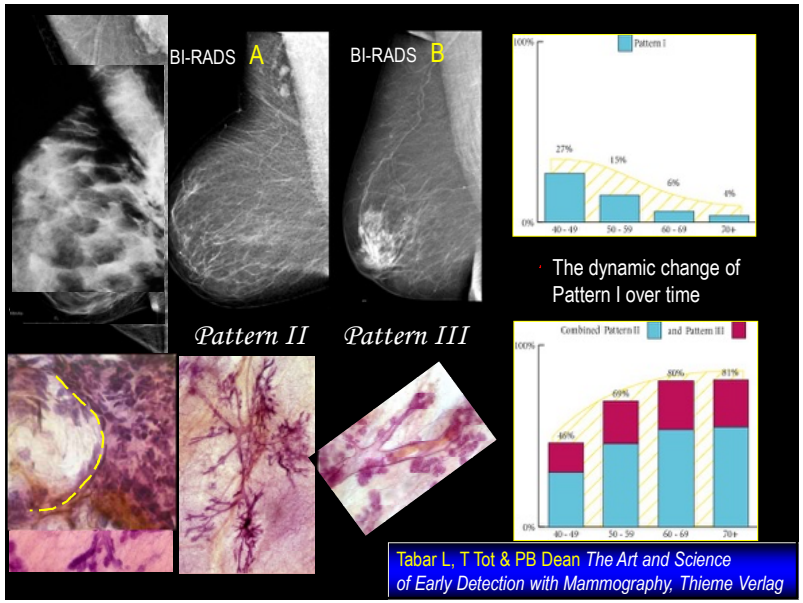
BI-RADS A
BI-RADS B
Pattern I
The dynamic change of Pattern I over time
Pattern II
Pattern III
Combined Pattern II and Pattern III
Tabar L, T Tot & PB Dean The Art and Science of Early Detection with Mammography, Thieme Verlag

54

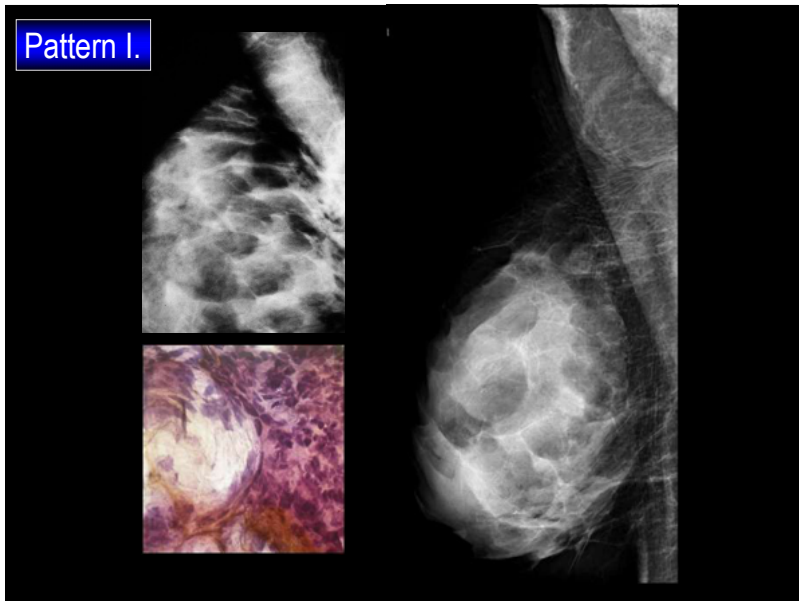
Pattern I.

55

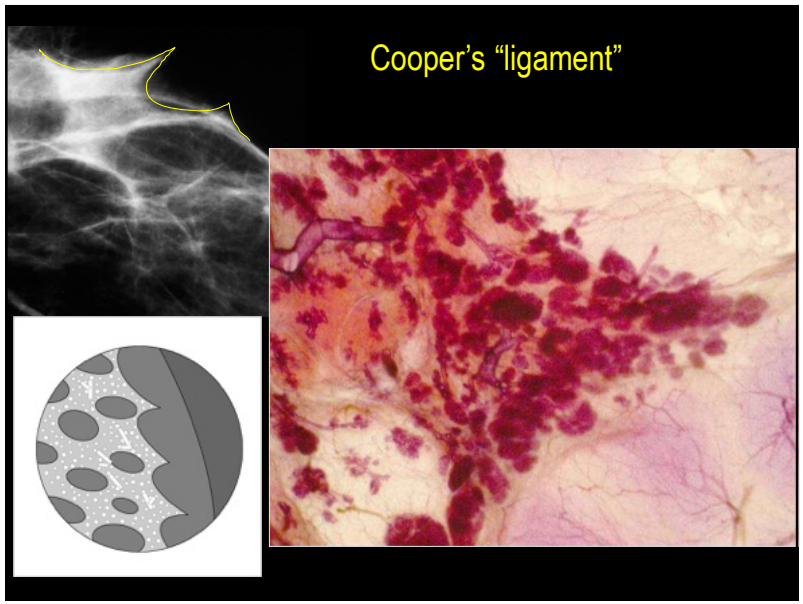
Cooper's "ligament"

56

Cooper's "ligament" is NOT a ligament.

It consists of three basic building blocks of the breast.

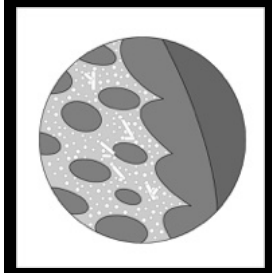

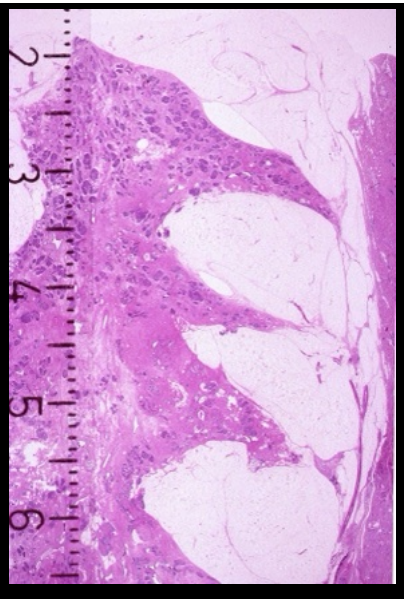

57

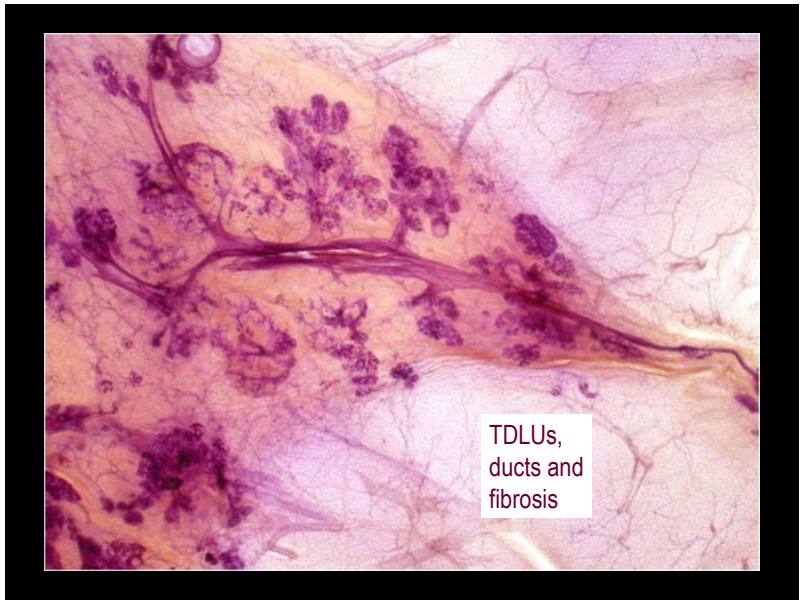

58

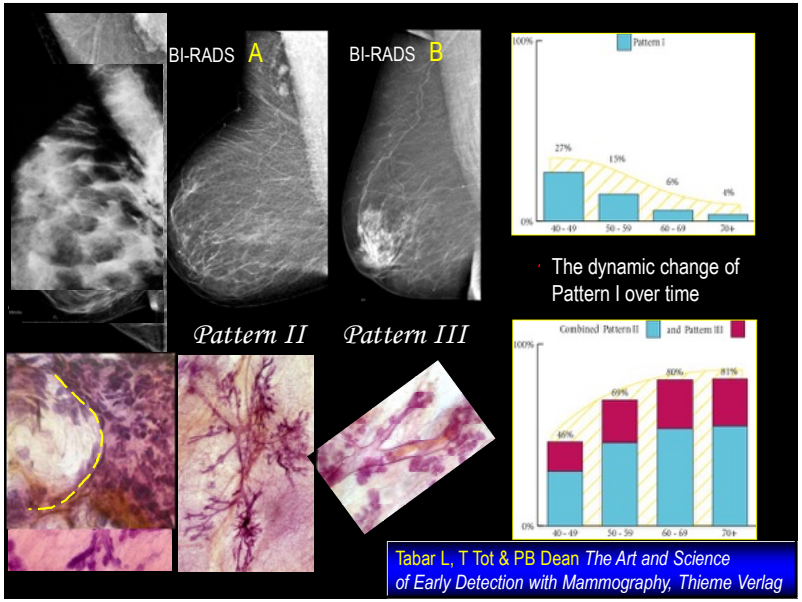

59

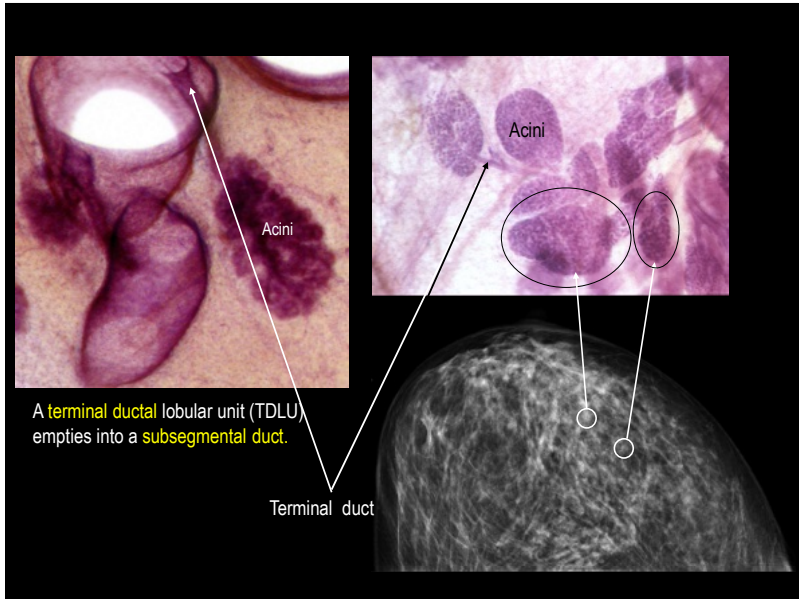

60

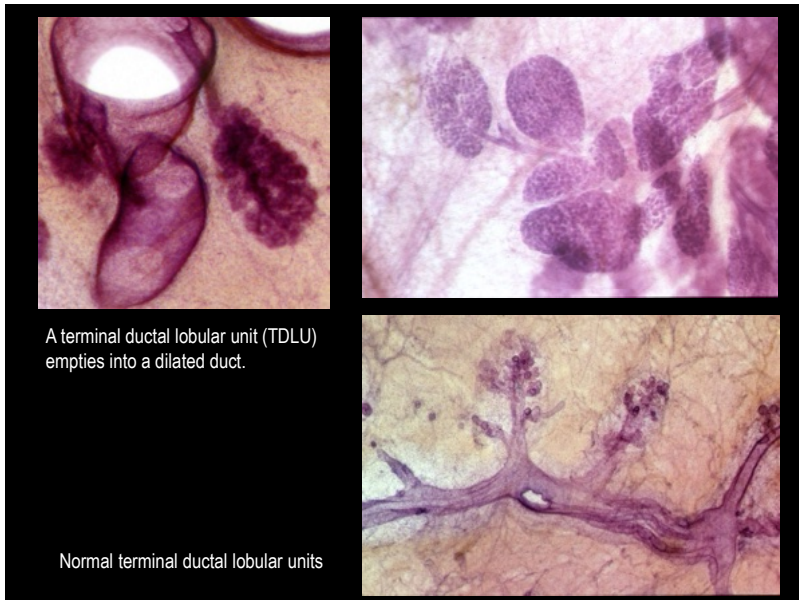
A terminal ductal lobular unit (TDLU) empties into a dilated duct.
Normal terminal ductal lobular units

61

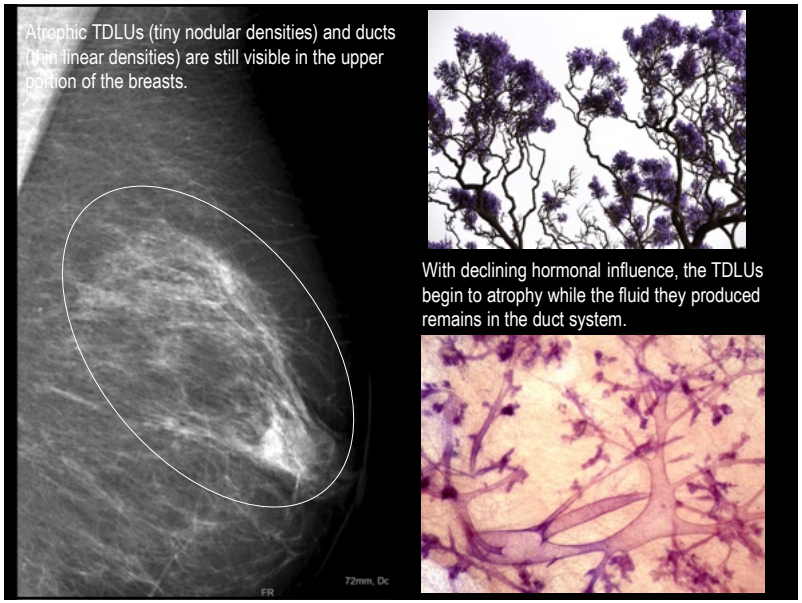
Atrophic TDLUs (tiny nodular densities) and ducts (thin linear densities) are still visible in the upper portion of the breasts.
With declining hormonal influence, the TDLUs begin to atrophy while the fluid they produced remains in the duct system.

62

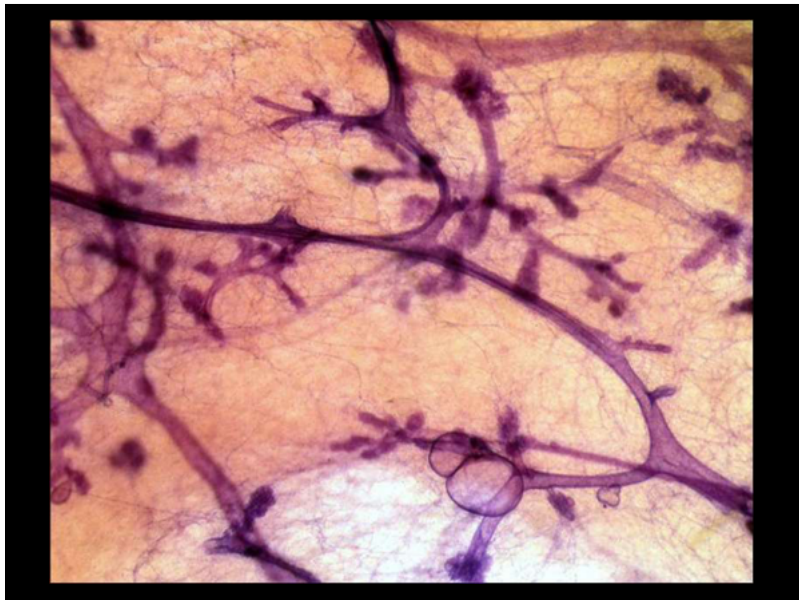

63

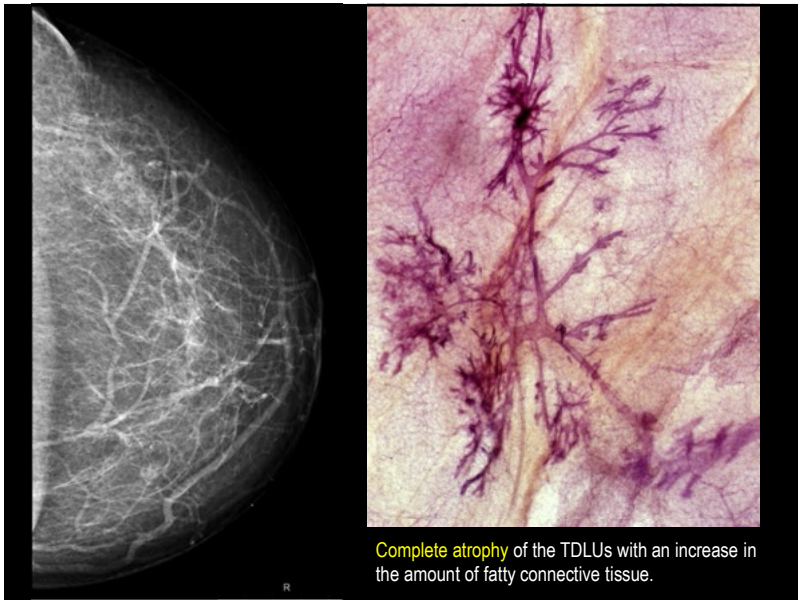
Complete atrophy of the TDLUs with an increase in the amount of fatty connective tissue.

64

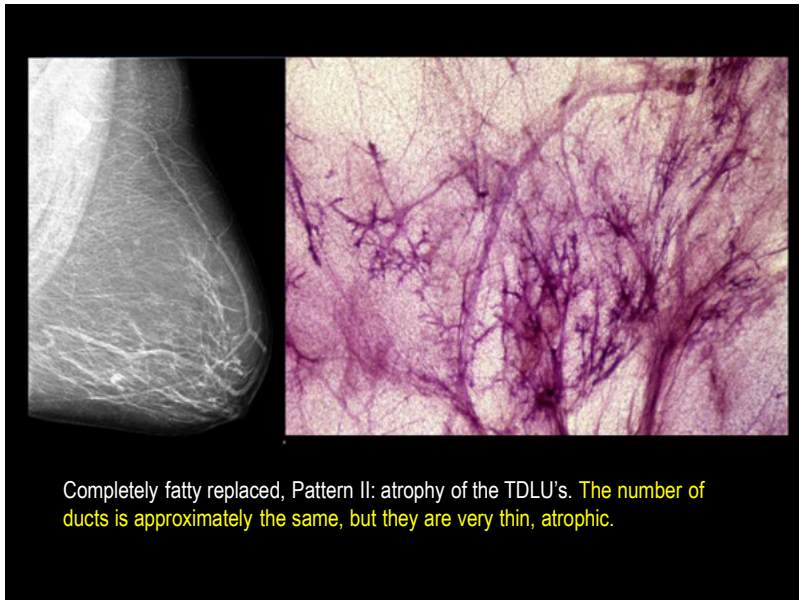

Completely fatty replaced, Pattern II: atrophy of the TDLU's. The number of ducts is approximately the same, but they are very thin, atrophic.

65

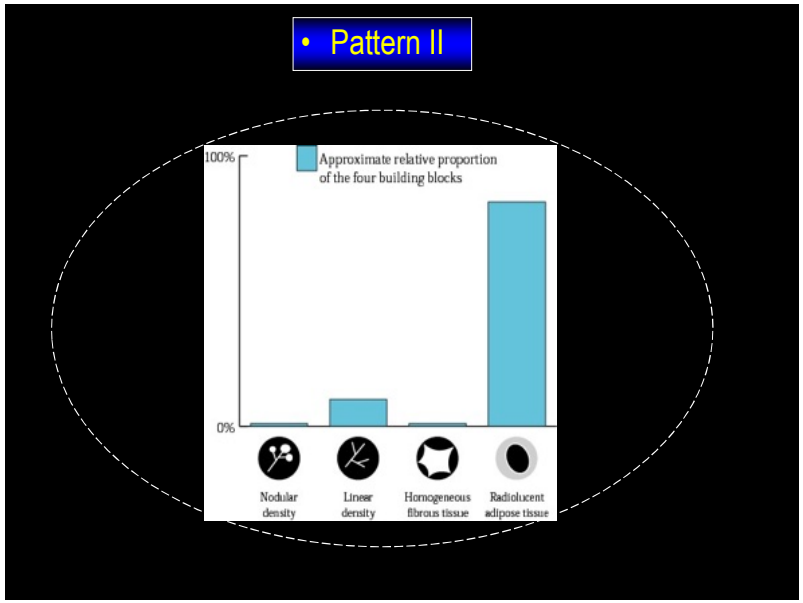

66

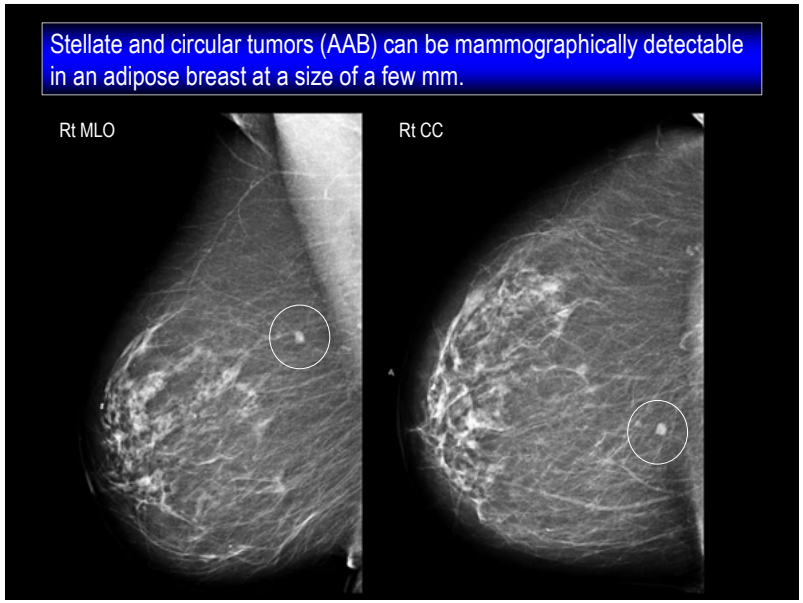

67

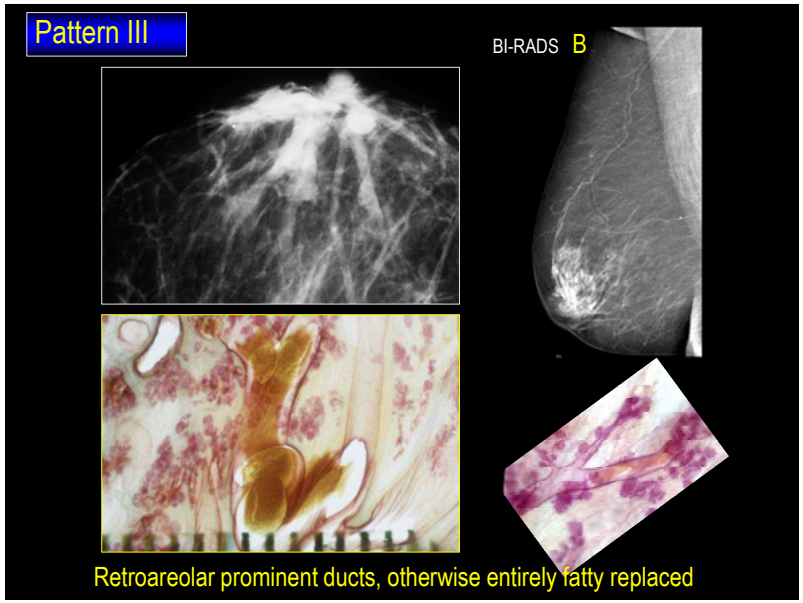

68

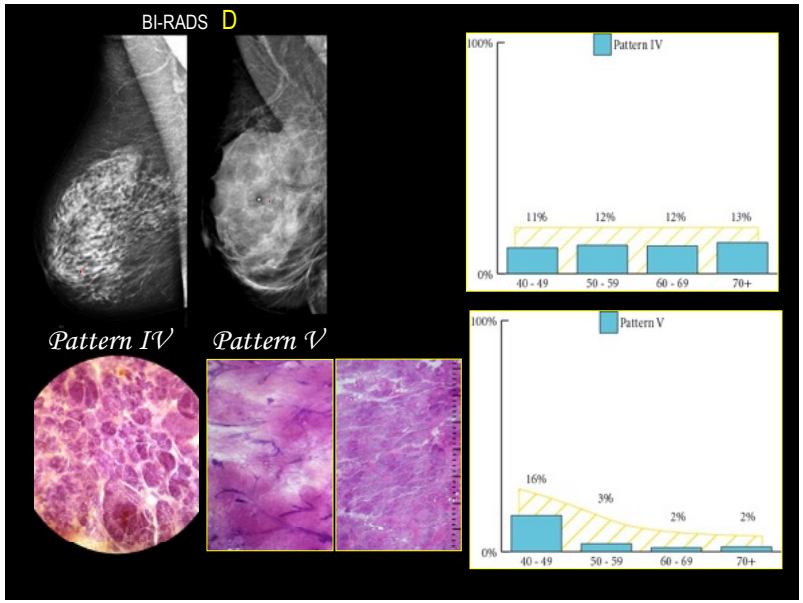
BI-RADS D
Pattern IV
Pattern V
100%
0%
Pattern IV
11%
12%
12%
13%
40 - 49
50 - 59
60 - 69
70+
Pattern V
16%
3%
2%
2%

69

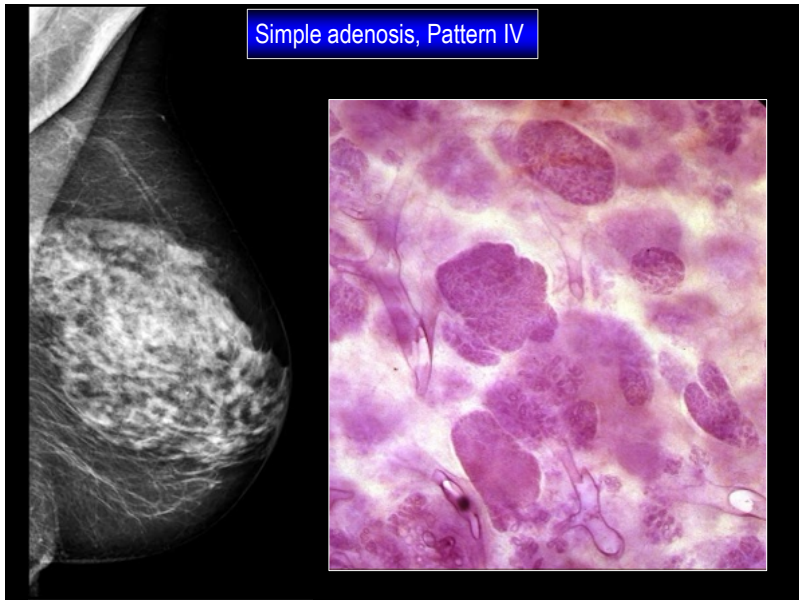
Simple adenosis, Pattern IV

70

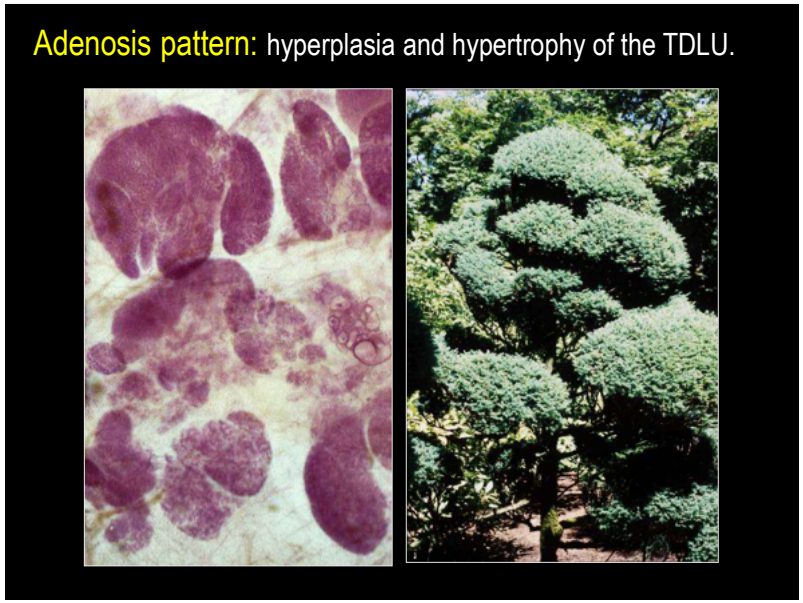
Adenosis pattern: hyperplasia and hypertrophy of the TDLU.

71

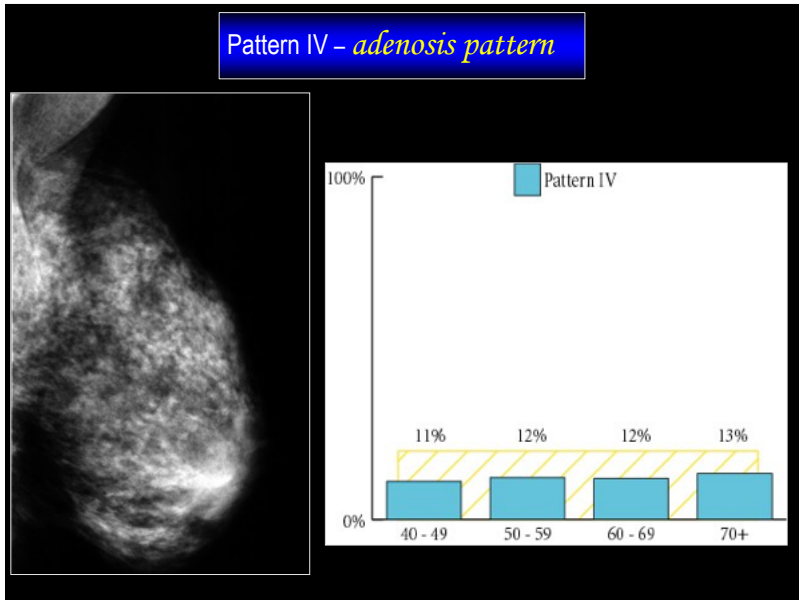
Pattern IV – adenosis pattern
100%
0%
Pattern IV
11%
12%
12%
13%
40 - 49
50 - 59
60 - 69
70+

72

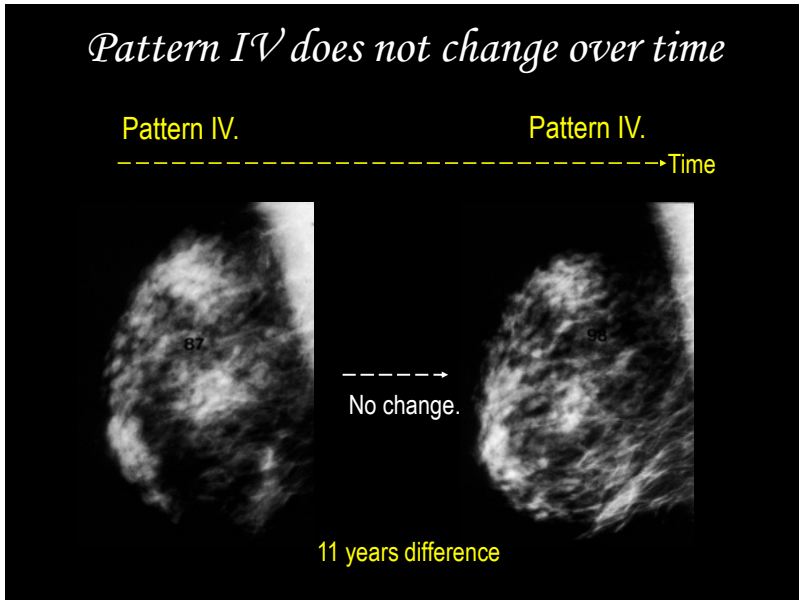

73

© International Epidemiological Association 2000 Printed in Great Britain International Journal of Epidemiology 2000;29:11–19

Mammographic parenchymal patterns and risk of breast cancer at and after a prevalence screen in Singaporean women

RW Jakes,[a] SW Duffy,[b] FC Ng,[c] F Gao[a,d] and EH Ng[c]

Background The objective of this study was to assess the effect of mammographic parenchymal patterns on risk of breast cancer detected at first screen or in the period following a negative screen.

Methods The study utilizes a nested case-control design with 132 breast cancer patients detected at first screen (from a total of 29 193 screened) and 42 breast cancer patients detected in the period following the first screen. These patients were matched to 348 screened-negative controls. The mammograms were classified according to Tabar's classification for parenchymal pattern and statistical analysis was done by conditional logistic regression.

Results The risk of breast cancer for women with Tabar pattern IV was significantly high when compared to the remaining patterns (odds ratio 2.59). Risk factors for Tabar pattern IV coincided largely with established risk factors for breast cancer.

Conclusion The study confirms the increased risk of breast cancer associated with Tabar pattern IV (approximately Wolfe pattern P2), in an Asian population. This pattern is associated with nulliparity and high educational status and is strongly associated with grade 3 cancers.

Keywords Breast cancer, mammography, parenchymal patterns, Asian women, case control study

Accepted 27 July 1999

Downloaded from http://ije.oxfordjournals.org/ by guest on

74

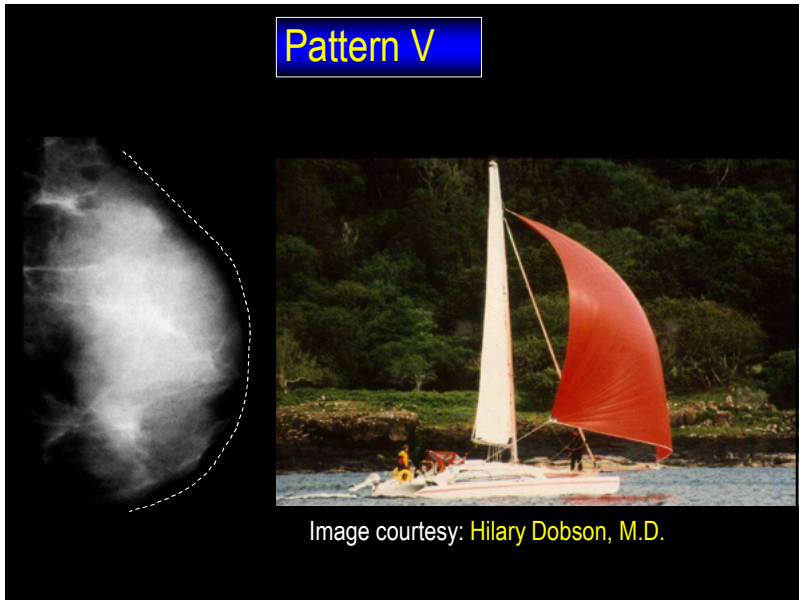

75

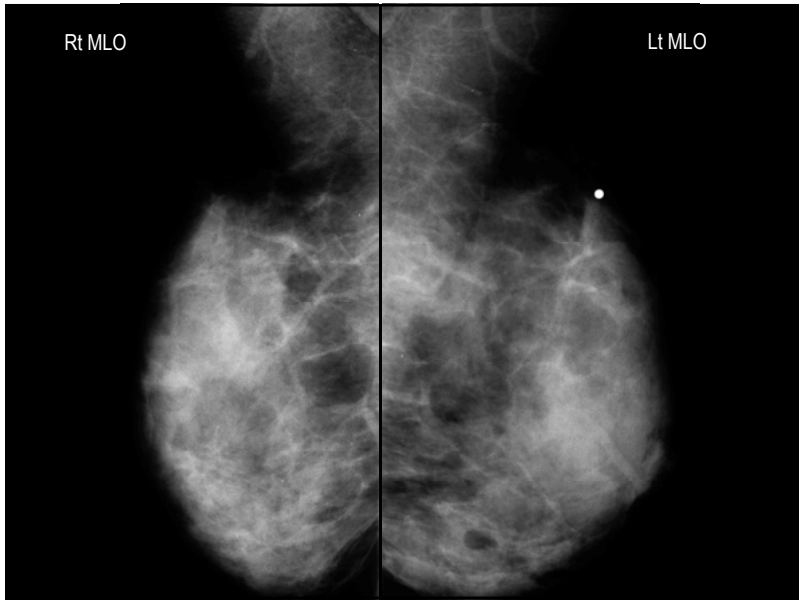

76

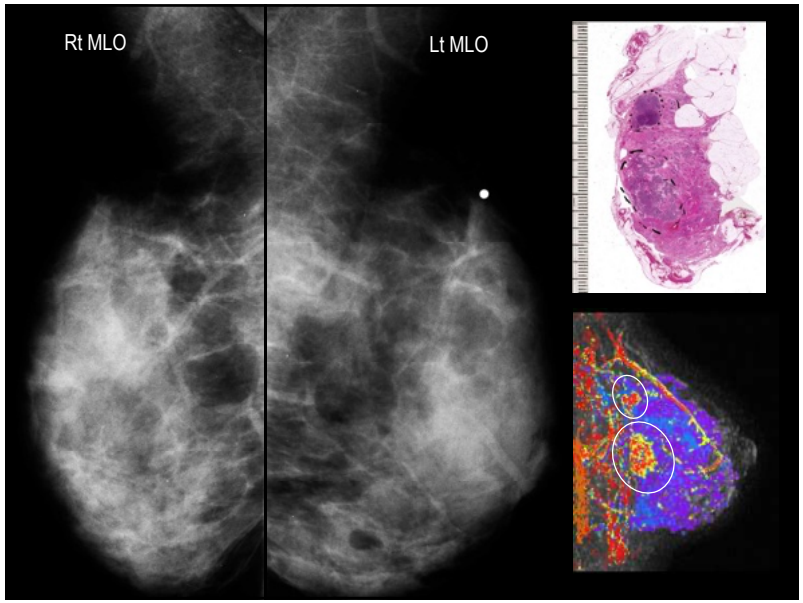
Rt MLO
Lt MLO

77

Rt MLO
Lt MLO

78

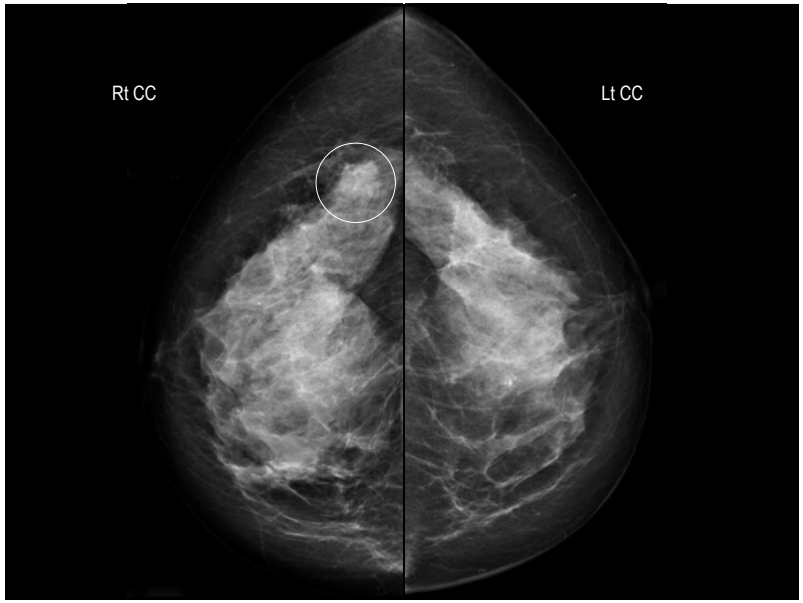
Rt CC
Lt CC

79

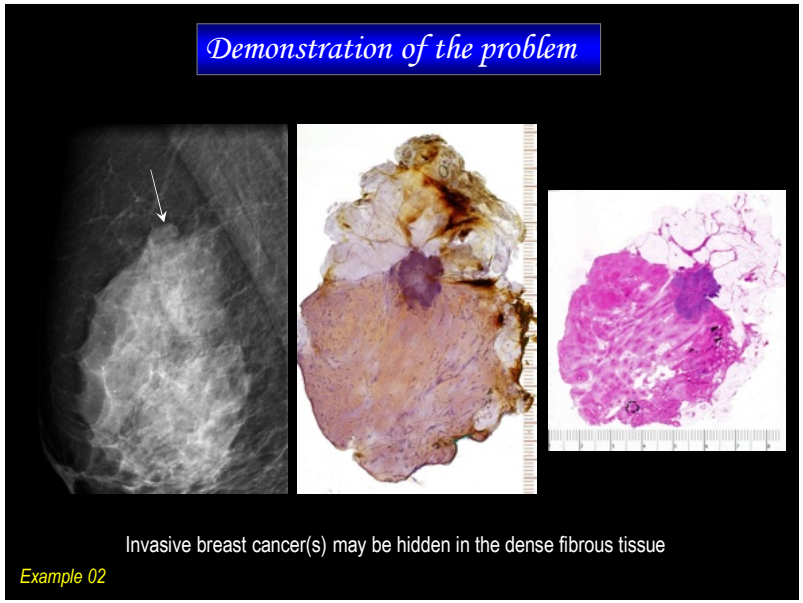
Demonstration of the problem
Invasive breast cancer(s) may be hidden in the dense fibrous tissue
Example 02

80

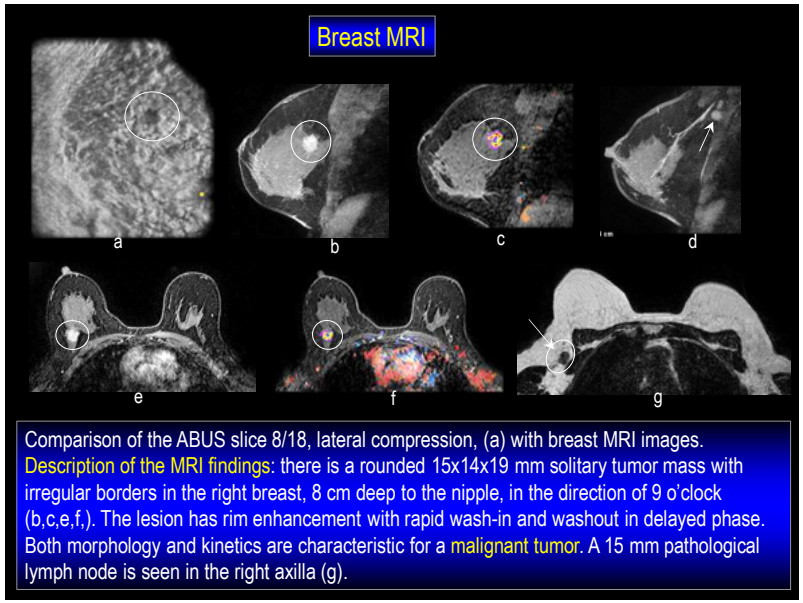
Breast MRI
a
b
c
d
e
f
g
Comparison of the ABUS slice 8/18, lateral compression, (a) with breast MRI images.
Description of the MRI findings: there is a rounded 15x14x19 mm solitary tumor mass with irregular borders in the right breast, 8 cm deep to the nipple, in the direction of 9 o'clock (b,c,e,f,). The lesion has rim enhancement with rapid wash-in and washout in delayed phase. Both morphology and kinetics are characteristic for a malignant tumor. A 15 mm pathological lymph node is seen in the right axilla (g).

81

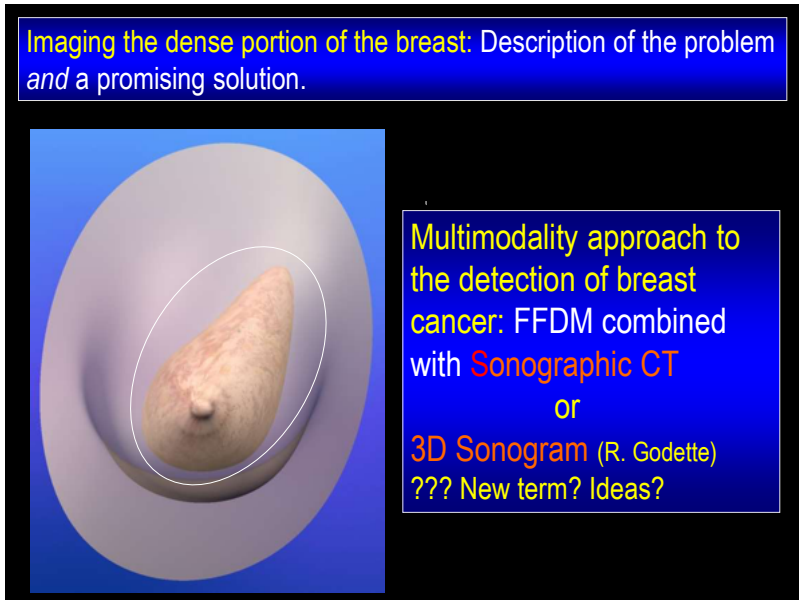
Imaging the dense portion of the breast: Description of the problem *and* a promising solution.
Multimodality approach to the detection of breast cancer: FFDM combined with Sonographic CT
or
3D Sonogram (R. Godette)
??? New term? Ideas?

82

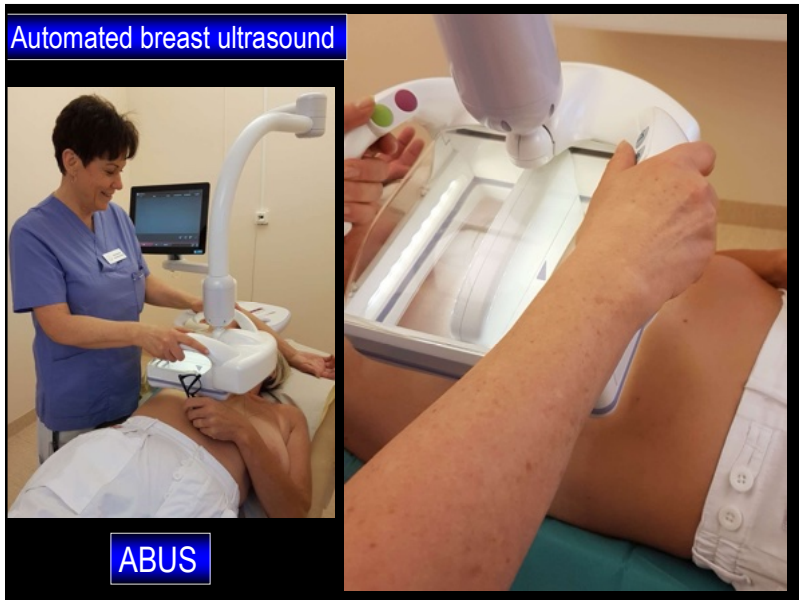
Automated breast ultrasound
ABUS

83

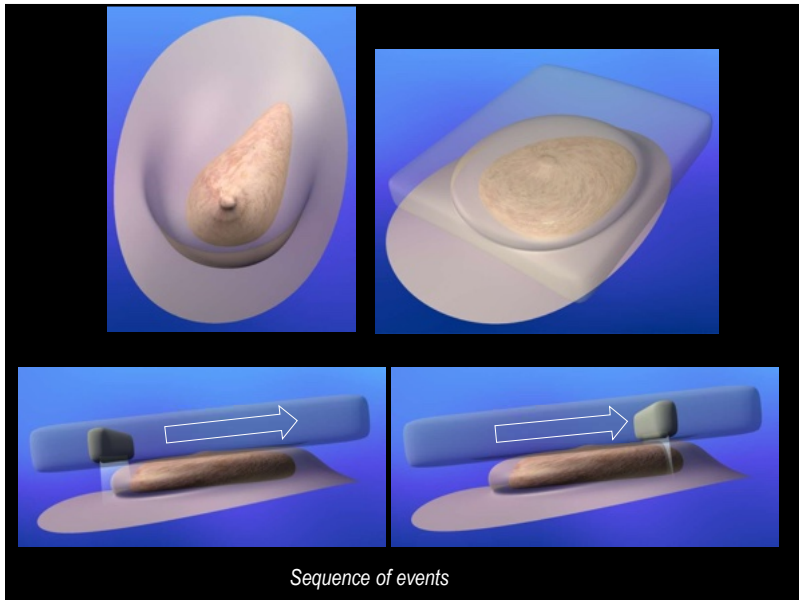
Sequence of events

84

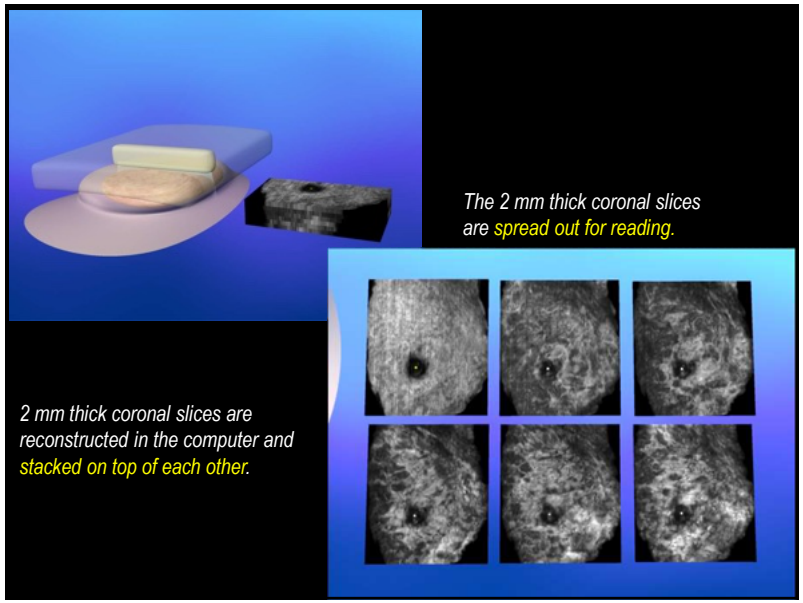
The 2 mm thick coronal slices are spread out for reading.
2 mm thick coronal slices are reconstructed in the computer and stacked on top of each other.

85

86

87

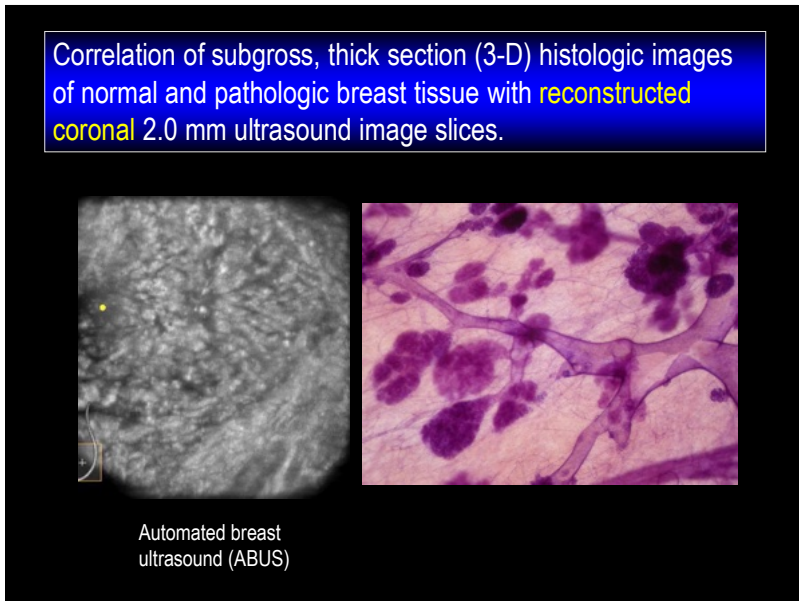
Correlation of subgross, thick section (3-D) histologic images of normal and pathologic breast tissue with reconstructed coronal 2.0 mm ultrasound image slices.
Automated breast ultrasound (ABUS)

88

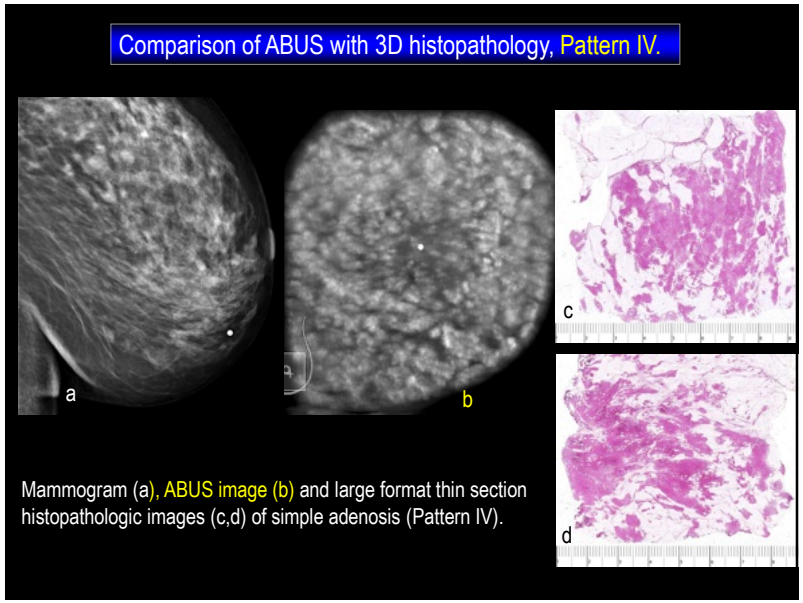
Comparison of ABUS with 3D histopathology, Pattern IV.
a
b
c
d
Mammogram (a), ABUS image (b) and large format thin section histopathologic images (c,d) of simple adenosis (Pattern IV).

89

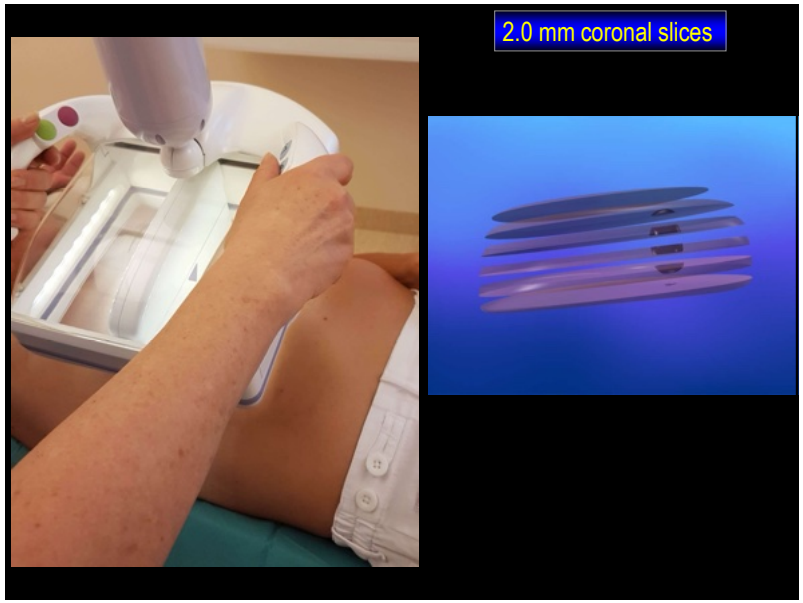
2.0 mm coronal slices

90

Tut-tut, nästa anhalt är i Dockehus.
Där kliver han snabbt av, vår hungriga mus.

91

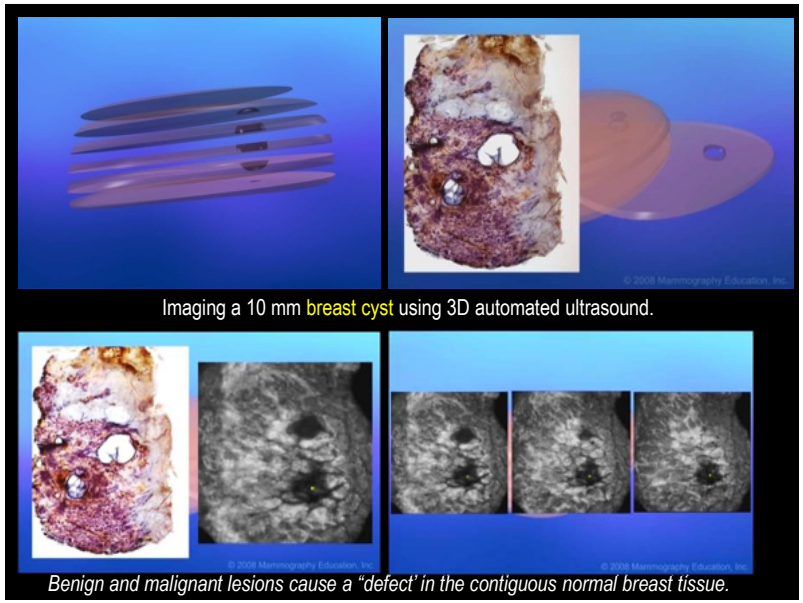
Imaging a 10 mm breast cyst using 3D automated ultrasound.
Benign and malignant lesions cause a "defect' in the contiguous normal breast tissue.

92

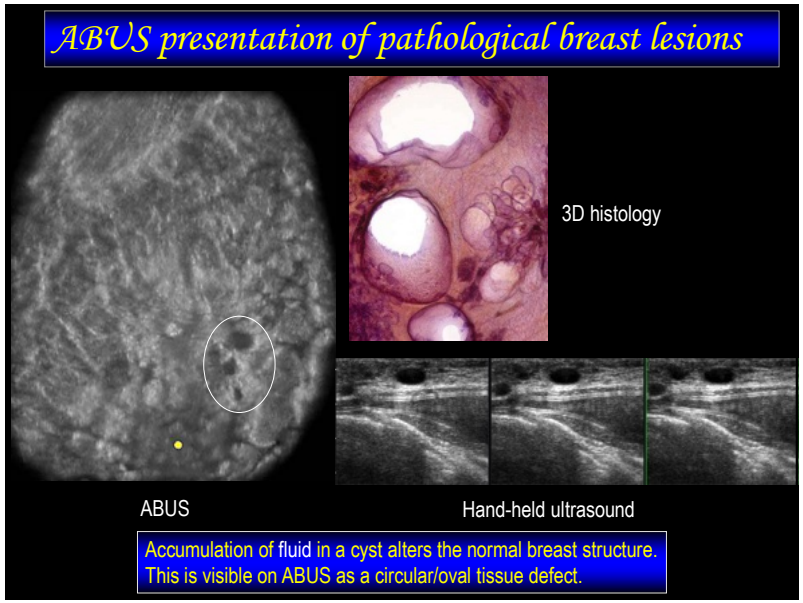
ABUS presentation of pathological breast lesions
3D histology
ABUS
Hand-held ultrasound
Accumulation of fluid in a cyst alters the normal breast structure.
This is visible on ABUS as a circular/oval tissue defect.

93

Åh vilket underbart mustårtebo,
hit ska jag flytta, ja det kan du tro!

94

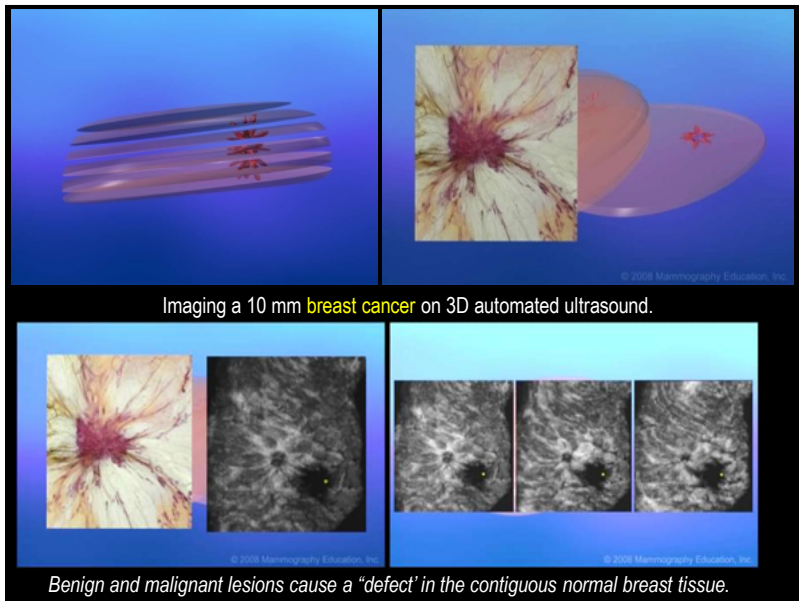
Imaging a 10 mm breast cancer on 3D automated ultrasound.
Benign and malignant lesions cause a "defect' in the contiguous normal breast tissue.

95

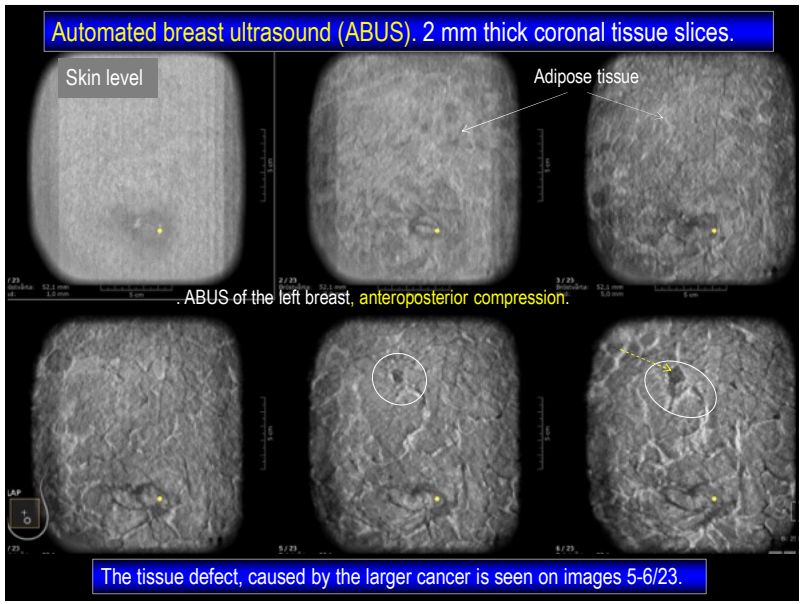
Automated breast ultrasound (ABUS). 2 mm thick coronal tissue slices.
Skin level
Adipose tissue
. ABUS of the left breast, anteroposterior compression.
The tissue defect, caused by the larger cancer is seen on images 5-6/23.

96

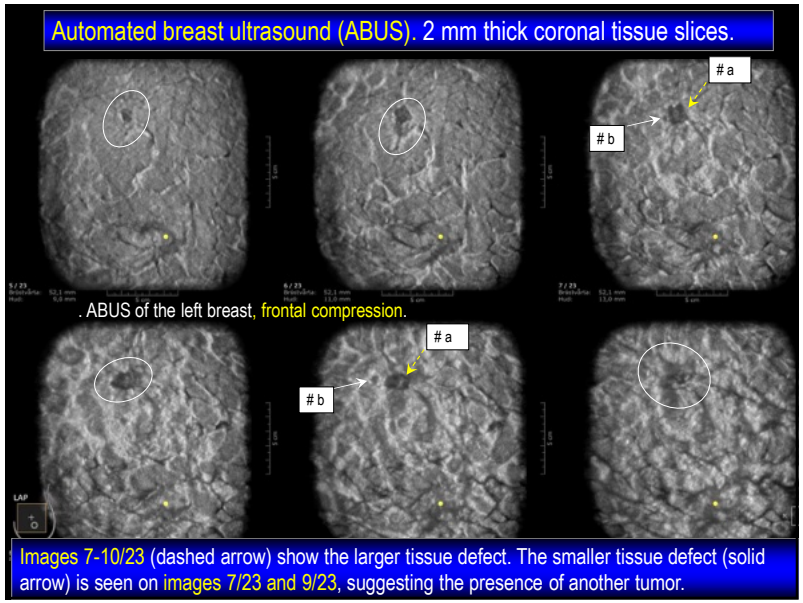
Automated breast ultrasound (ABUS). 2 mm thick coronal tissue slices.
a
b
. ABUS of the left breast, frontal compression.
a
b
Images 7-10/23 (dashed arrow) show the larger tissue defect. The smaller tissue defect (solid arrow) is seen on images 7/23 and 9/23, suggesting the presence of another tumor.

97

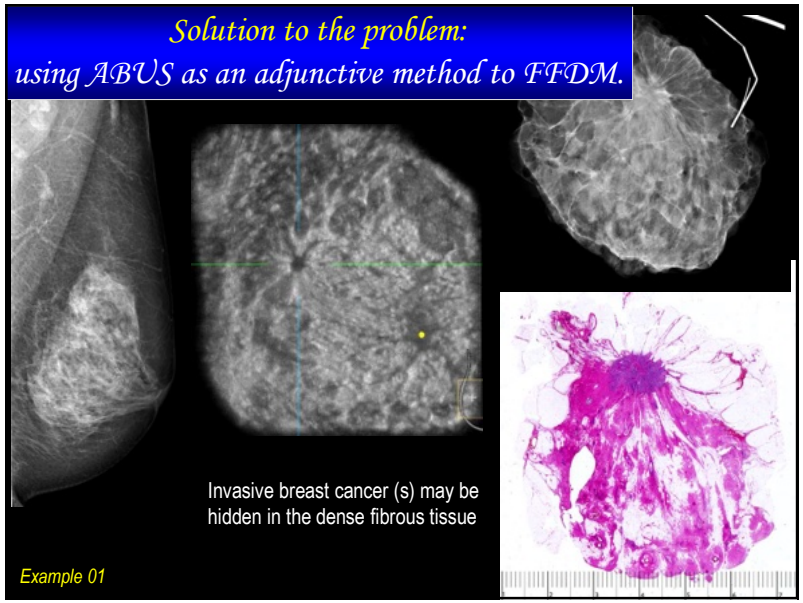
Solution to the problem:
using ABUS as an adjunctive method to FFDM.
Invasive breast cancer (s) may be hidden in the dense fibrous tissue
Example 01

98

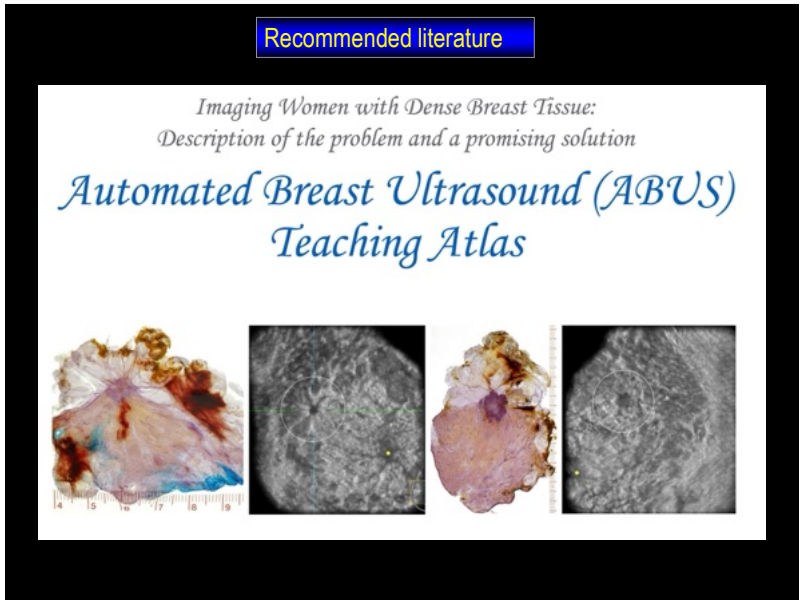
Recommended literature
Imaging Women with Dense Breast Tissue:
Description of the problem and a promising solution
Automated Breast Ultrasound (ABUS)
Teaching Atlas

99

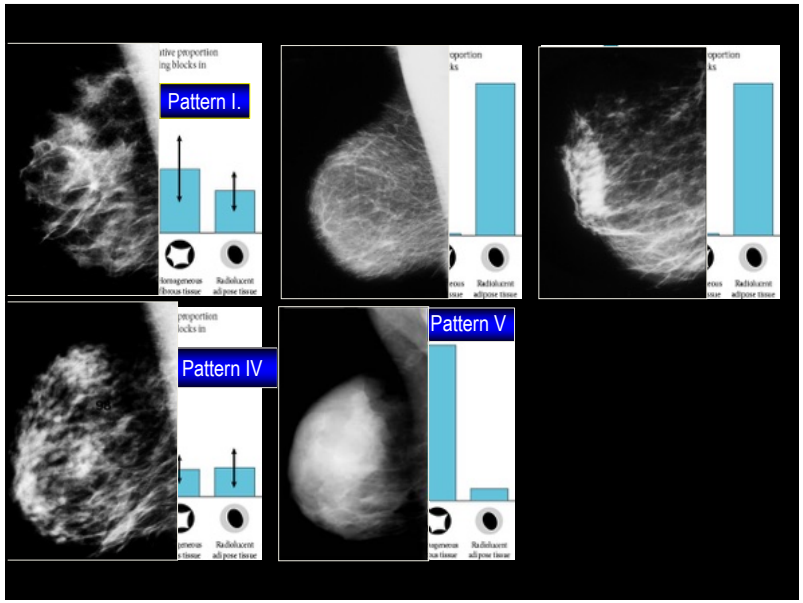
Pattern I.
Pattern IV
Pattern V

100

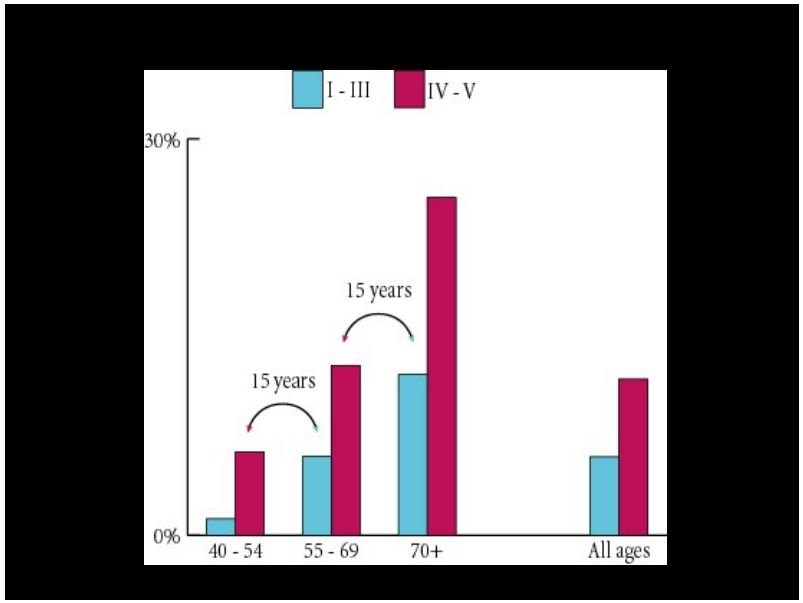

101

Recommended literature

Breast Cancer: The Art and Science of Early Detection with Mammography

www.thieme.com

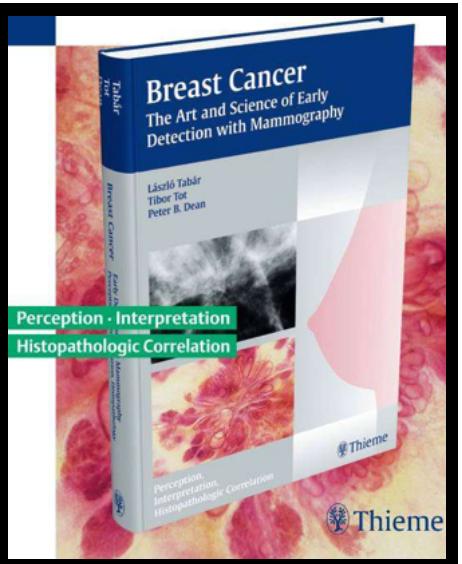

102

Where to look?

- *To detect AABs*
- *To detect DABs*
- *To detect diffusely infiltrating breast malignancy of mesenchymal origin*

103

Distribution of 1-14 mm breast cancers (# 981) according to location in the breast

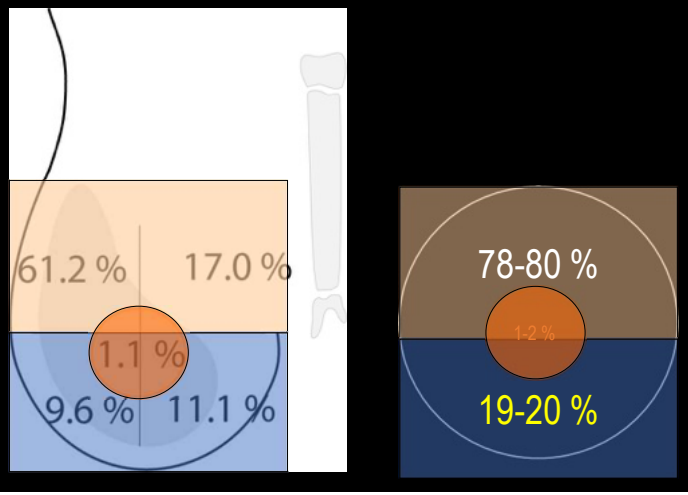

104

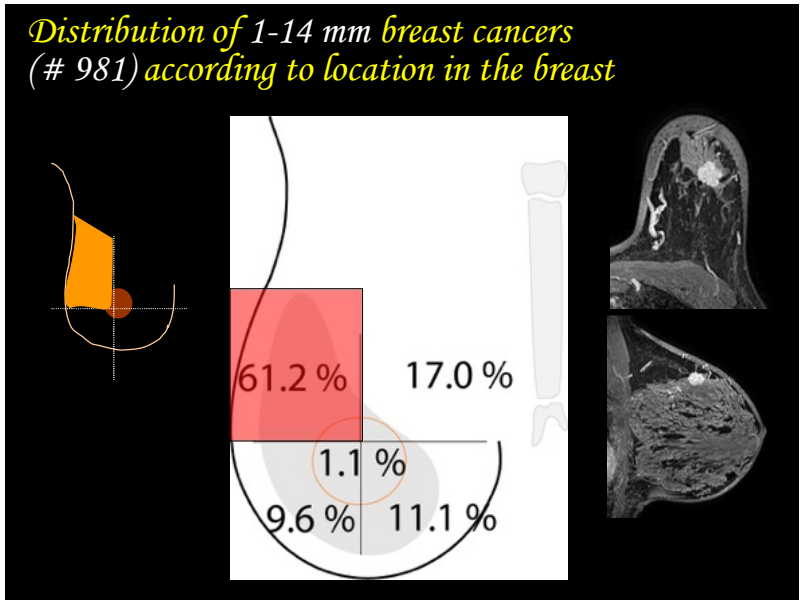

105

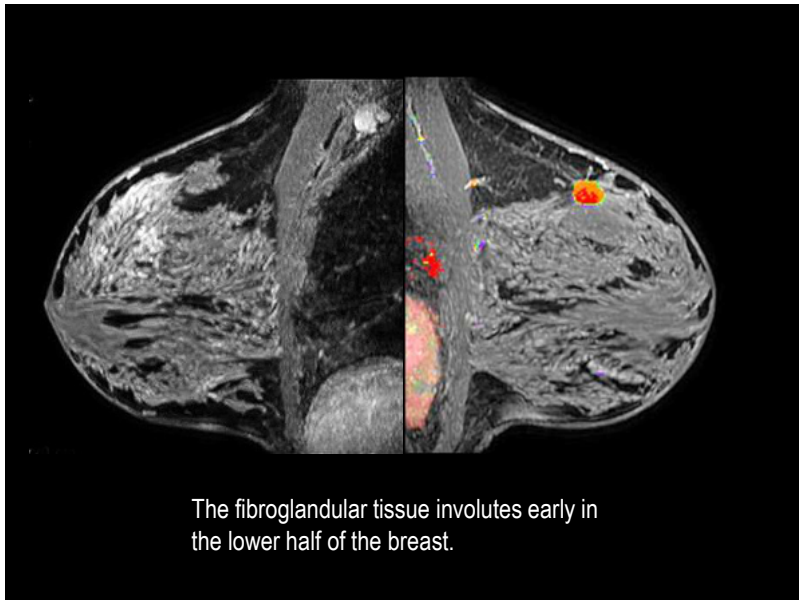

106

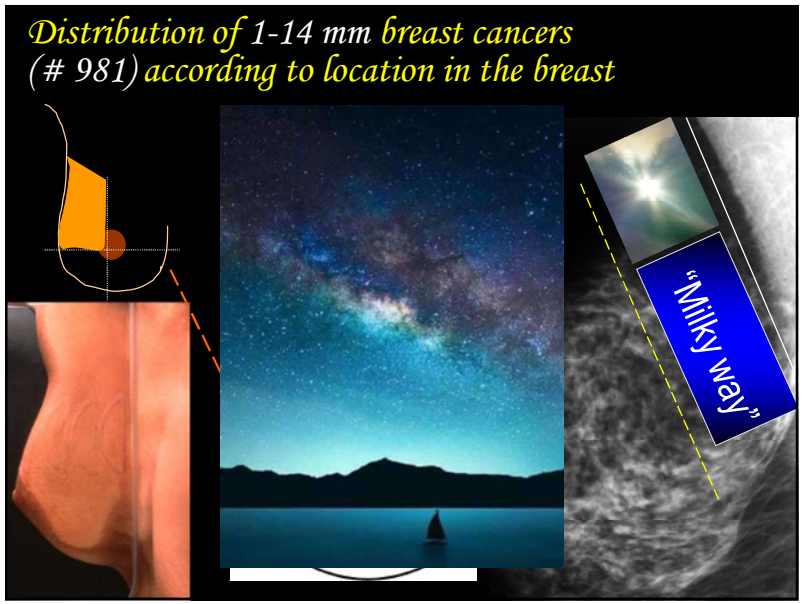

107

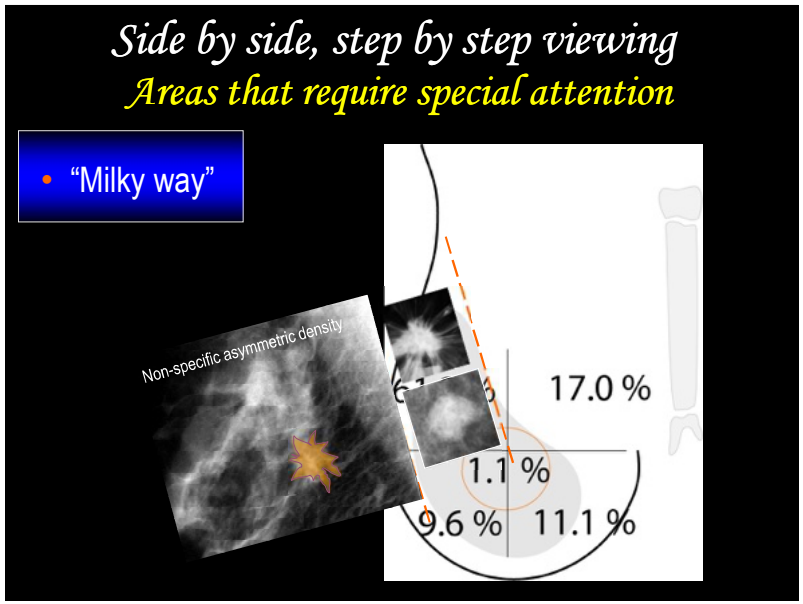

108

Side by side, step by step viewing
Areas that require special attention

Locations with high frequency of abnormal lesions ("forbidden areas"):

- "Milky way"
- The medial half of the breast

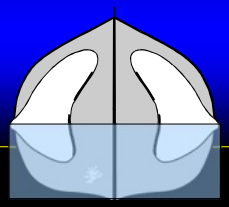

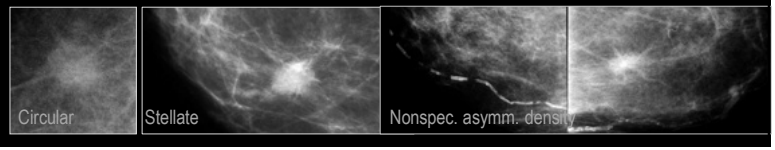

109

Side by side, step by step viewing
Areas that require special attention

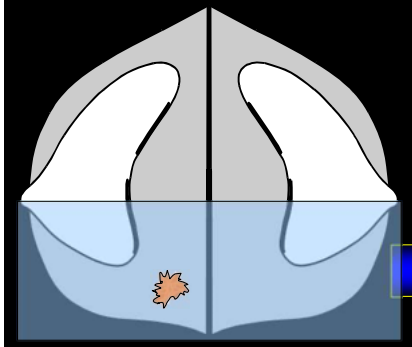

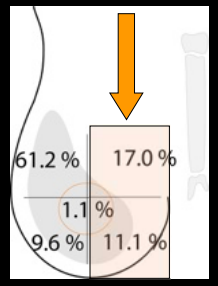

The medial half of the breast

110

Side by side, step by step viewing
Areas that require special attention

Locations with high frequency of abnormal lesions ("forbidden areas"):

- "Milky way"
- The medial half of the breast
- Retroglandular clear space ("no man's land")

111

Side by side, step by step viewing
Areas that require special attention

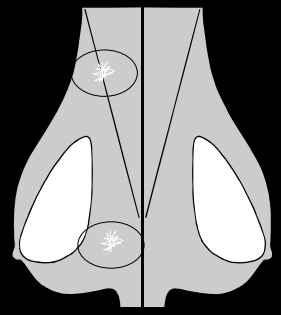

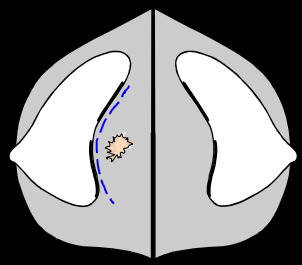

The retroglandular clear space ("no man's land")

112

Side by side, step by step viewing
Areas that require special attention

Locations with high frequency of abnormal lesions ("forbidden areas"):

- "Milky way"
- The medial half of the breast
- Retroglandular clear space ("no man's land")
- The retroareolar area

113

Side by side, step by step viewing
Areas that require special attention

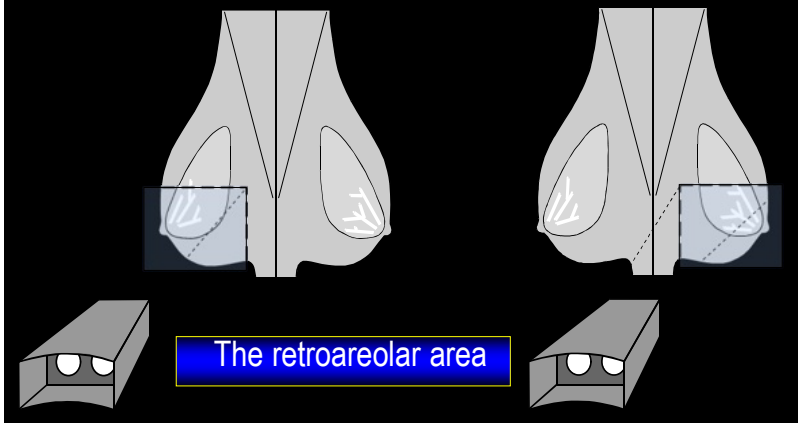

114

Aim of perception
Disruption of the harmonic structure

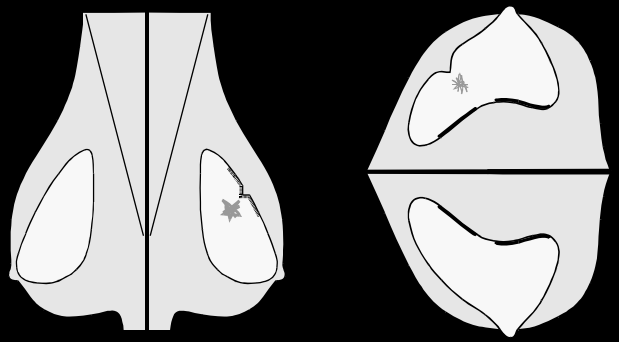

115

Aim of perception
Disruption of the harmonic structure

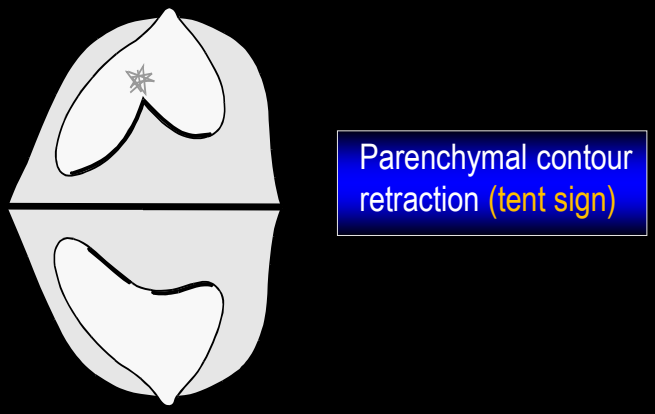

116

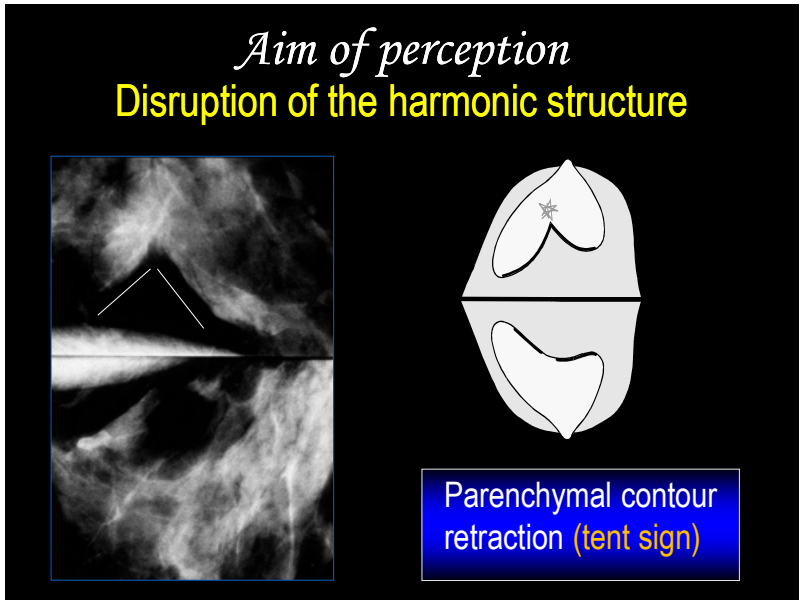

117

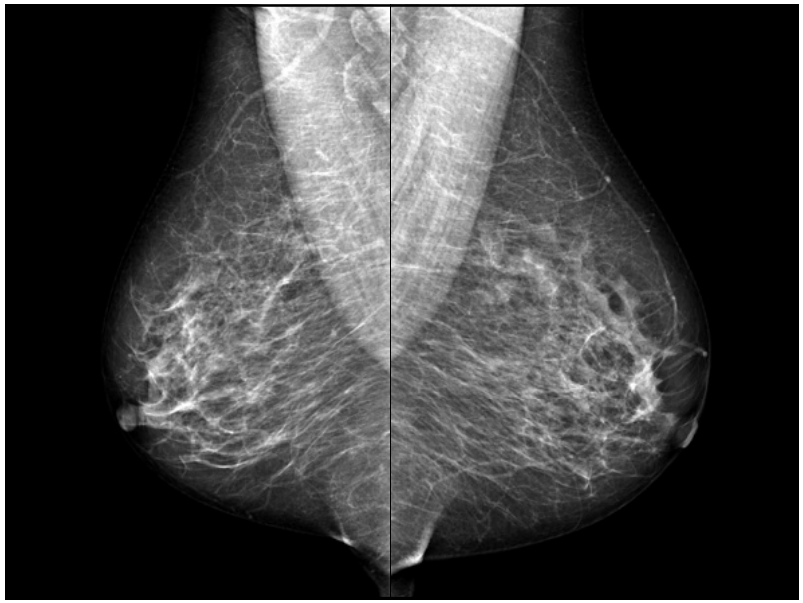

118

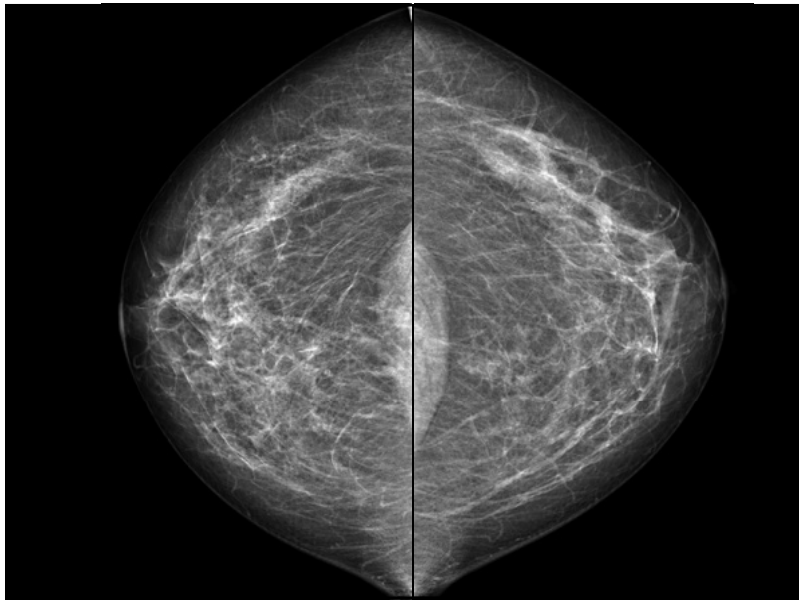

119

120

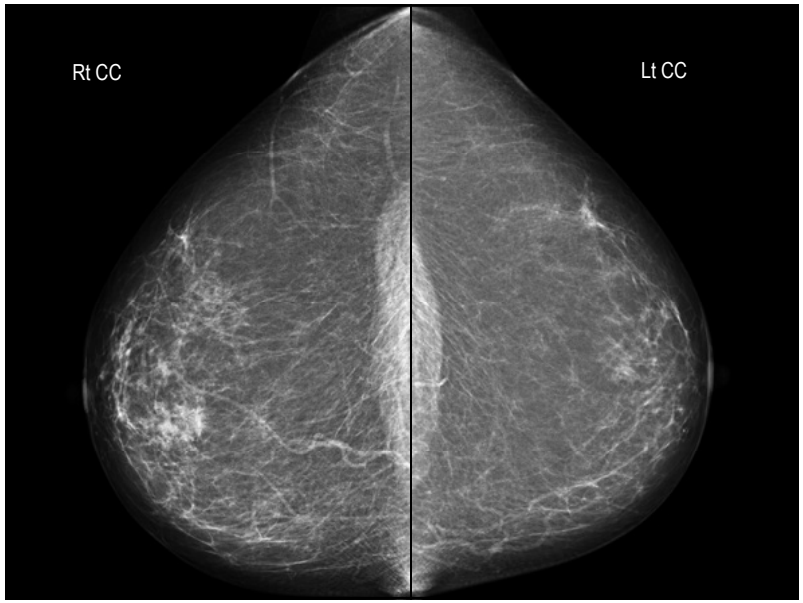

121

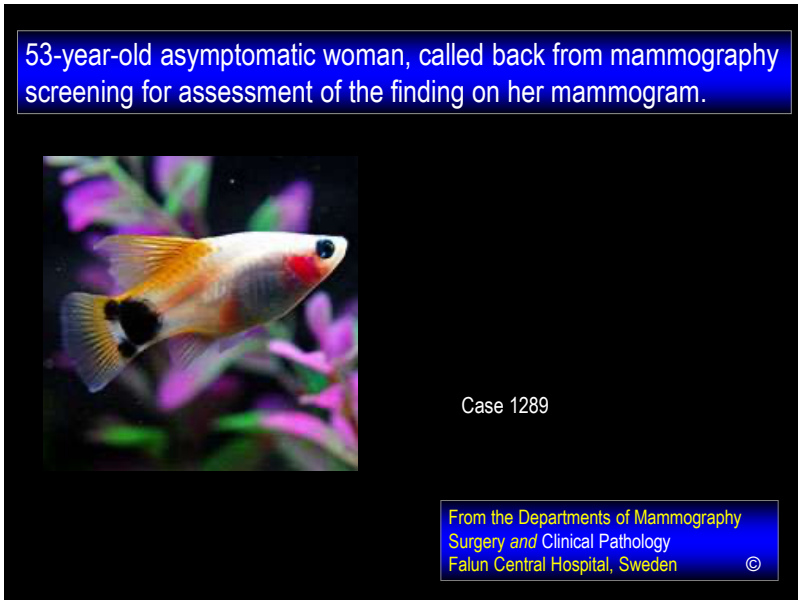

122

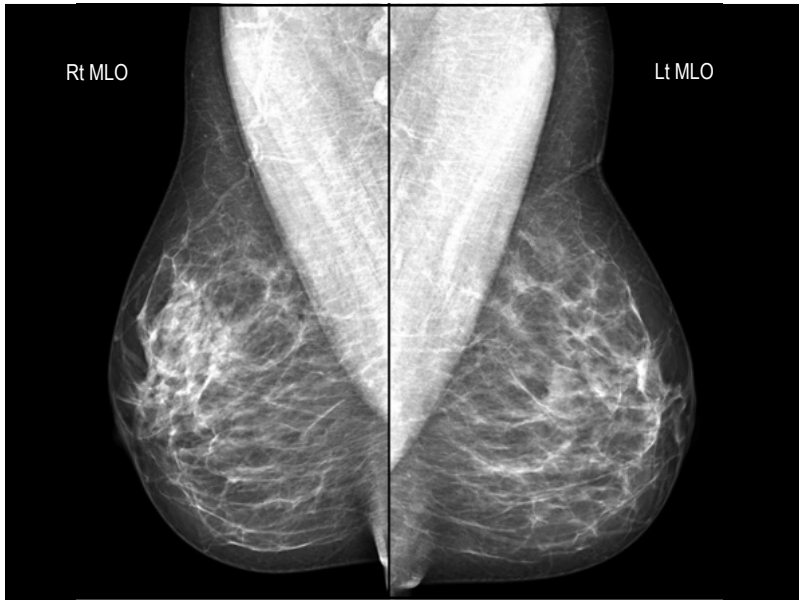

123

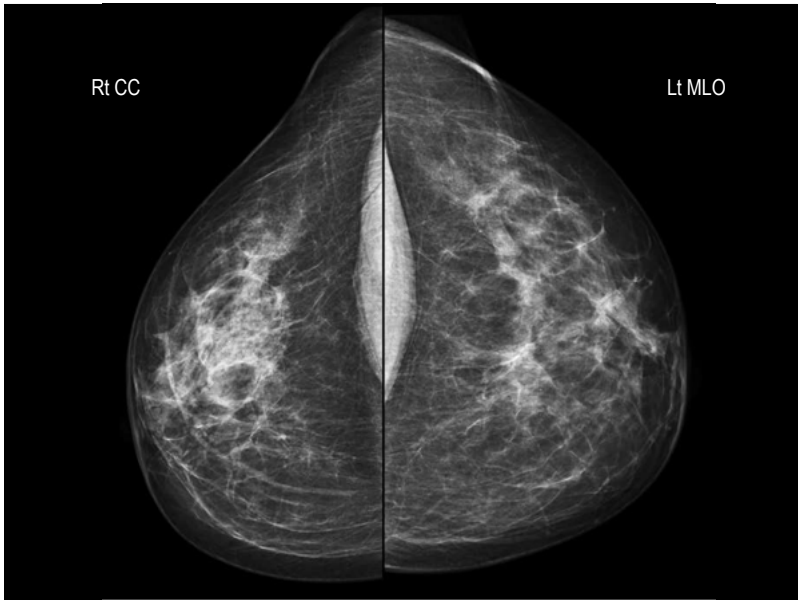

124

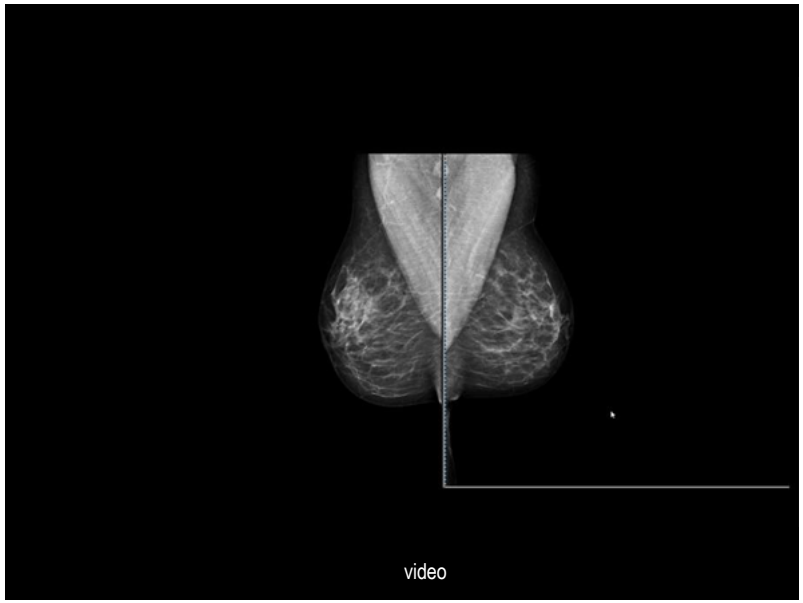

125

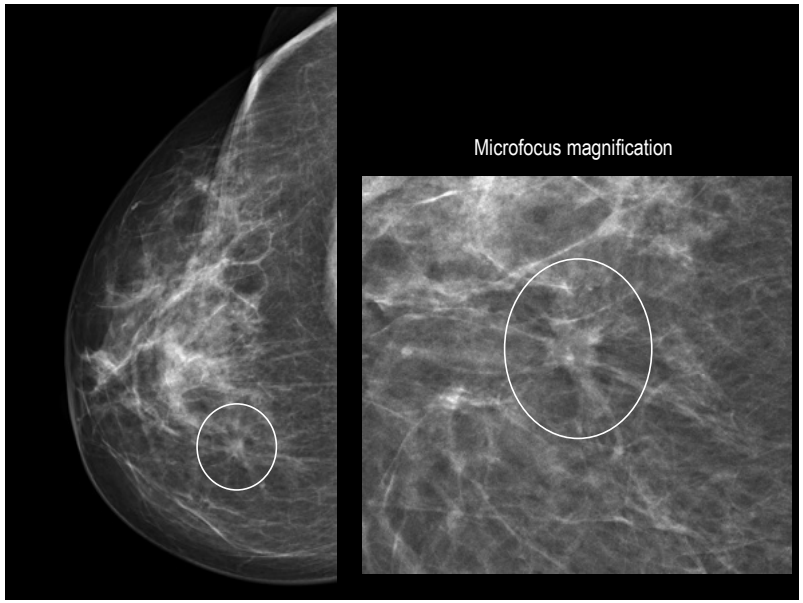

126

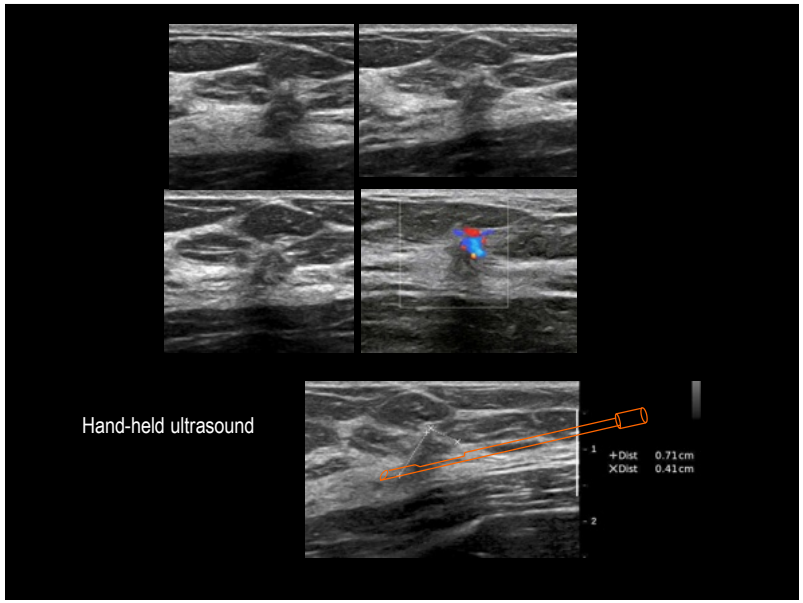

127

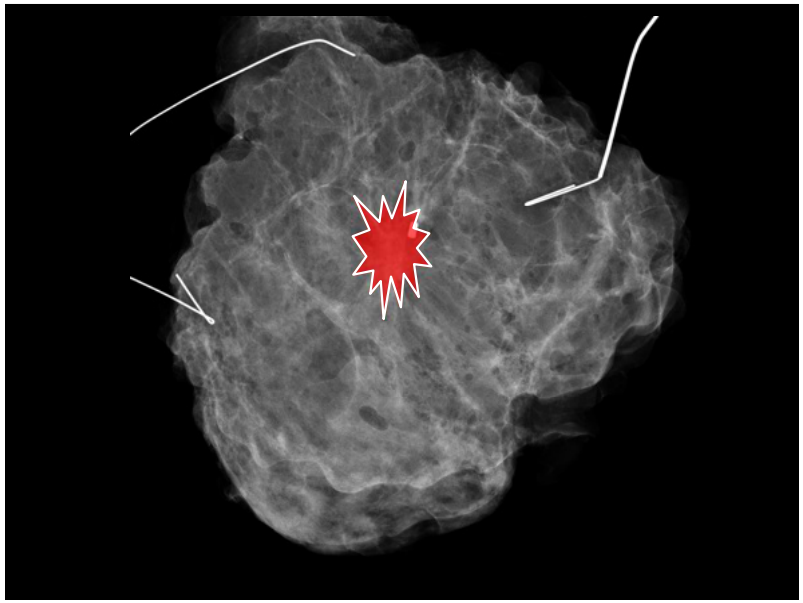

128

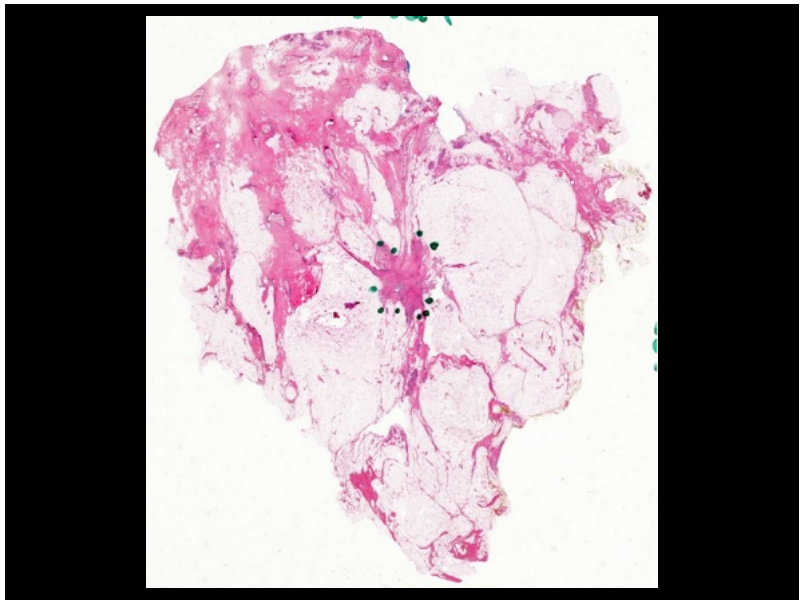

129

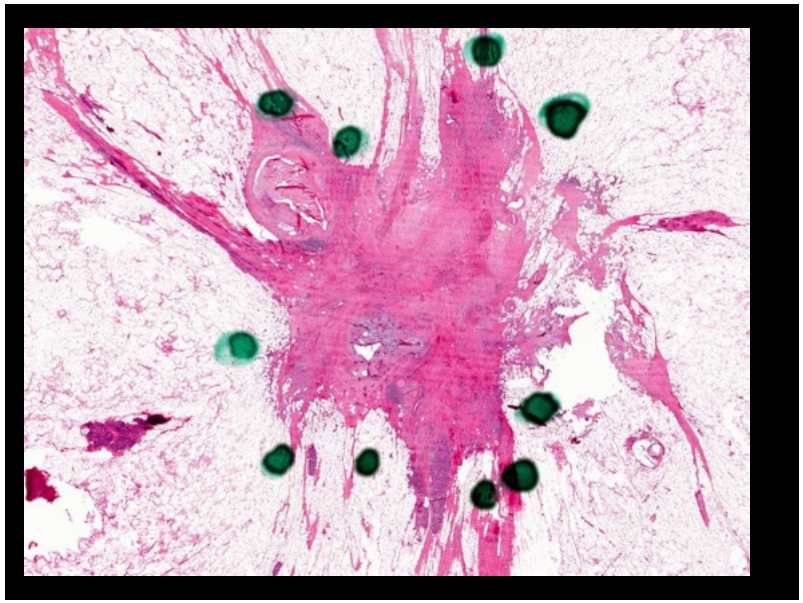

130

Histopathology

12x10 mm solitary invasive intralobular BCMO. pN 0/2

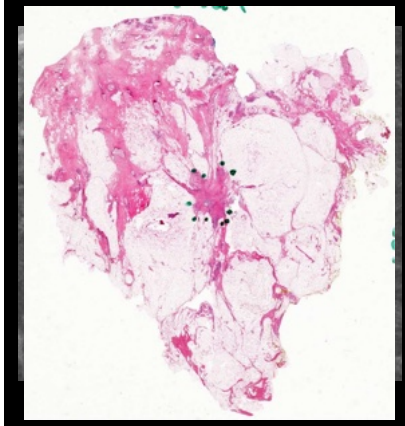

131

Follow-up

Nine years and seven months after diagnosis and treatment, the patient is well with no signs of recurrence.

132

Breast imagers' expectations for help from AI when reading mammograms

I am truly enthused by the potential benefit of AI, since it may bring breast cancer detection at mammography screening to the same high level everywhere.

133

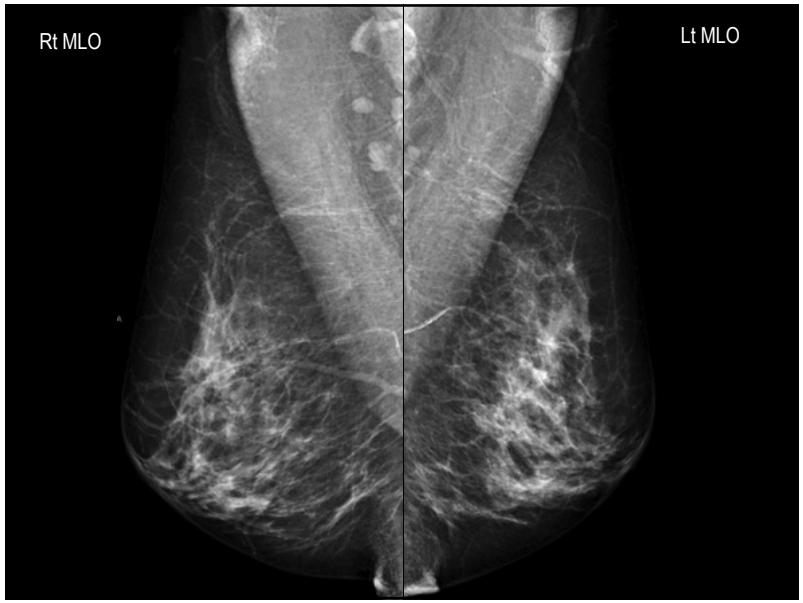

134

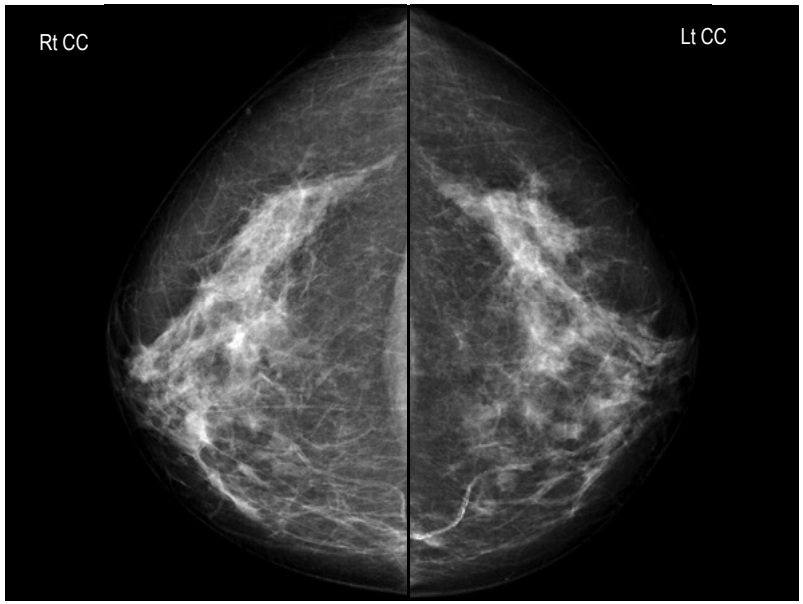

135

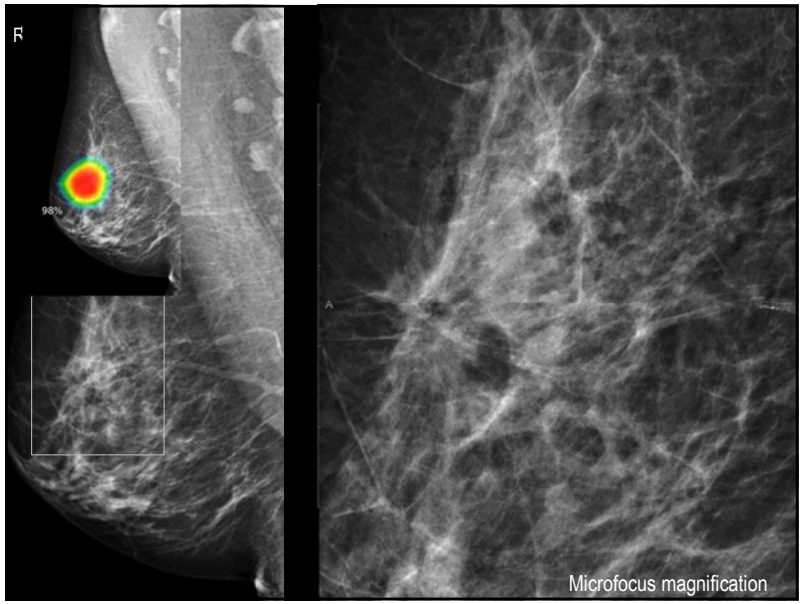

136

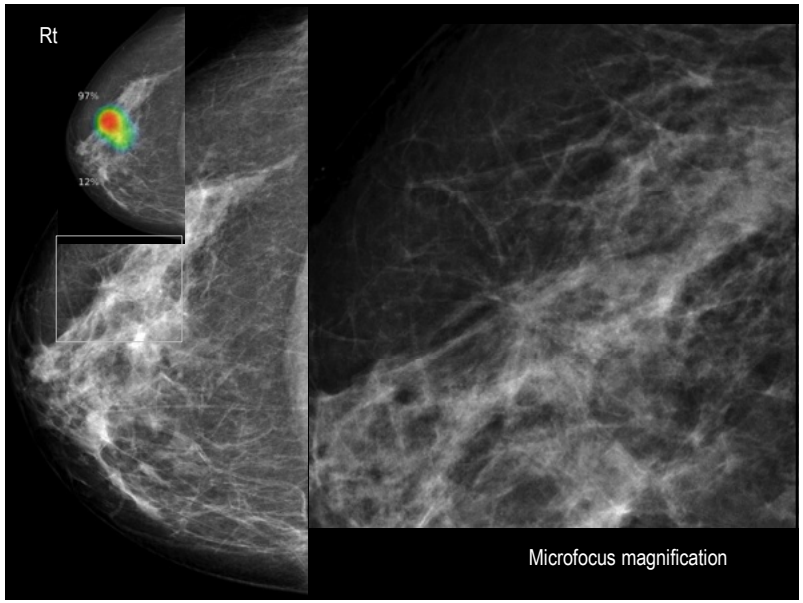

137

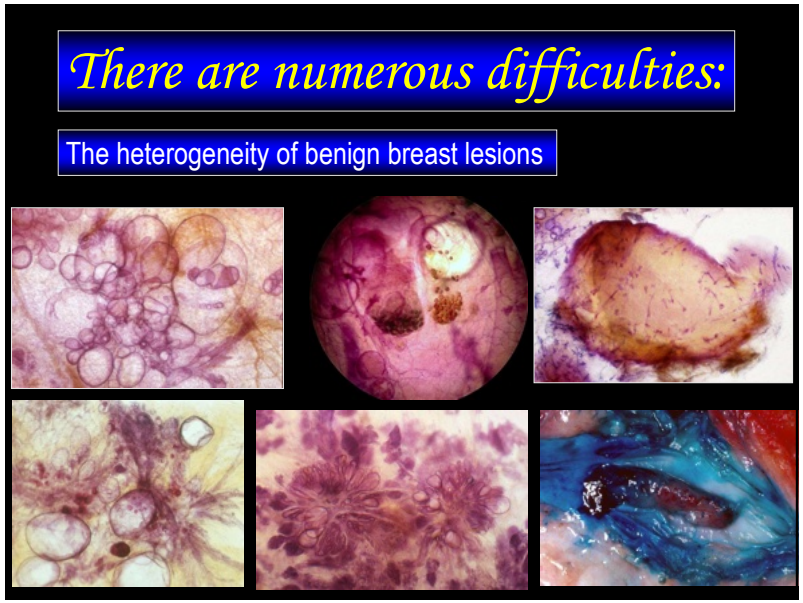

138

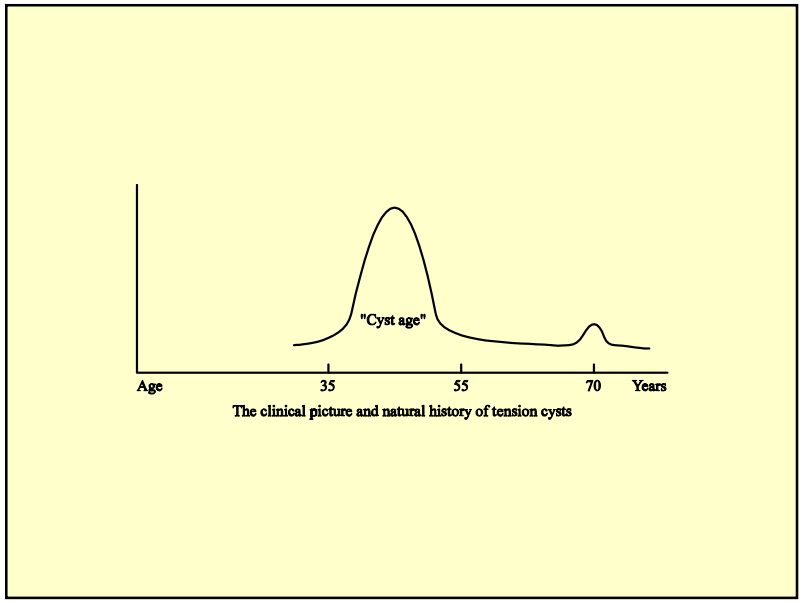

139

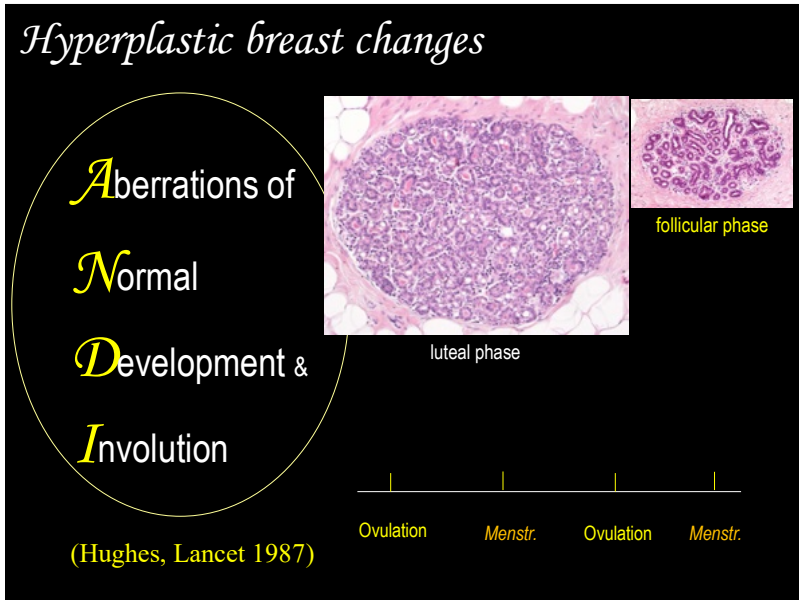

140

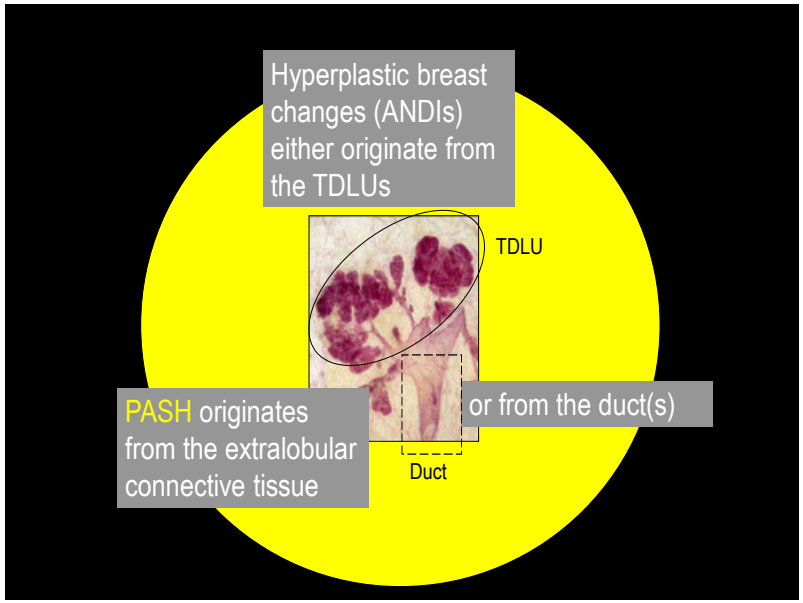

141

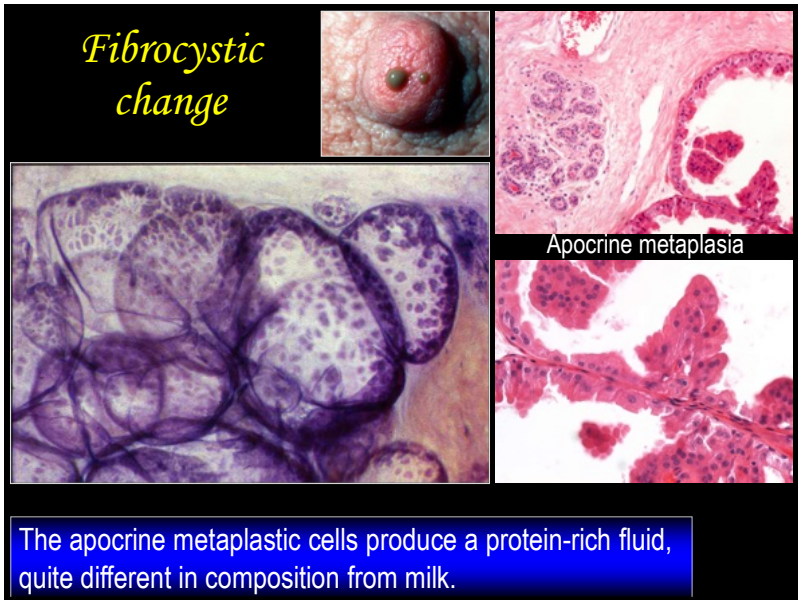

142

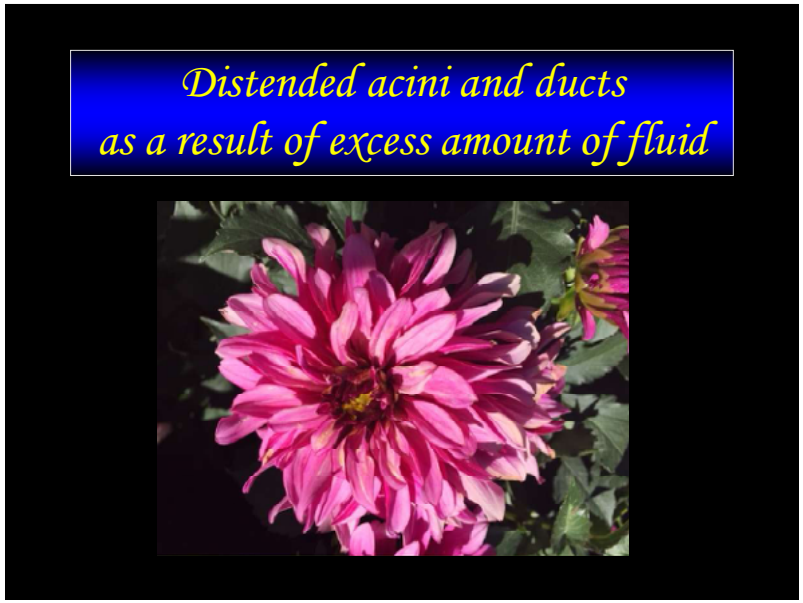

143

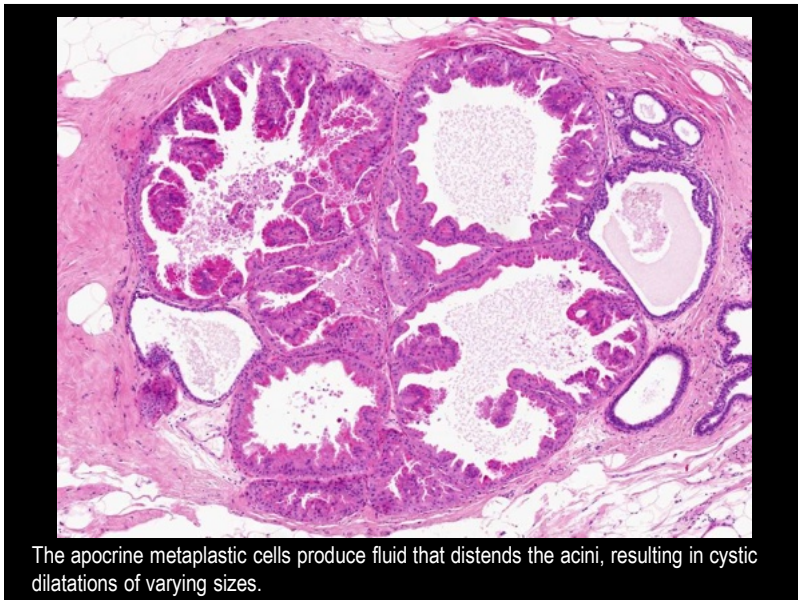

144

Aberrations of Normal Development and Involution ("ANDI")

1) Excess amount of fluid produced
   a) Fibrocystic change, cysts

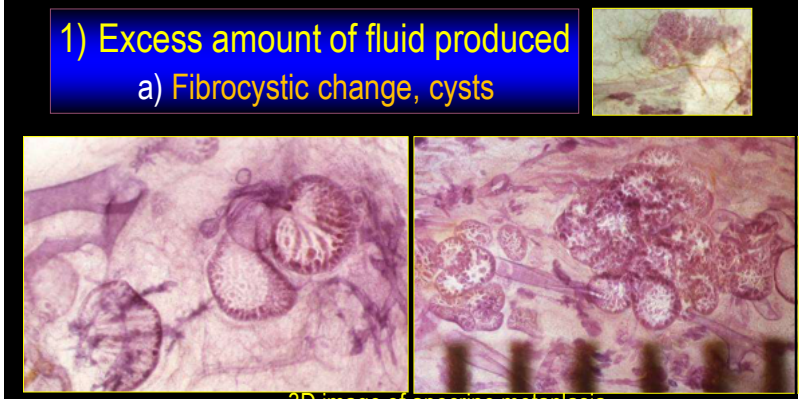

3D image of apocrine metaplasia

145

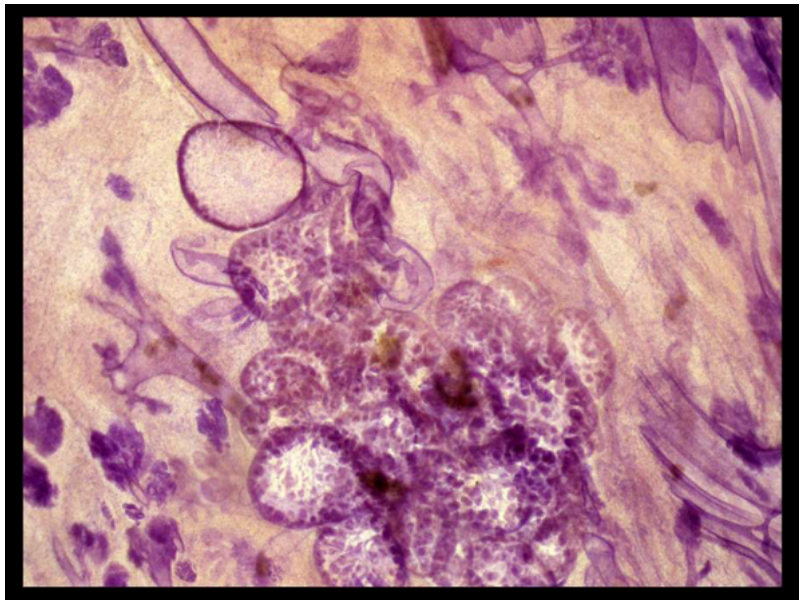

146

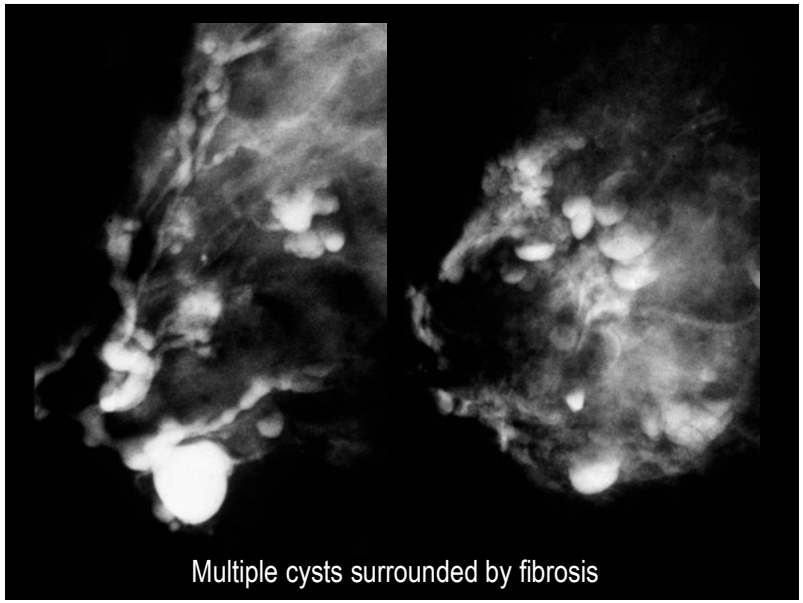

Multiple cysts surrounded by fibrosis

147

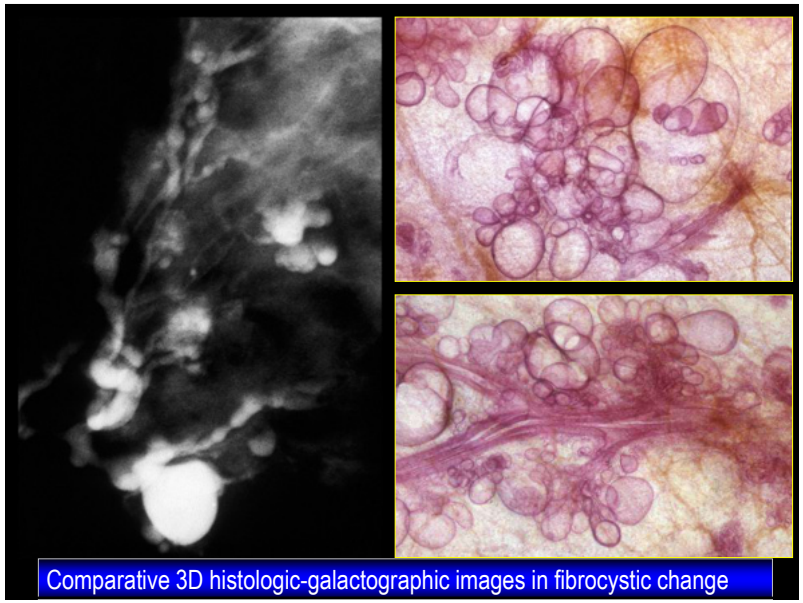

Comparative 3D histologic-galactographic images in fibrocystic change

148

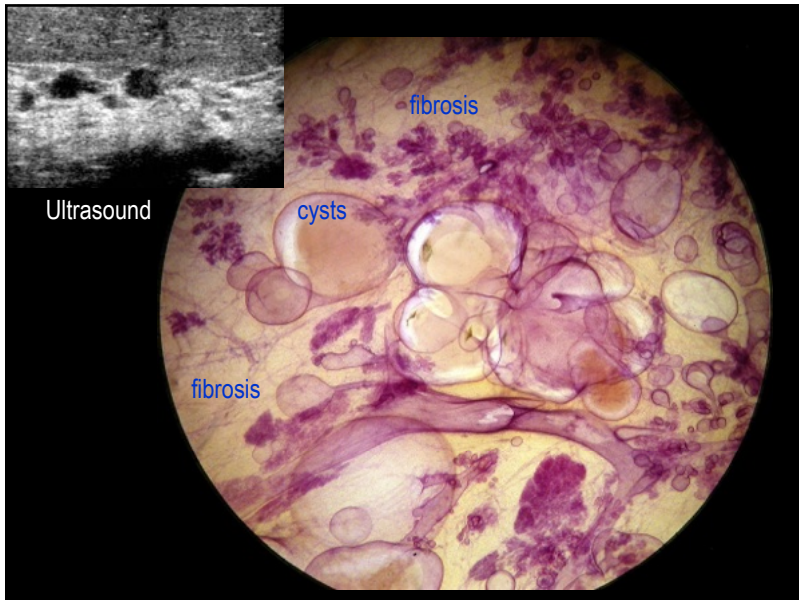

149

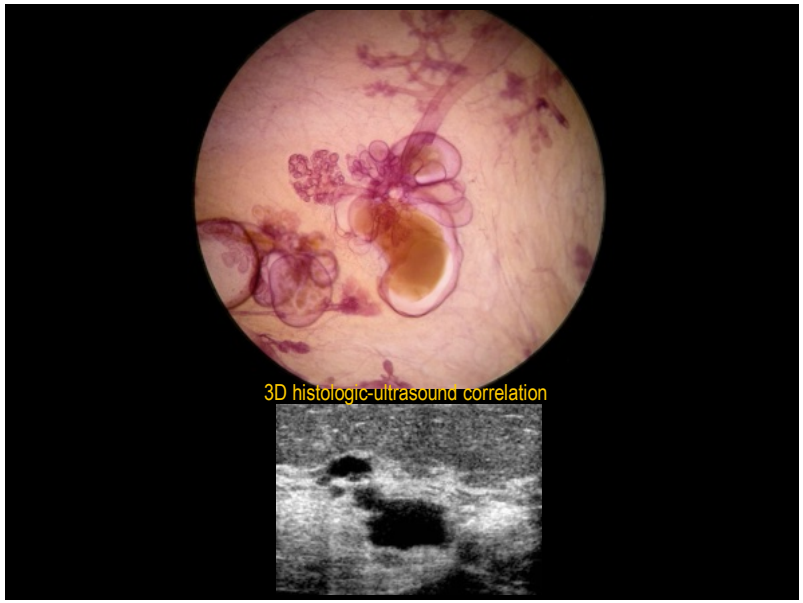

150

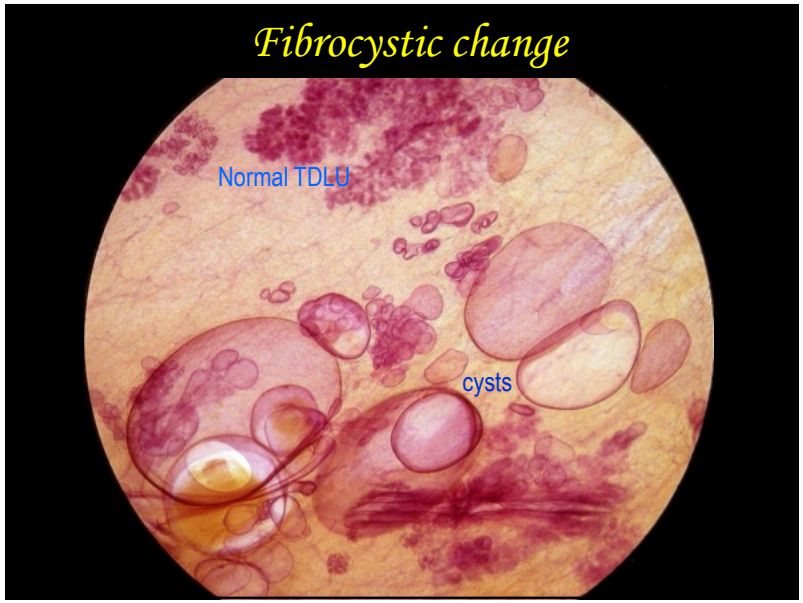

151

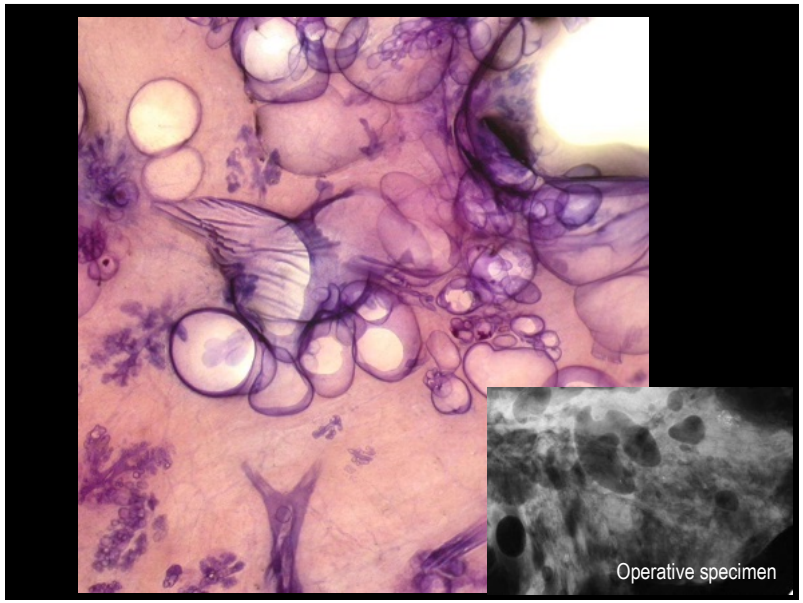

152

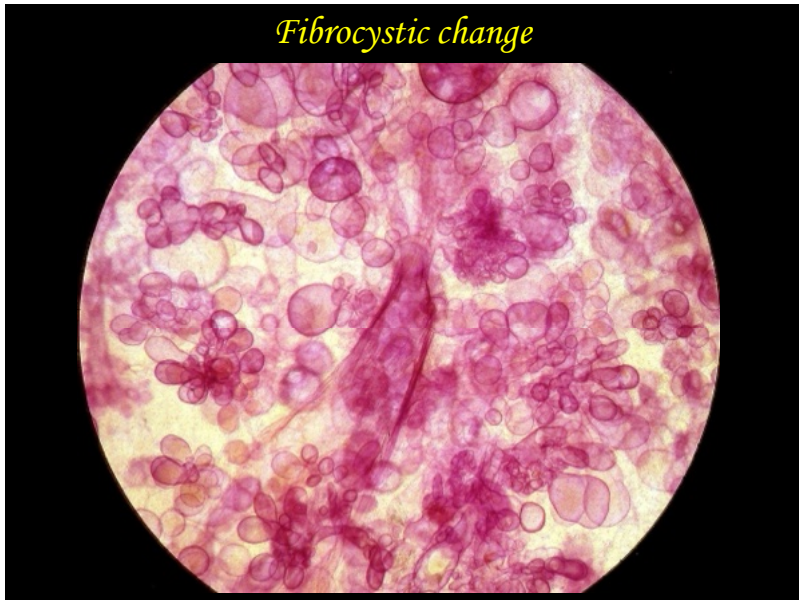

153

154

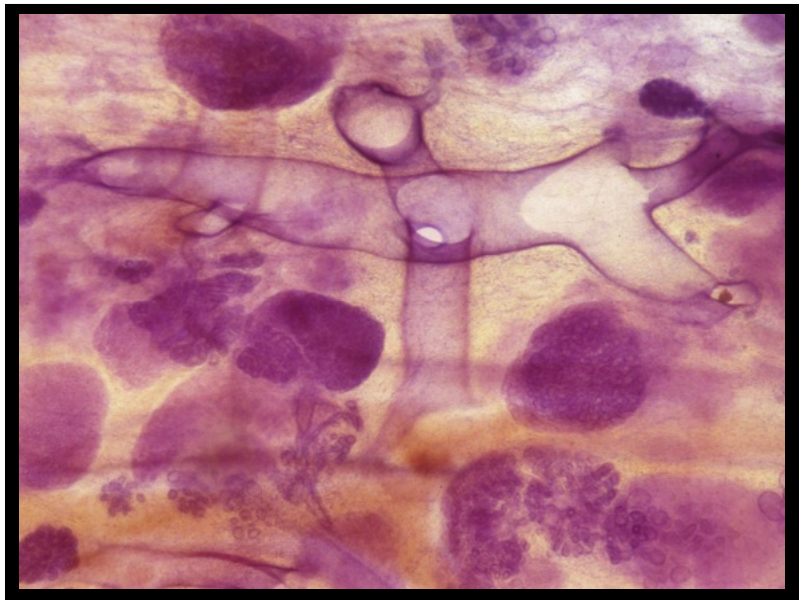

155

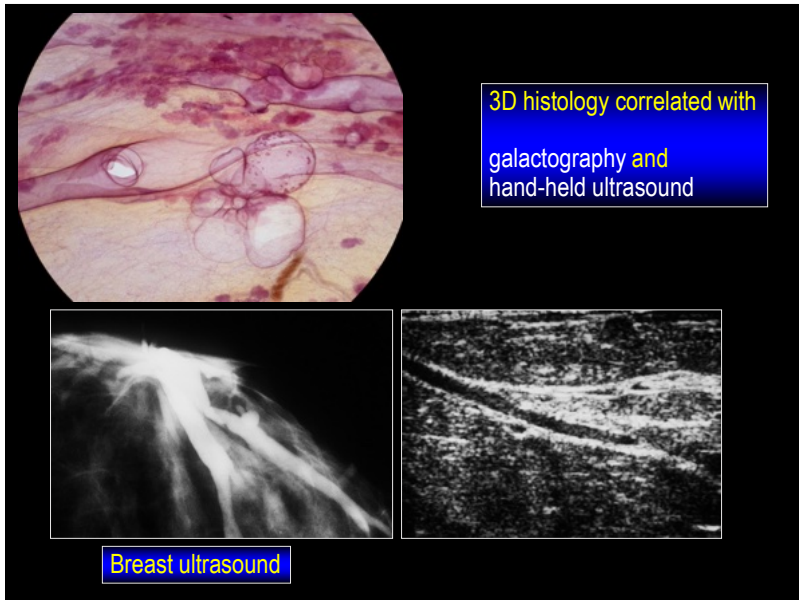

156

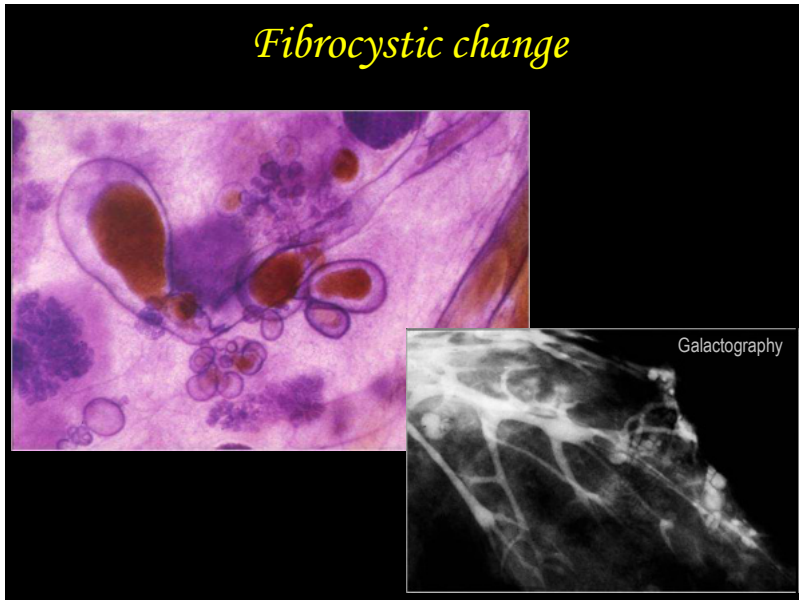

157

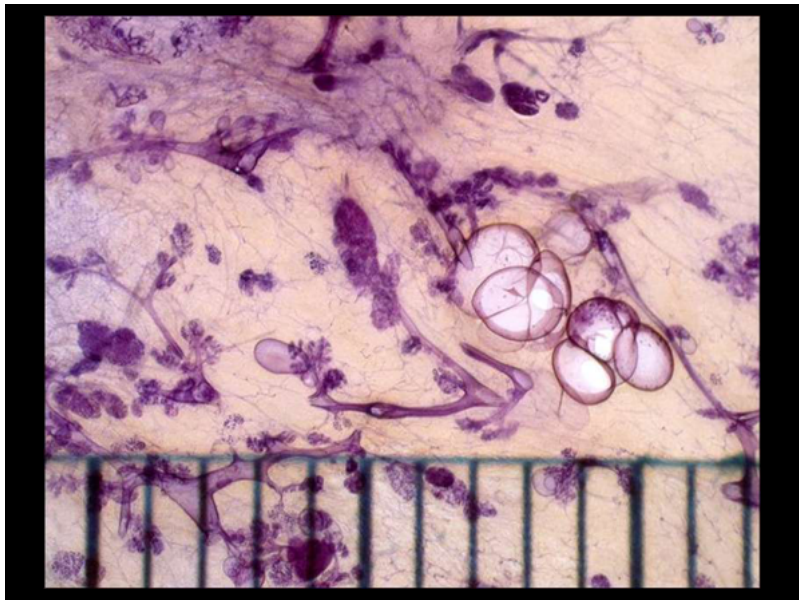

158

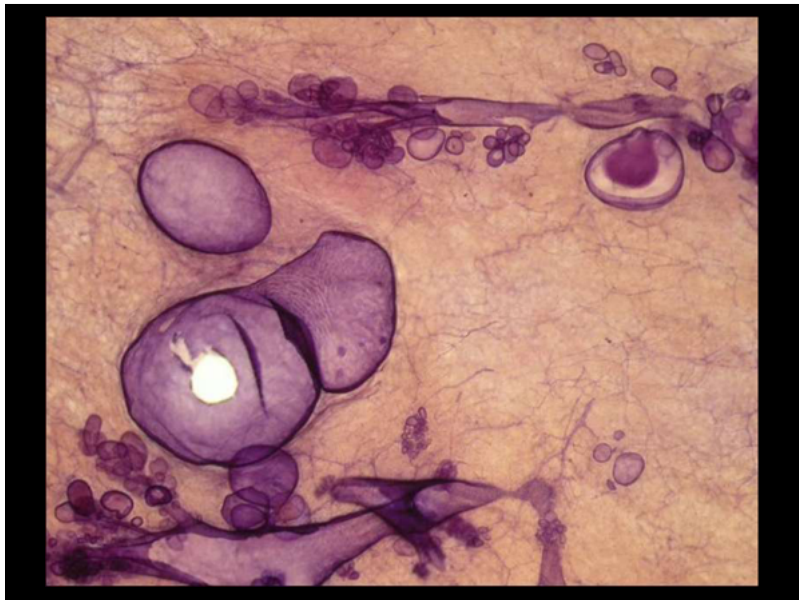

159

160

Demonstration of

- Normal ducts
- Dilated, fluid-filled ducts, ductectasia
- Cancer of ductal origin (DAB)

161

12-18 lobes

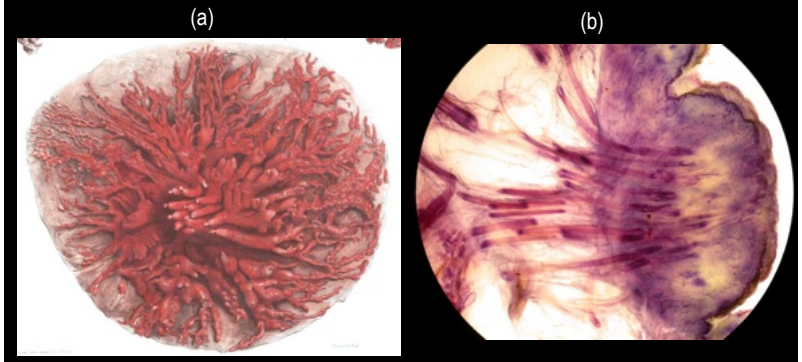

The 12-18 breast lobes have their own individual openings on the nipple surface. Preparation of Cooper (a) and thick section histology image in cross section showing the ducts within and behind the nipple (b).

162

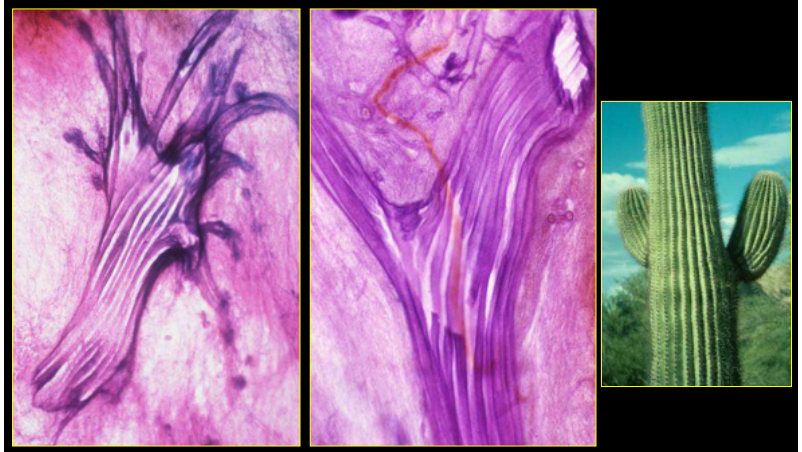

The major ducts are pleated . There is a slight twist on the pleated pattern.

163

The pleats follow the twists in the major ducts.

164

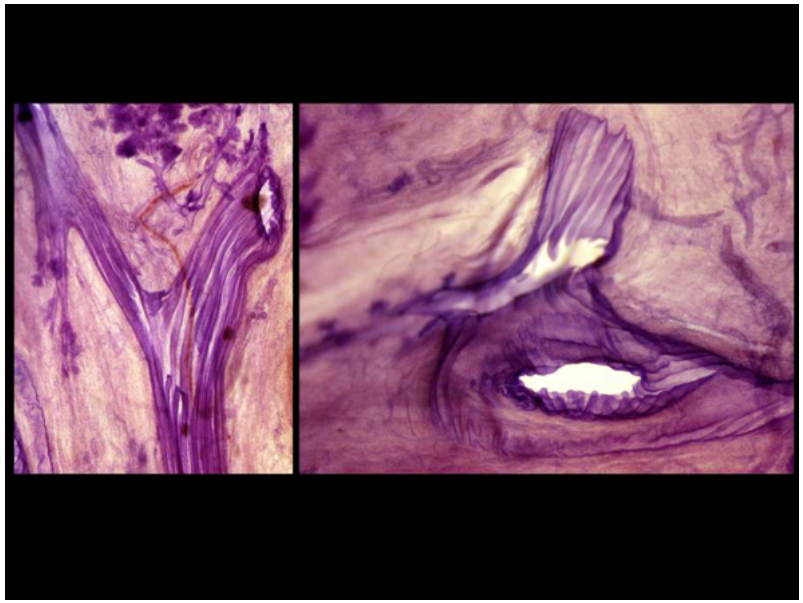

165

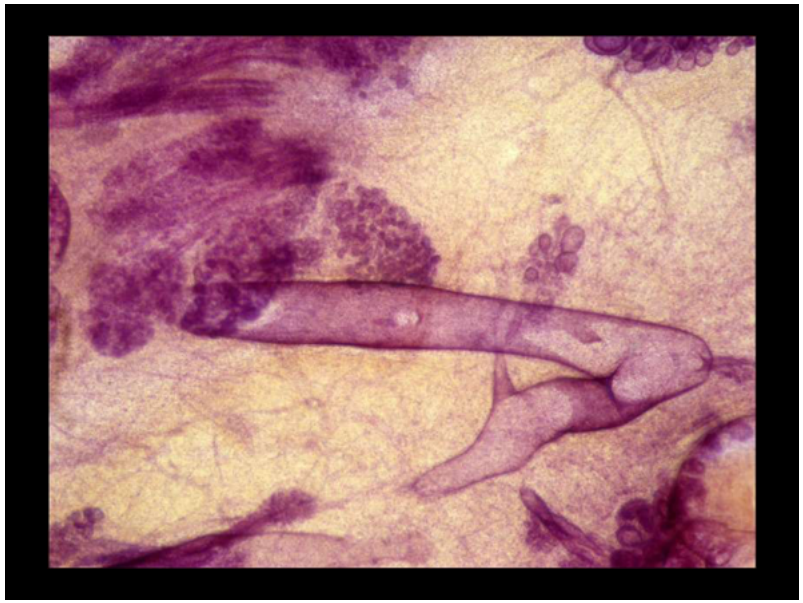

166

167

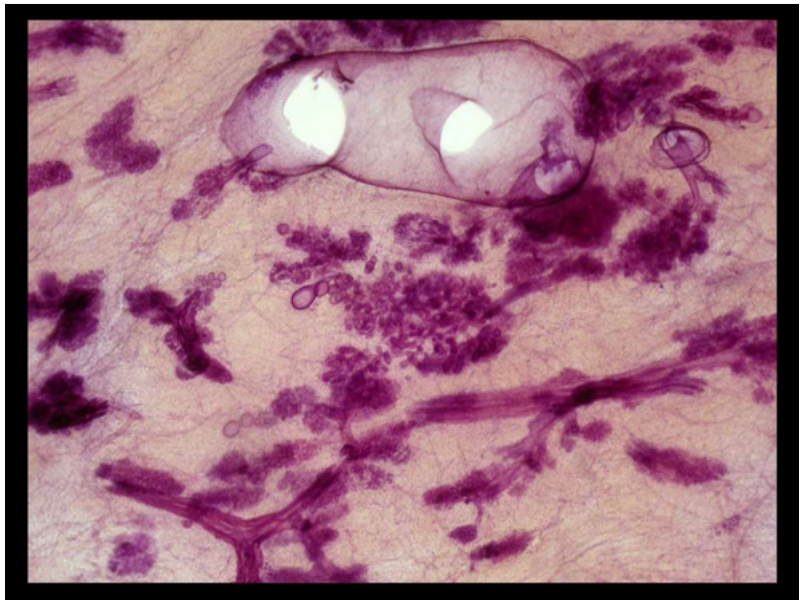

168

169

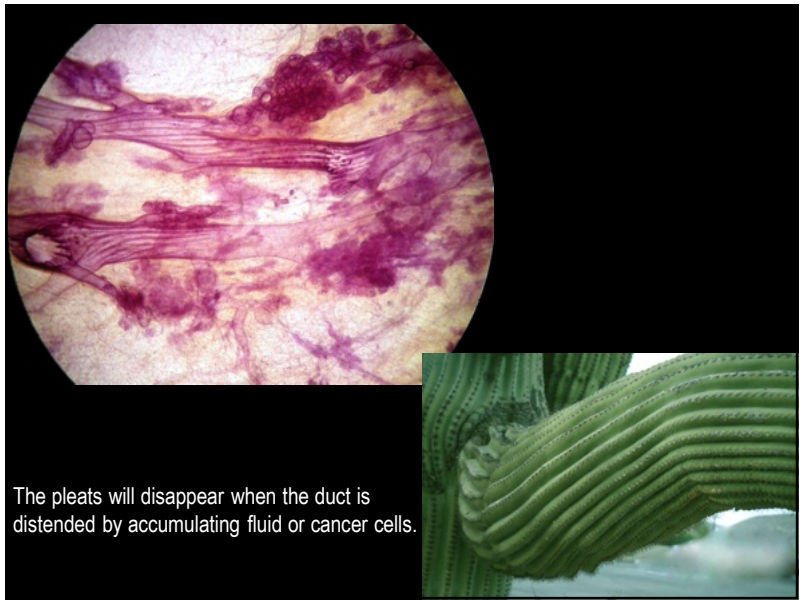

170

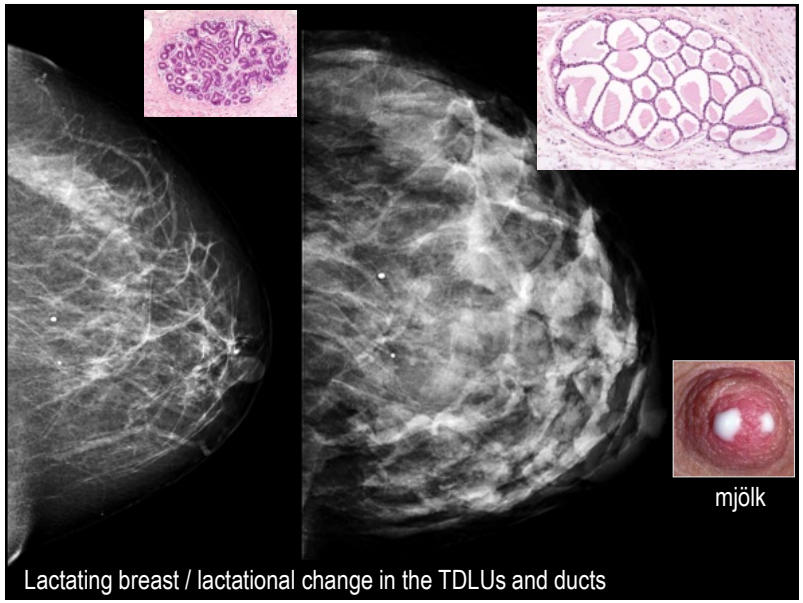

171

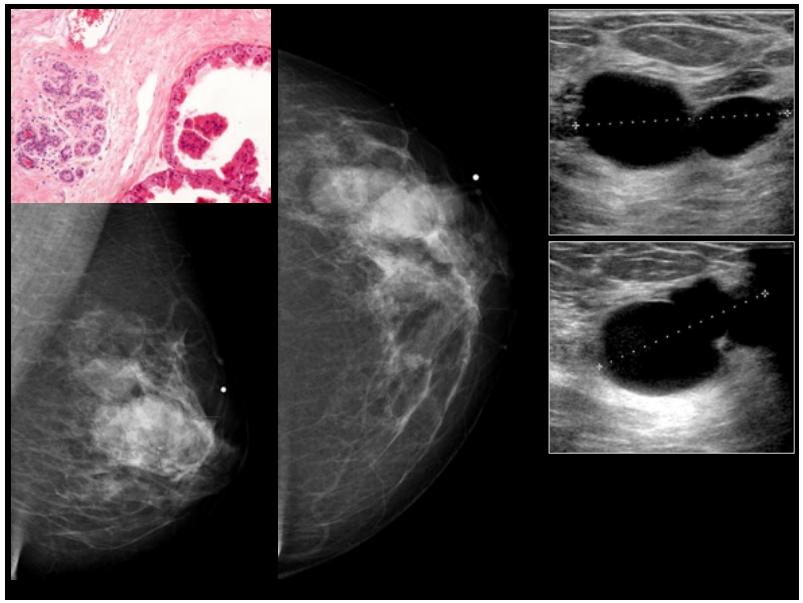

172

173

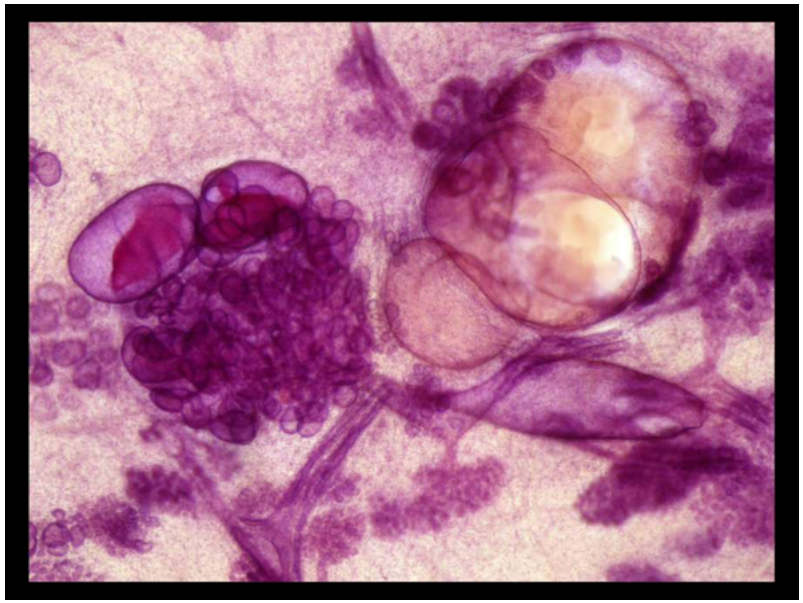

174

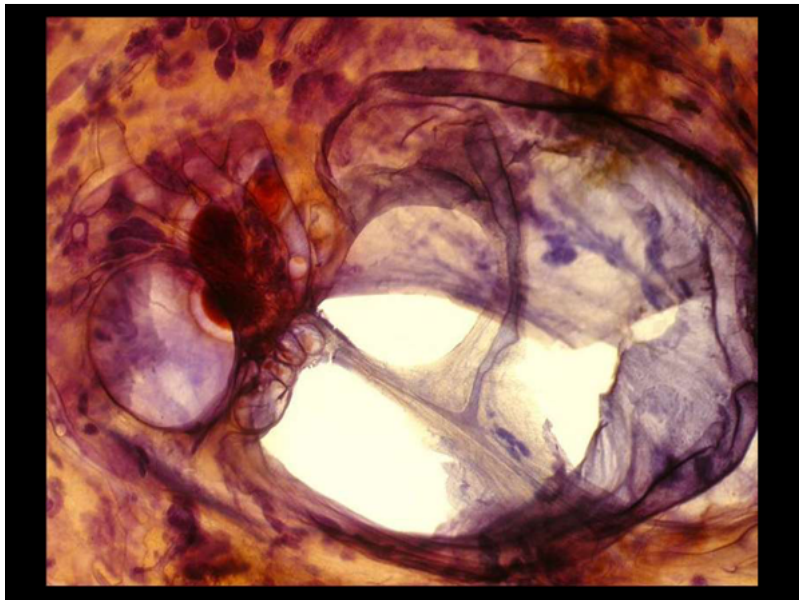

175

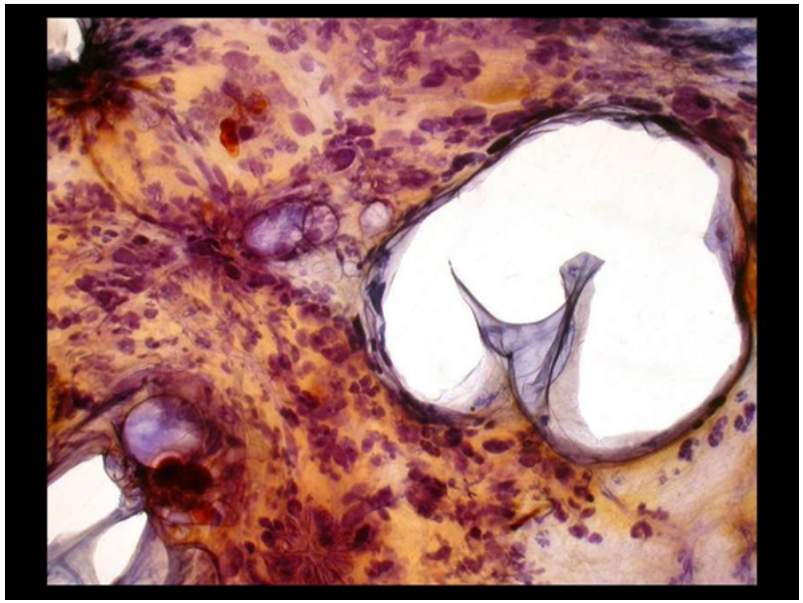

176

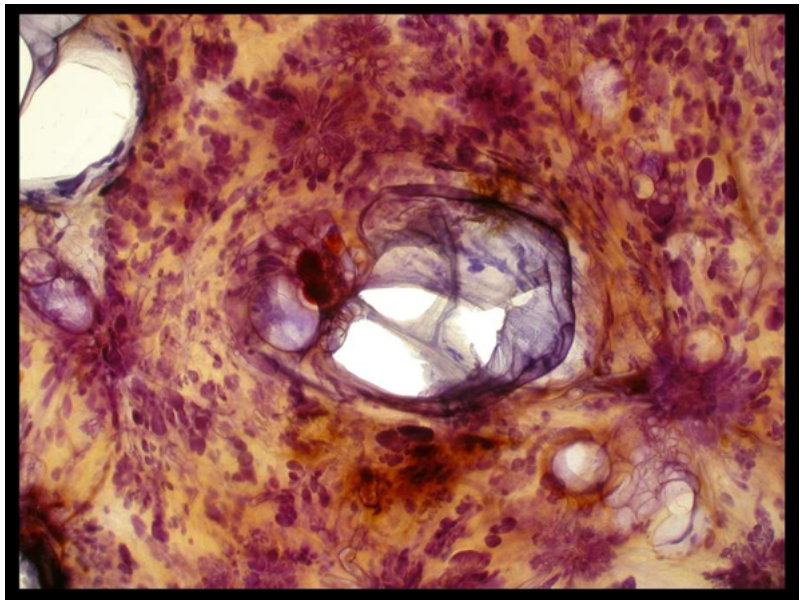

177

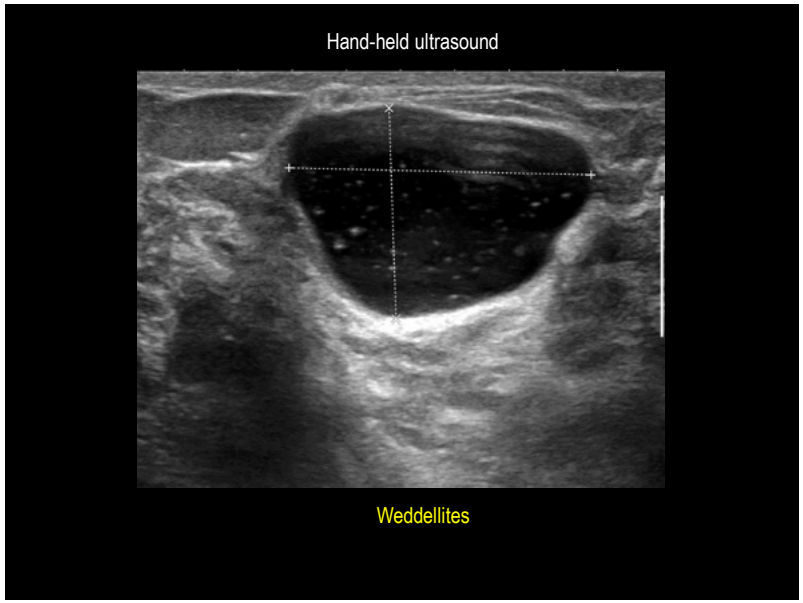

178

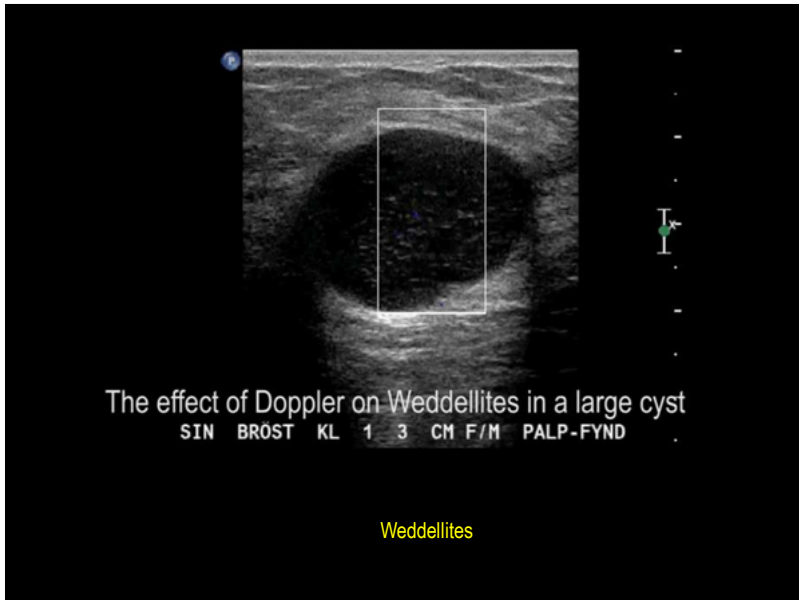

179

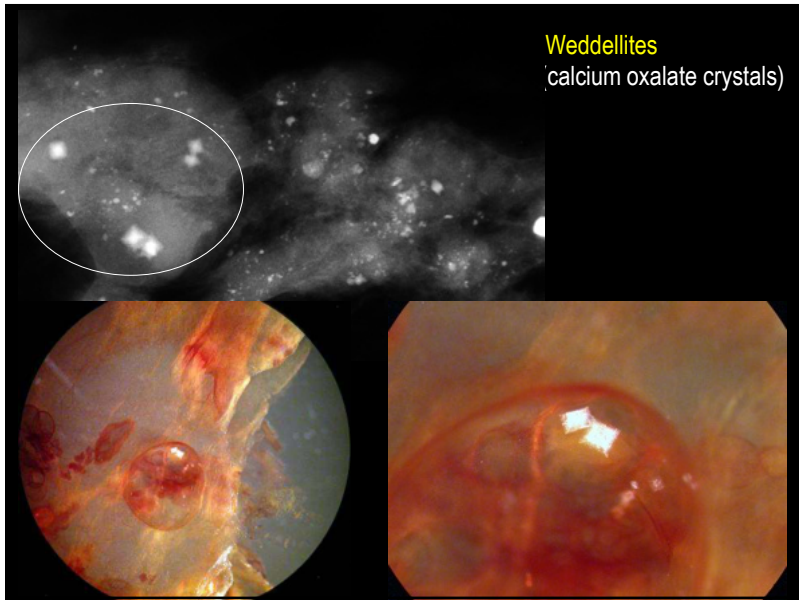

180

Nipple discharge of the breast.

Bologna, Italy

181

Lack of indication for galactography

Milky *or* turbid / cloudy discharge from multiple openings on the nipple.

182





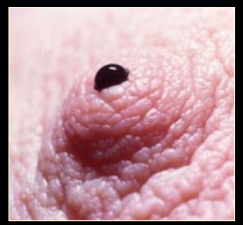

183

Indication for galactography

Bloody nipple discharge

Cancer is the underlying cause:

13%

184

Indication for galactography

Serous nipple discharge

Cancer is the underlying cause:

7 %

185

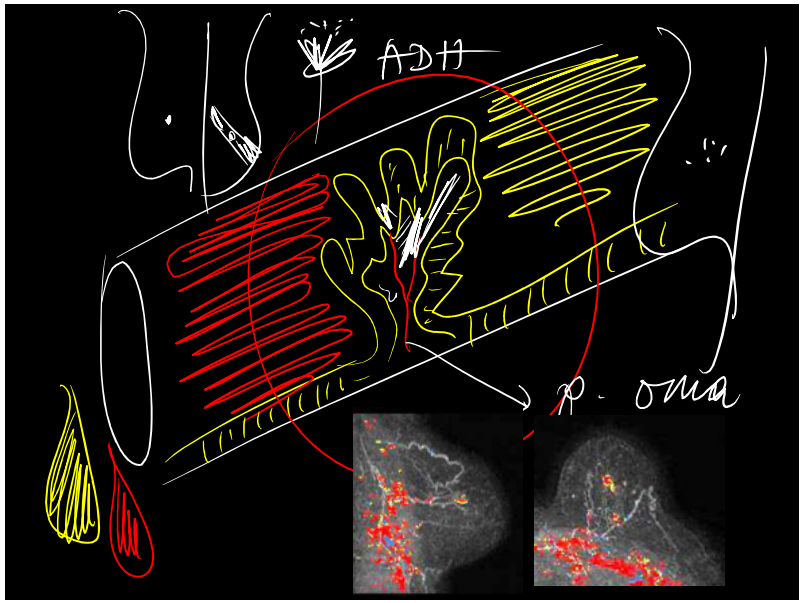

186

The procedure of choice is: *Galactography*

Benign, intraductal papilloma cases

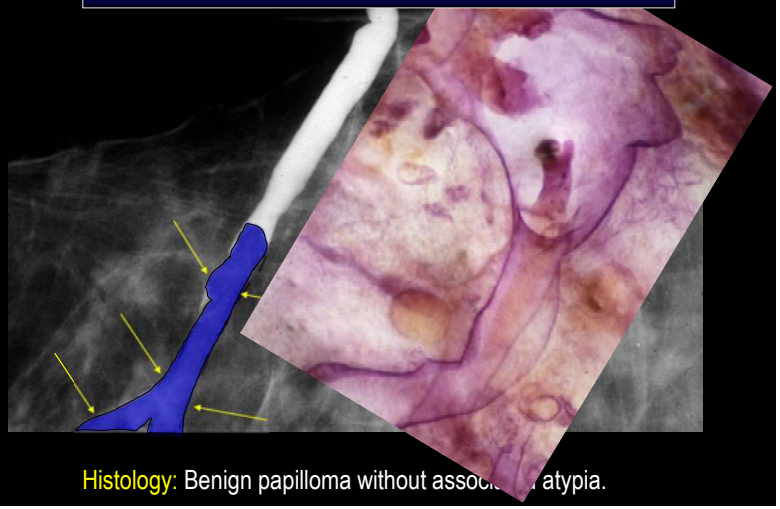

Histology: Benign papilloma without associ… atypia.

187

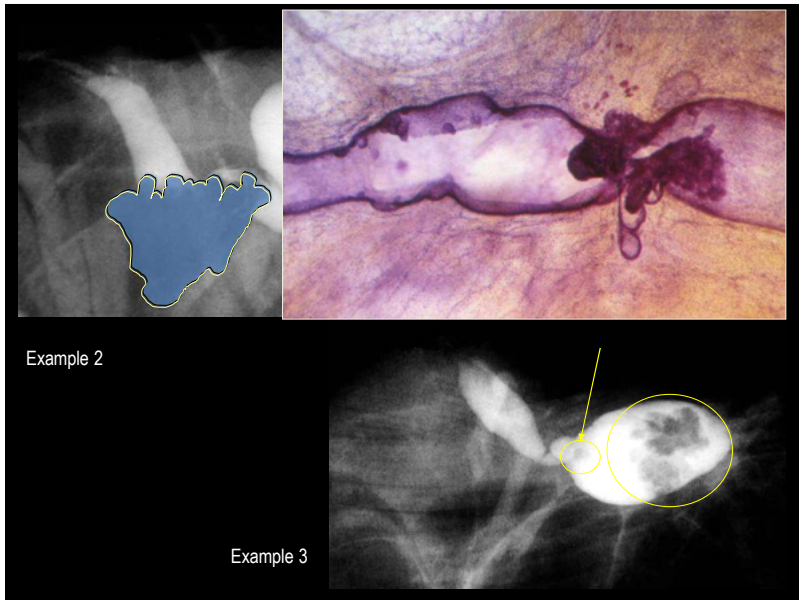

188

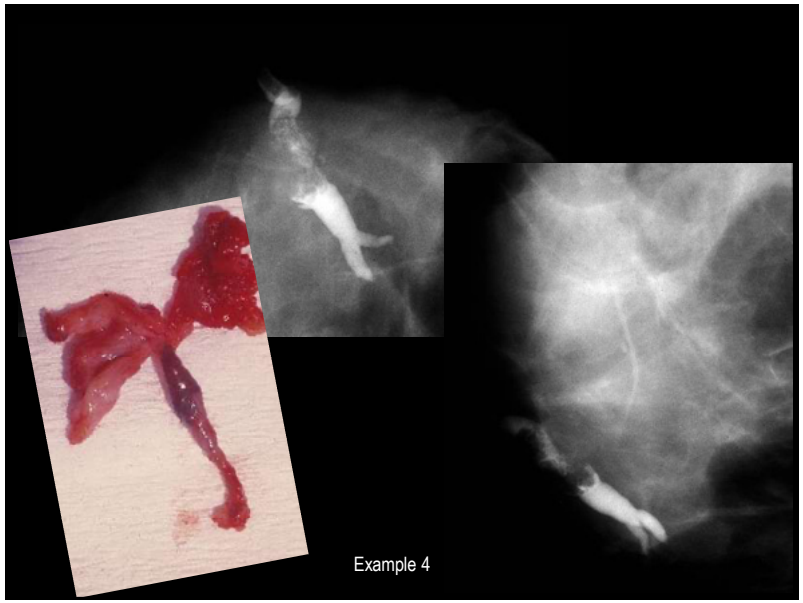

189

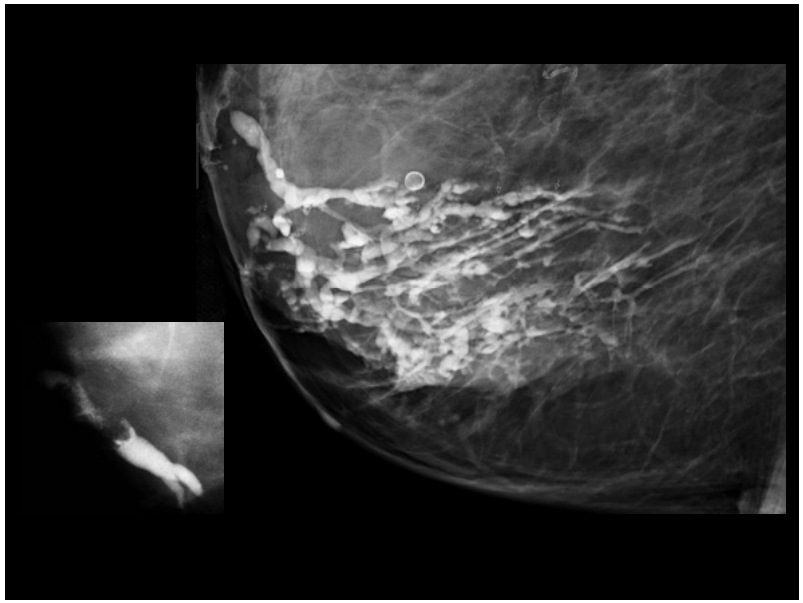

190

191

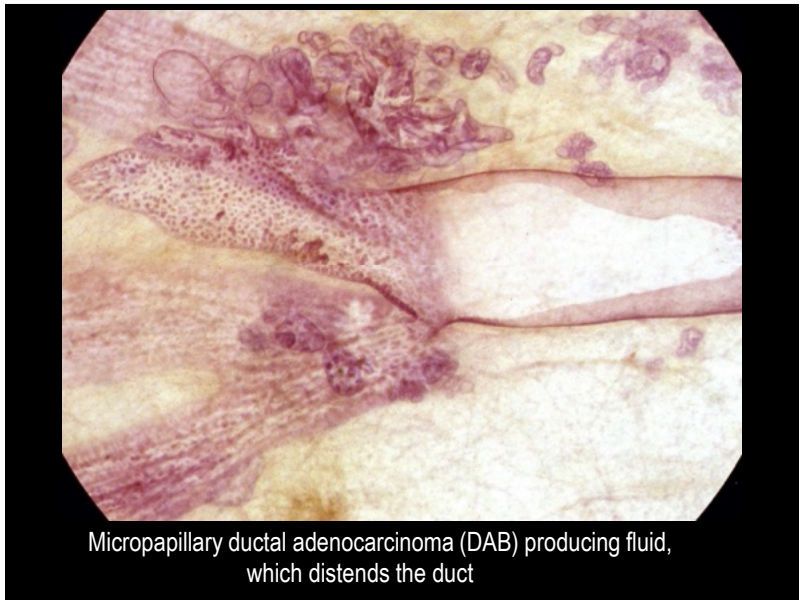

192

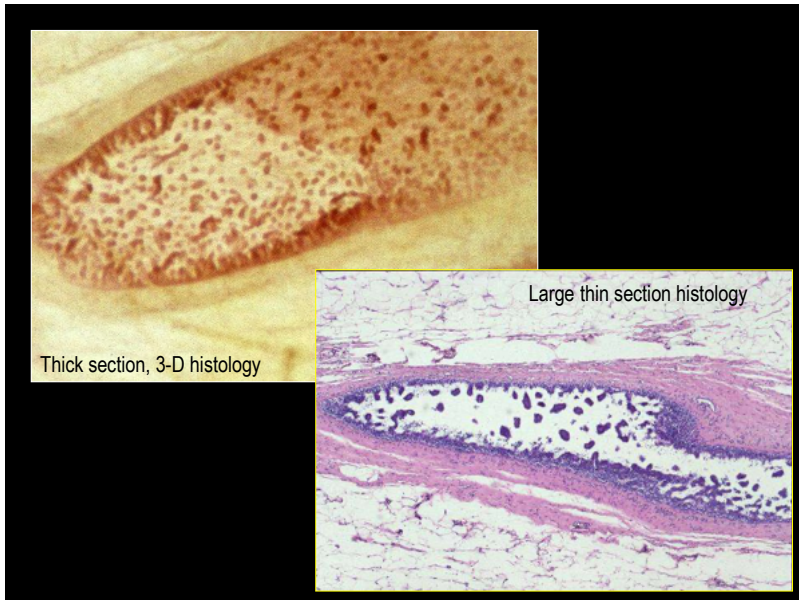

193

45-year-old woman, felt a thickening in the lower-lateral portion of her right breast. Also, she had bloody nipple discharge from the right nipple.

From the Departments of Mammography
Surgery and Clinical Pathology
Falun Central Hospital, Sweden ©

194

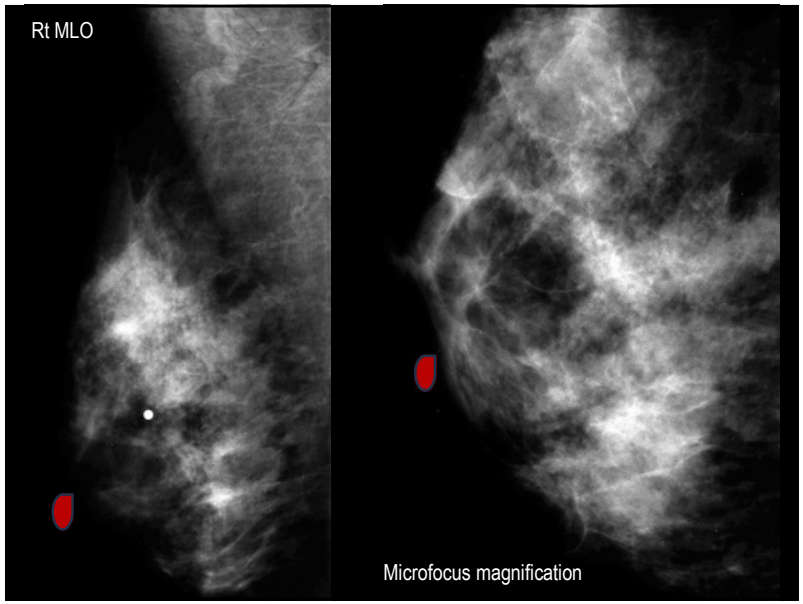

195

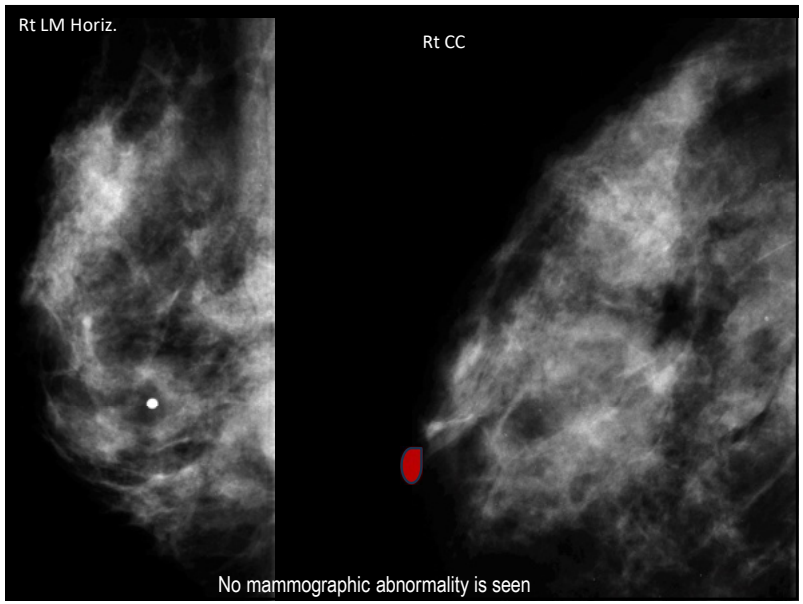

196

197

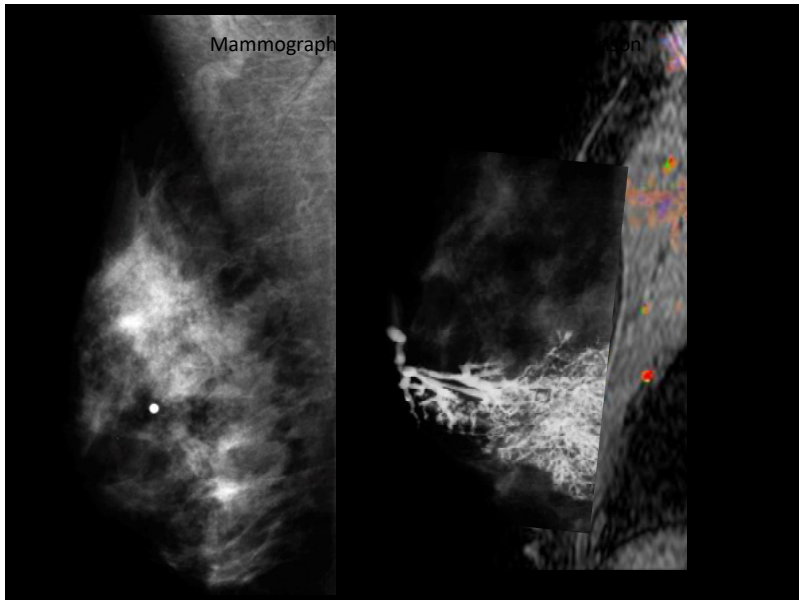

198

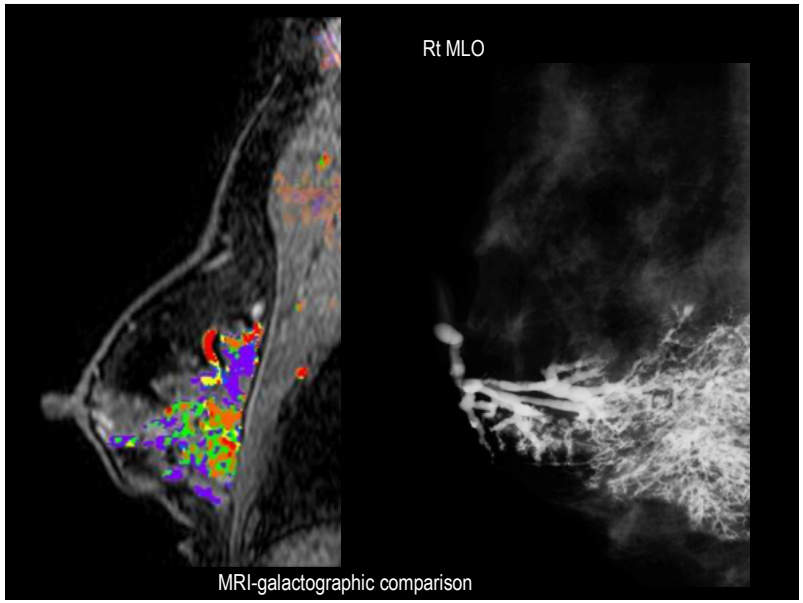

199

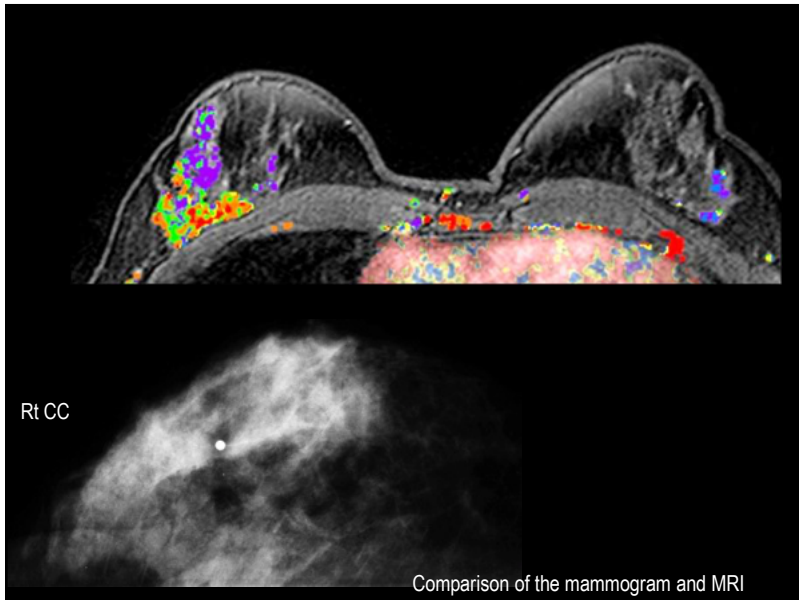

200

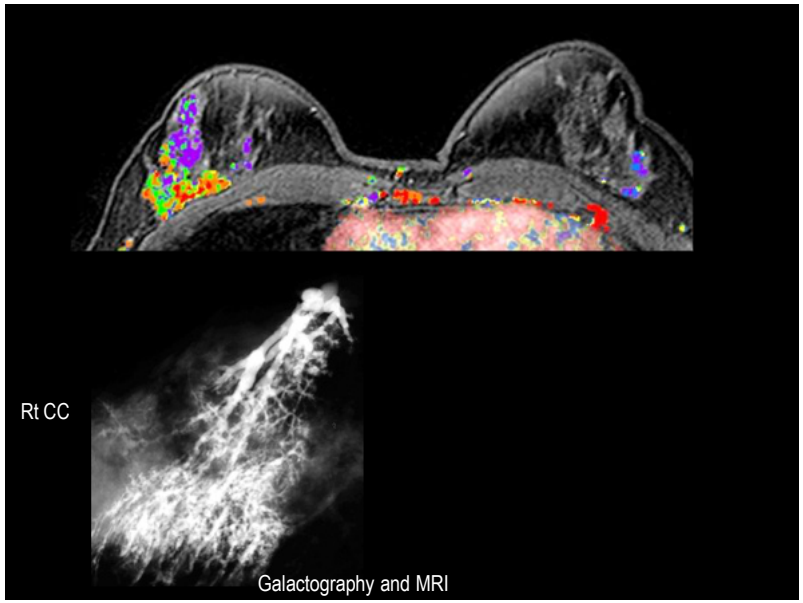

201

202

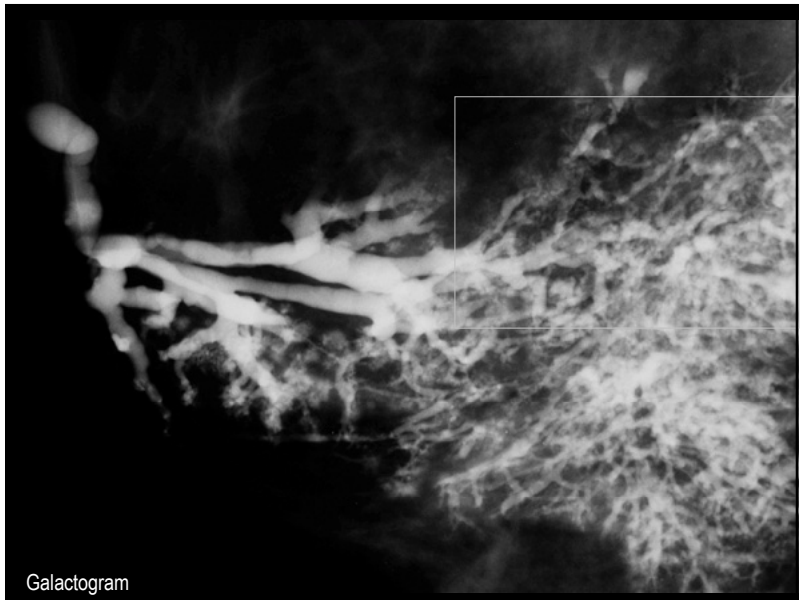

203

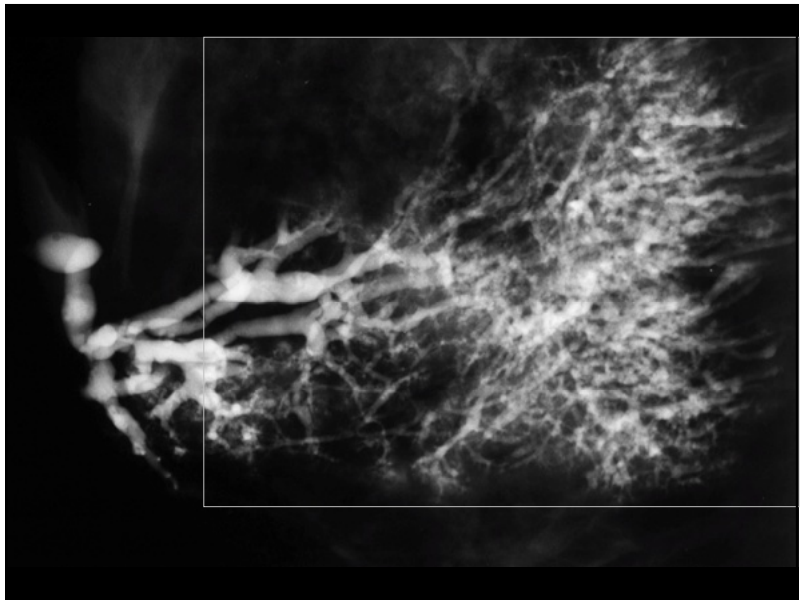

204



205

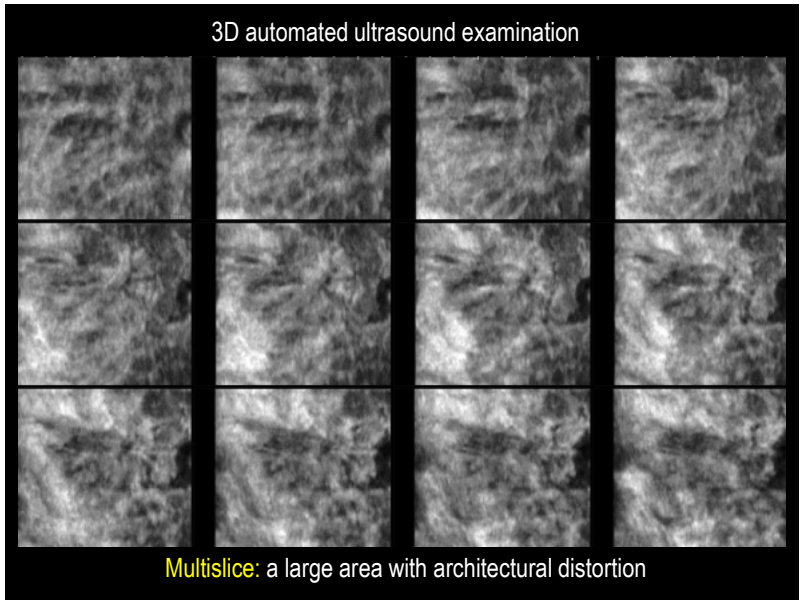

206

207

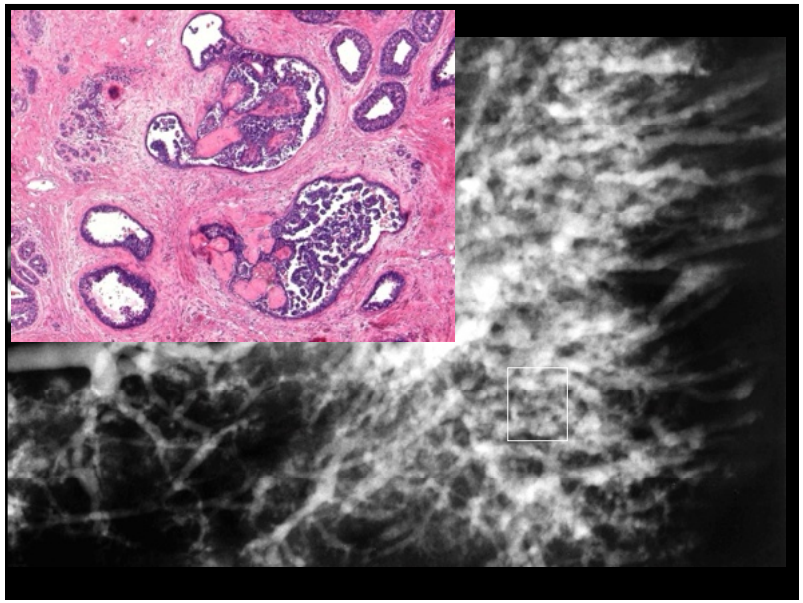

208

209