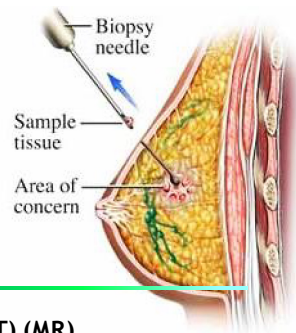


Stereotactic Biopsy- Theory and Procedure



Christine Murray, RT (R) (M) (CT) (MR)

1 | FUJIFILM

1

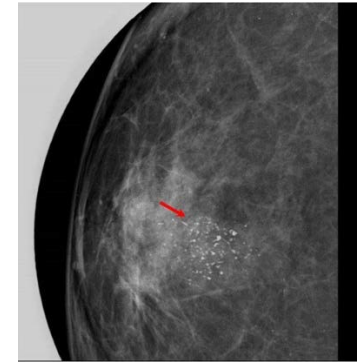
Agenda

History of Breast Biopsy
Stereotaxis and Parallax Effect

Theory
reference point
coordinate systems
stroke and stroke margin

Stereotactic Procedure and Steps

upright and prone system
biopsy needles
stereotactic biopsy
tomo biopsy
post procedure
identifying needle errors



FUJIFILM

2

The Problem:

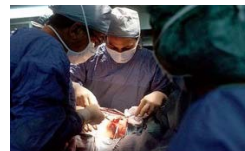Mammography can identify non-palpable breast abnormalities earlier than they can be diagnosed by physical examination.

However, some benign lesions have mammographic features that mimic malignant lesions, and some malignant lesions have mammographic features that mimic benign lesions. **The only way to definitively know what a lesion is, is to obtain a tissue sample for histology analysis.**

Open surgical biopsy was the gold-standard for many years

Drawbacks of open surgical biopsy:

- 1) Cost
- 2) Recovery time
- 3) Missed time from work
- 4) Low risk, but potential for mortality
- 5) Poor cosmetic result
- 6) internal scarring of breast tissue



Surgeon doing a surgical breast biopsy

***80% of breast biopsies are benign!!!!!!**

* F. Margolin, L. Kaufman, R. Jacobs, S. Denny, J. Schrupf "Stereotactic Core Breast Biopsy of Malignant Calcifications" Radiology vol. 233 No. 1 October 1, 2004

FUJIFILM

3

-Early 1980's Dr. Lindgren in Sweden designed a Tru-cut needle that "fired" the needle with a trigger. Hence the name biopsy gun.

-By the late 1980's radiologists heard from their urology counterparts about the quality of the specimens obtained with the Biopsy gun.

-In 1987 Dr. Steve Parker, Denver, CO introduced the Biopsy gun into his practice.

-Stereotix breast biopsy system (General Electric Medical Systems) modified to perform both surgical and core biopsies.

Dr. Parker then worked with Fischer Imaging (Denver, CO) to modify the Mammostest table to accommodate the Biopsy gun. Patient biopsies could now be performed in the prone position.

First stereotactic core biopsy performed by Parker on August 8, 1988

4 | FUJIFILM

4

- 1992 Lorad Corp (Danbury, CT) introduced a dedicated prone table called the StereoGuide.

- In the spring of 1993 radiologists: Fred Burbank, Steve Parker, Elias Zerhouni, surgeon Thomas Fogarty, and medical device engineer Mark Retchard, created a breast biopsy instrument called "Mammotome" (Biopsy Medical Systems, San Juan Capistrano, CA)

- August 5, 1994 first biopsy done with the Mammotome device- first VABB done!!



Steve Parker



Fred Burbank



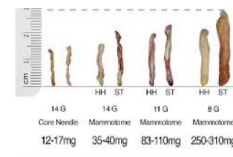
Elias Zerhouni



Thomas Fogarty

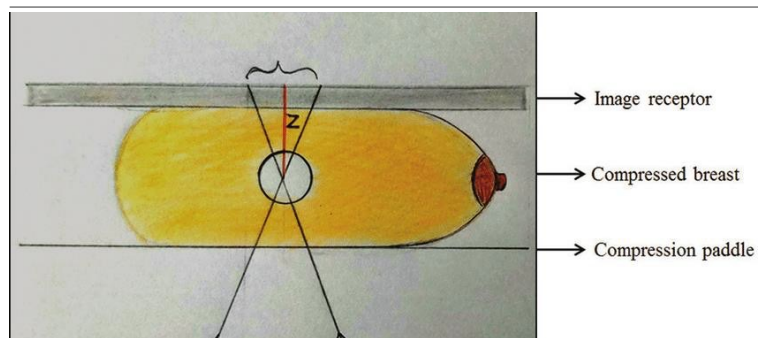
FUJIFILM

The way it was.....



FUJIFILM

Stereotactic and Parallax Effect



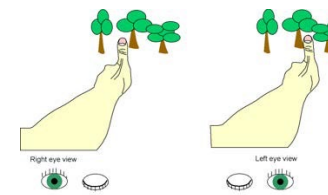
FUJIFILM

Principles of Stereology:

Stereology deals with the transformation of 2D observations to 3D information using mathematical, statistical, and geometric tools

Stereotactic biopsy involves the same principles that our brains and eyes use to accurately see a three-dimensional object





The distance of the apparent shift of your finger in relation to the reference point is called the *Parallax Shift*



Parallax effect illustrated with your thumb. Notice how your thumb held at arm's length appears to shift with respect to background objects when you look at it with one eye and then the other eye.

FUJIFILM

Parallax Effect

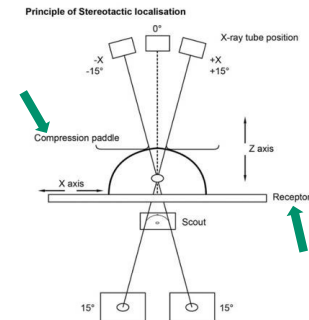
-  -The apparent movement of a lesion between projections is referred to as the parallax shift and is calculated relative to the reference point.
-  -The terms *parallax shift* and *apparent movement* are used because the breast and lesion don't move between projections.
-  -The distance of the apparent shift between the images can be used to calculate the Z depth.
-  -The location of the center of rotation of the stereotactic biopsy system **must be known** to understand the significance of the apparent motion of the lesion

9 | FUJIFILM

9

What is the Reference Point?

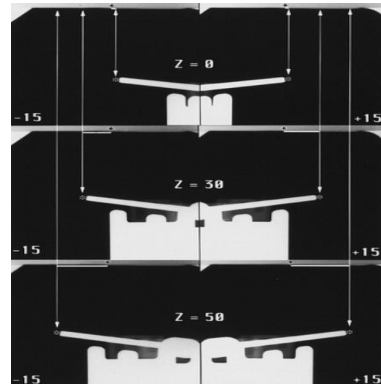
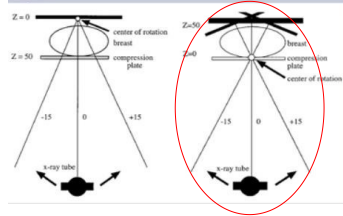
- The reference point is generally used to determine the motion in a specific area.
- It is a fixed position that does not move according to the object's apparent movement.
- The reference point defines the coordinates. Considering the three axes, X, Y and Z, or H, V and D, the intersection area of all the three axes, their origin, is known as a reference point .



FUJIFILM

10

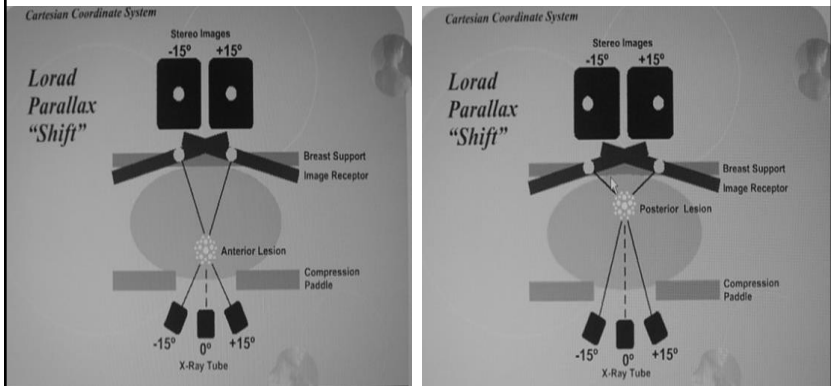
Figure 3. Relationship Between Image Parallax and Target Depth



FUJIFILM

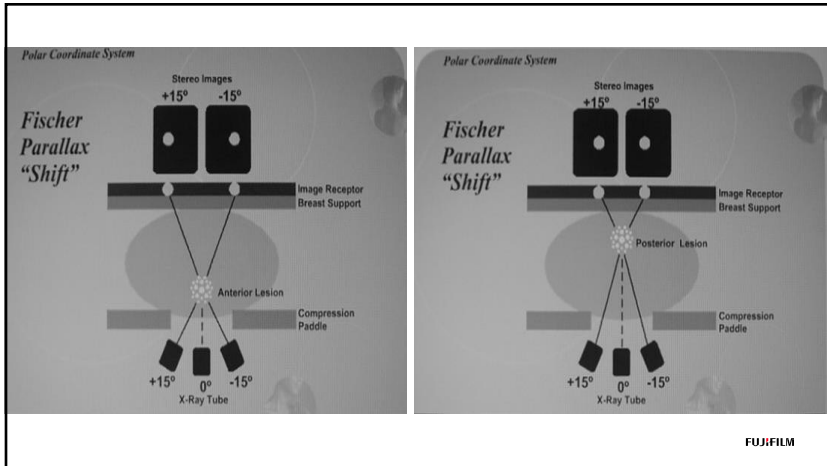
11

Lesion "Shift"

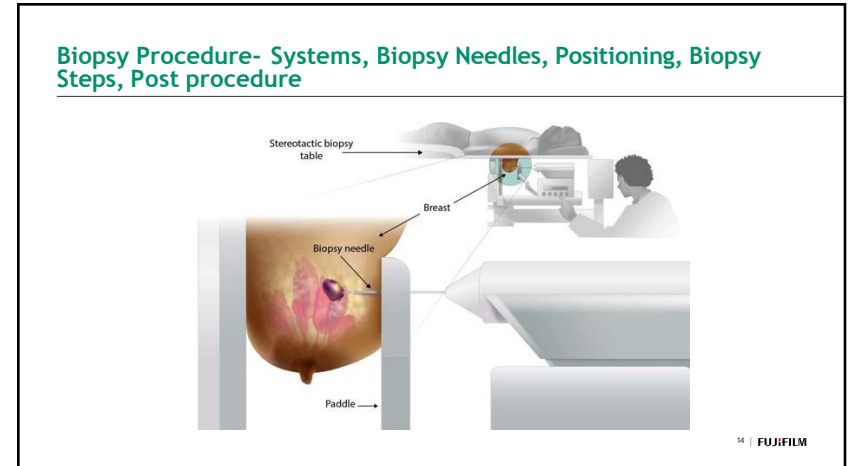


FUJIFILM

12



13



14



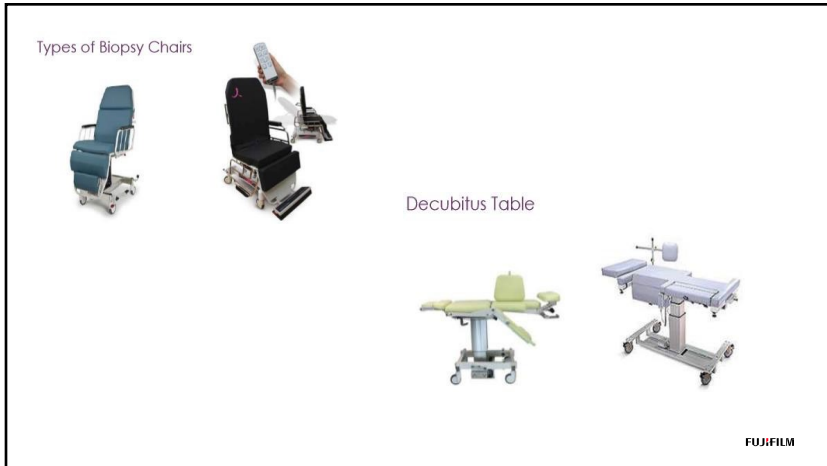15

- Don't require a dedicated room. Have a small footprint
- More cost effect than a prone table.
- Dual usage. Quickly convert mammography system for biopsy
- Biopsies can be performed with patients in an sitting position or decubitus.
- Upright biopsies can be more comfortable for certain patients. For example:
 - Patients with frozen shoulders
 - large stomachs
 - patients with neck issues
 - obese patients
- Patients may have a view of the biopsy being performed (vaso-vagal reactions)
- Upright biopsies have gotten more streamlined and faster vs. previous systems

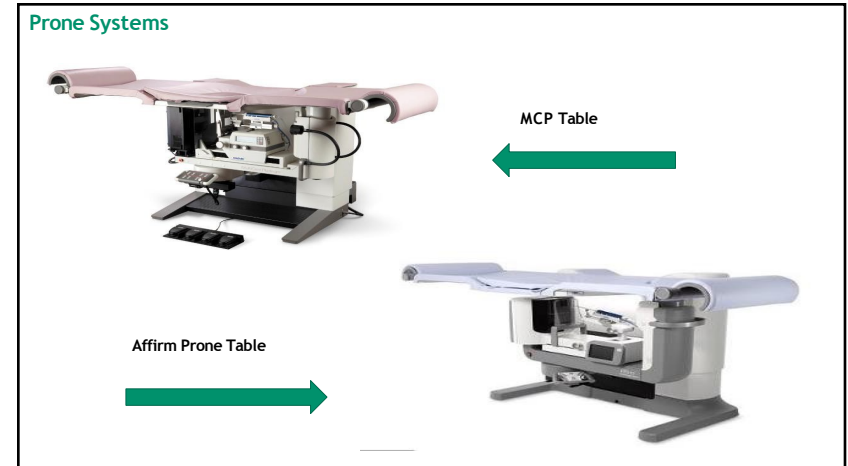
Upright Systems

FUJIFILM

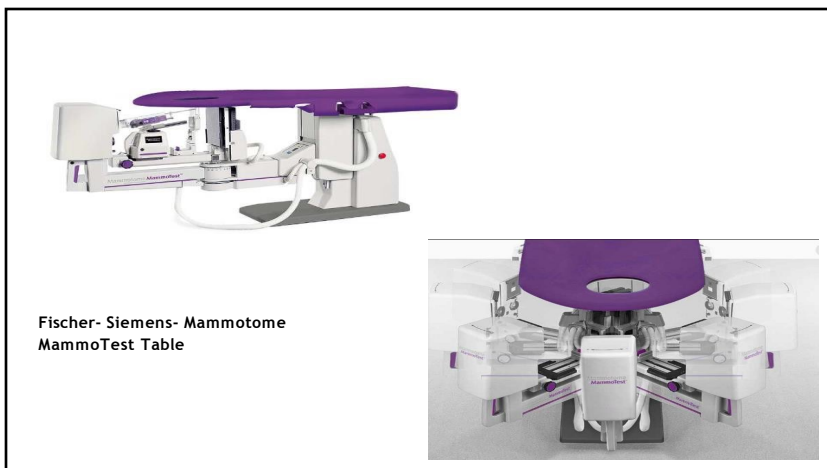16



17



18



19

- Dedicated procedure room
 - Patient positioned prone with her breast through an opening. Biopsy is done out of patient's view.
 - C-arm allows 360-degree access to breast
 - Reduce risk of vaso-vagal reactions
 - Gravity can help with posterior lesions
 - More expensive than upright option
 - Able to do Tomo biopsies (Hologic).
 - Lateral arm approach.
- Prone Systems
- FUJIFILM

20

Biopsy Needles- VAB

Mammotome

ST

Revolve



Hologic

ATEC

Eviva

Brevera



BD (Bard)

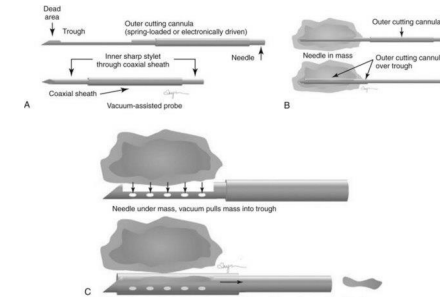
EnCor

EnCompass



21 | FUJIFILM

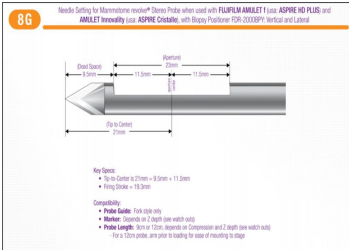
VABB Needle Operation



22 | FUJIFILM

21

22



Anatomy of a Biopsy Needle

23 | FUJIFILM

Specs if each manufacturer's needles are input into the AWS of the mammography vendor's mammography systems.

Aperture AKA Sample Notch

Dead Space- end of sample notch to probe tip

Firing Stroke AKA Throw

Tip-to-Center- is important to ensure the lesion is in the middle of the sample notch

Stroke and Stroke Margin

The distance that the driver moves the needle/probe from the "cocked" position to the "fired/pierce" position is the stroke.

The stroke margin is the distance from the tip of the probe in the "fired" position to the image receptor.

POSITIVE stroke margin indicates there is enough tissue behind the lesion in the "fired" position.

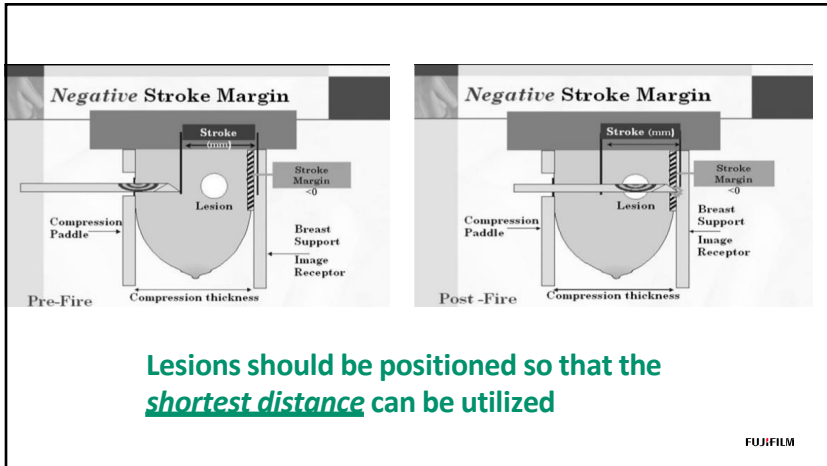
NEGATIVE stroke margin indicates the needle/probe will exit the breast and strike the image receptor

Stroke and Stroke Margin

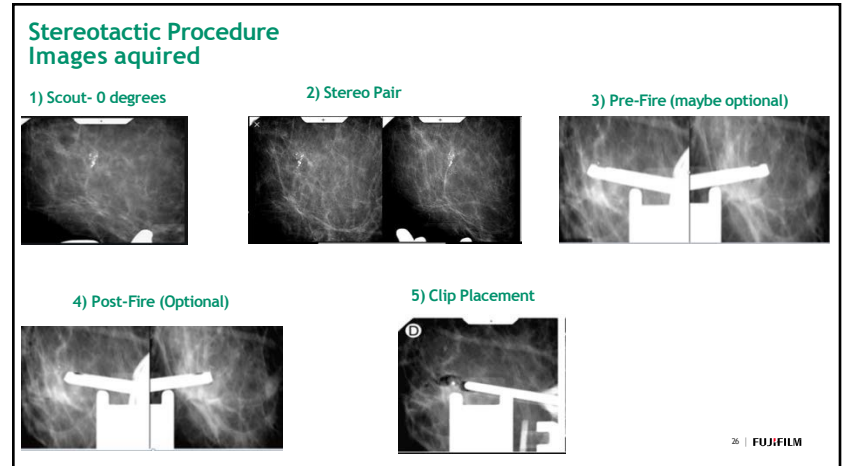
24 | FUJIFILM

23

24



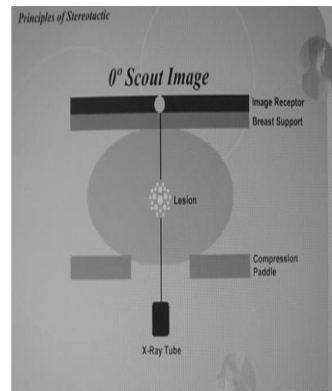
25



26

Biopsy Steps- Scout Image

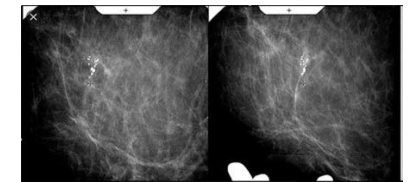
A scout image is used to locate the lesion in the center the biopsy window. ***** It's important to get the lesion as centered as possible in the biopsy window!!**



27

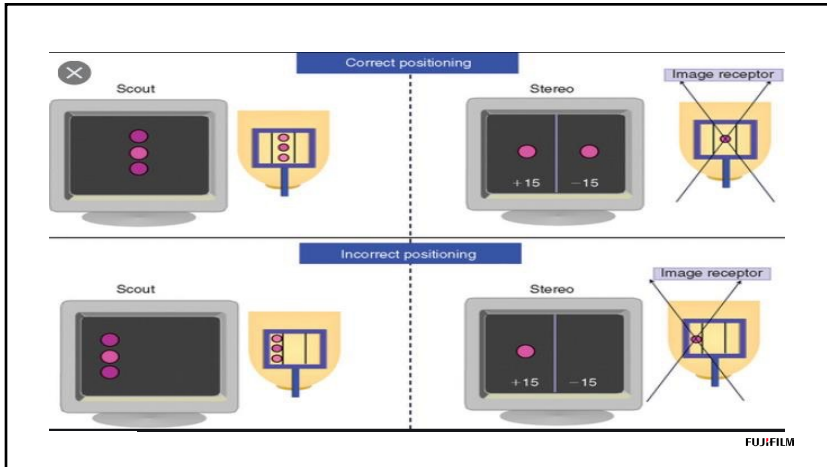
Biopsy steps- Stereo Pair

The two x rays are responsible for creating the image of the lesion center on the +15° and -15° images. By equating these two x rays, the x, y, and z coordinates of the lesion can be determined with basic trigonometry.

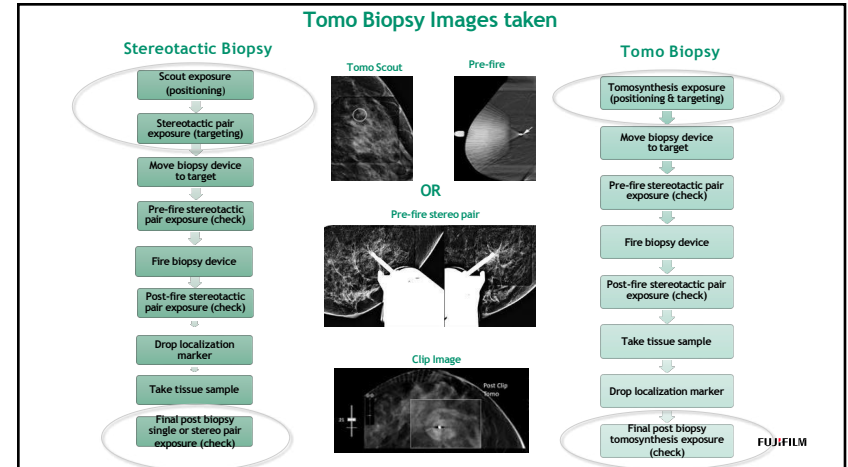


FUJIFILM

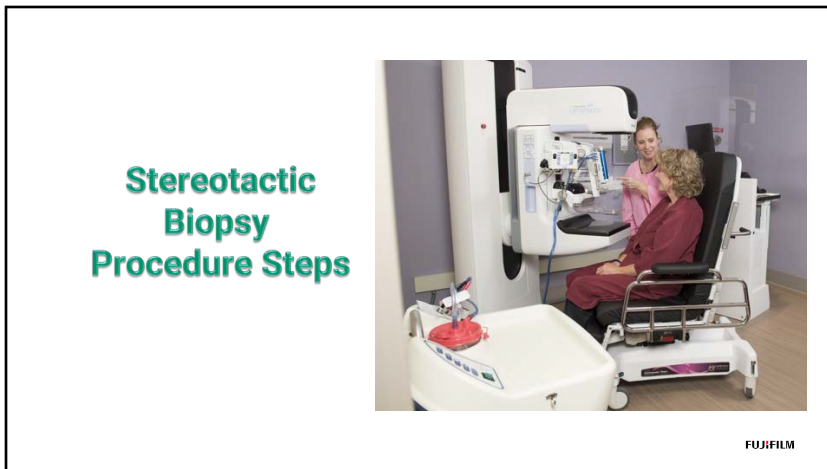
28



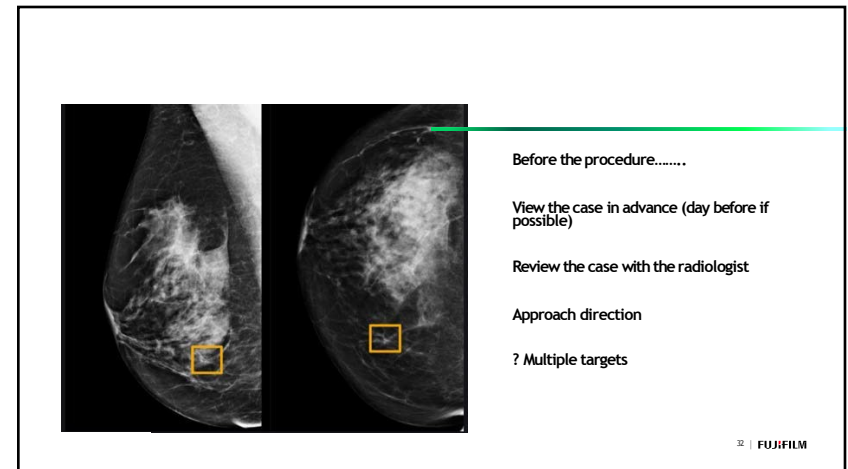
29



30



31

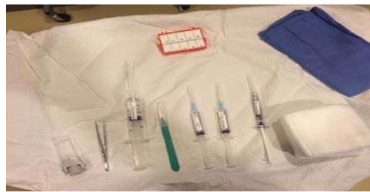
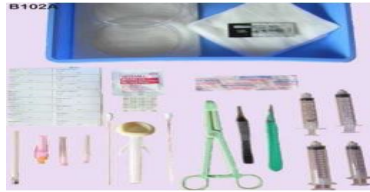
32

Tray Set-Up

Varies between facilities and physicians

- Procedure in place to include tray supplies and set up
- Pre-made biopsy trays



33

Tray/Kit includes:

- 1 12cc syringe (Standard)
- 1 6cc syringe
- 1 5cc syringe
- 1 1cc syringe
- 1 Forceps Adson® 1x2 Fine
- 10 4x4 gauze 8 ply (Standard)
- 1 Alcohol prep pad
- 1 Triple antibiotic ointment
- 1 ChloraPrep® 3ml applicator
- 1 #11 scalpel SS plastic handle (Standard)
- 2 6-inch cotton tip applicators
- 2 18 1½-inch needles (Standard to draw up meds)
- 1 20g 3 ½-inch spinal needle
- 1 22g 1 ½-inch needle
- 1 25g 1½-inch needle (Standard for superficial anesthesia)
- 1 Standard band-aid - latex free
- 2 Petri-dishes 3-inch diameter x ½ inch high
- 1 Package steri-strips ¼ x 1.5 inch, 3 strips/card (Standard)
- 2 Disposable towels 17x19 inches, 2PP White
- Identifier labels (anesthetic, lidocaine, epinephrine, sterile saline) (Standard)

FUJIFILM

34

Technologist

Prepare - Know orientation of breast and how it displays on the monitor

Needle size Standard vs. Petite

Depends on thickness of breast and location of targeted area

Possible patient limitations

Frozen shoulder, range of motion with neck/shoulders, unable to be seated upright or be in prone position for period of time

Type of clip to use - have a selection of 2-4 to choose from
Sensitivity to certain materials ie: nickel

****Marking side of interest - Radiologist - Facility specific
"Time Out" Protocol in place

FUJIFILM

35

Patient

Before getting started....

Explain the procedure to the patient.

- The importance of staying still
- Anesthesia
- Marker/clip placement
- Have them sign the consent form

Screening the patient -

- Diabetic
- Anti-coagulants • Radiologist preference on if/when to discontinue
- Anxiety medication • Not to take until consent is signed
- Allergies to medication • Lidocaine • Betadine/Chloraprep

FUJIFILM

36

Preparing the Patient:

Chucks to protect clothing...and equipment

- Warm blanket
- Wet wash cloths
- Emesis basin
- Room temperature
- Sheet for table or chair
- Pillows
- Padding
- Ammonia inhalants

- Relaxation Tools - Aromatherapy
- Lavender - Aids in relaxation
- Orange - Nausea
- Calming décor/pictures
- Light music
- Guided imagery
- Serenity Suites - all bundled into one

FUJIFILM

37

Positioning the Patient:

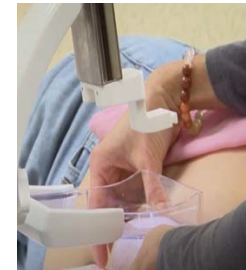Upright

Biopsy chair

Upright, decubitus, lateral, medial

Prone

Lateral, medial, CC, FB.



***Get the patient as comfortable as possible. It's the key to a successful biopsy*

Remember a moving patient is a moving lesion and a moving lesion can't be biopsied!

FUJIFILM

38

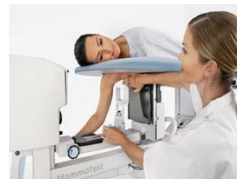Positioning Tricks

For lesions close to the chest wall consider a MLO or LMO approach

XCC's can also be done and arm through the hole

Benzoin tincture can also be used to prevent skin/tissue from slipping out of compression. The tincture makes the skin slightly tacky

For fine or hard to see calcs- Tegaderm can be placed over the biopsy opening. This provides a little compression to the area.



FUJIFILM

39

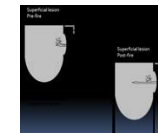
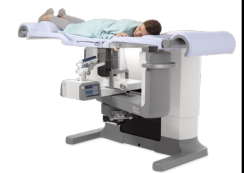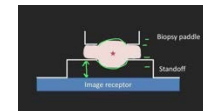
Positioning tricks- continued

For thin breasts:

- Use spacer
- Petite needle OR standard needle can be used and inserted in the post-fire position
- Lateral arm

For superficial lesions:

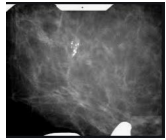
- "Pouching" of the tissue through the biopsy window can help
- Insert needle in more so that lesion is in the back of the sample notch



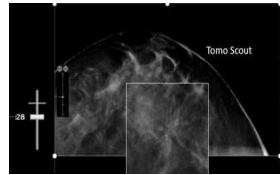
FUJIFILM

40

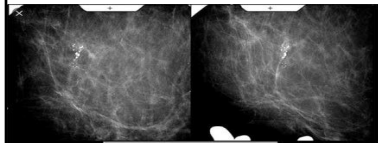
Procedure- Images



0-degree Scout



Scroll through slices until the lesion is well seen. This is your depth (Z)



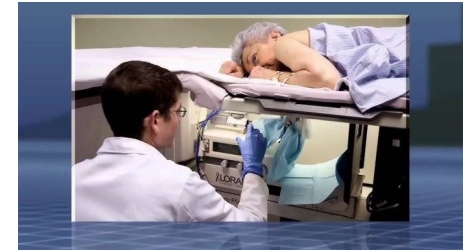Stereo Pair

FUJIFILM

41

Radiologist- Prep before Biopsy

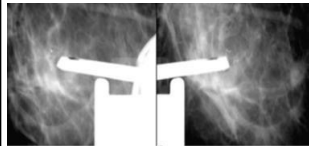
- 1) Clean skin in biopsy area with antiseptic
- 2) Move biopsy device to the appropriate X and Y coordinates
- 3) Dial needle tip closer to skin to use as guidance (depth, dial down Z)
- 4) Inject superficial anesthesia to numb skin
- 5) Use an #11 blade scalpel to make skin nick
- 6) Inject deep anesthesia
- 7) Move biopsy needle to pre-fire position
- 8) Image confirmation



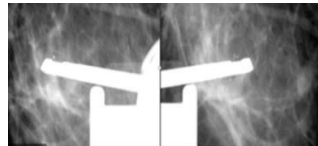
FUJIFILM

42

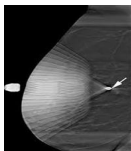
Procedure- Images



Pre-Fire



Post-Fire



Tomo Pre-Fire

Is the Needle in the Correct Position?
 • Pre-fire & Post-fire Needle Position
 - Has the Lesion Moved?
 Patient movement, deep anesthesia pushed lesion
 - How Do I Correct the Situation?
 Do you need to re-target?
 Directional Sampling
 **Most VAB needle will pull tissue in from ~5mm away

FUJIFILM

43

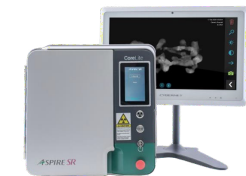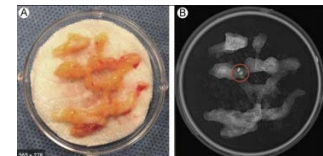
Specimen Radiograph

Confirms Calcifications have been biopsied

Cancer can potentially be missed if calcifications are not demonstrated*

-Miss rate 1% with retrieval

- 11% without retrieval

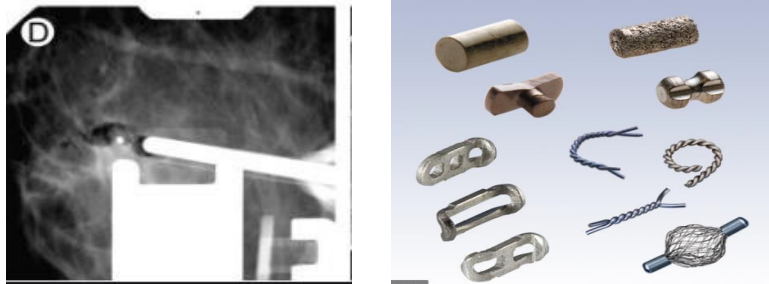


FUJIFILM

*Radiology 2004;233:251-54

44

Clip Placement and Biopsy Markers

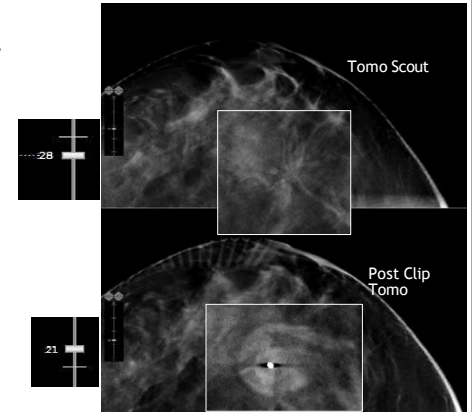


FUJIFILM

45

Post Biopsy & Clip Placement

- Display original tomo scout to view target
- Scroll up and down on post biopsy tomo
 - Check if lesion is gone
Compare depth
 - hematoma/cavity ↔ lesion on target
- View Clip



46

Post Procedure

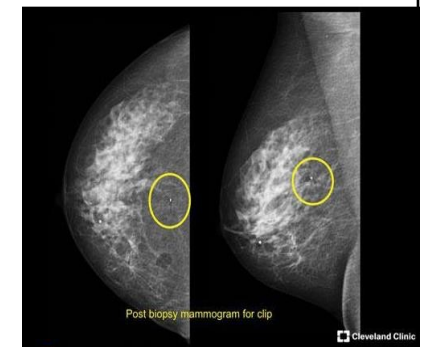- Firm compression at the biopsy site **NOT** the at incision for at least 10 minutes.
- Patient should avoid any strenuous lifting or activities.
- Patient should observe for local bleeding or signs of infection.
- Medications can be started back up as per doctors orders
- Tylenol for pain. No Advil or Motrin
- Complications are rare but may include: hematoma, infection, bleeding

FUJIFILM

47

Post-Biopsy mammogram

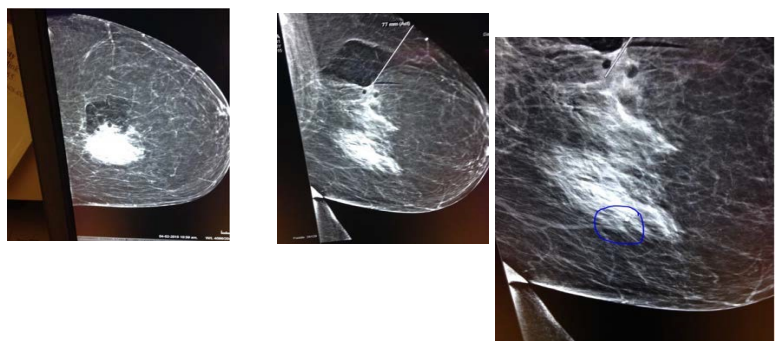
- Confirms clip placement
- Shows that the patient has had a biopsy on future mammograms
- Guide for needle localization if needed



Cleveland Clinic
FUJIFILM

48

Clip Migration due to Hematoma



FUJIFILM

49

Accordion Effect after Biopsy

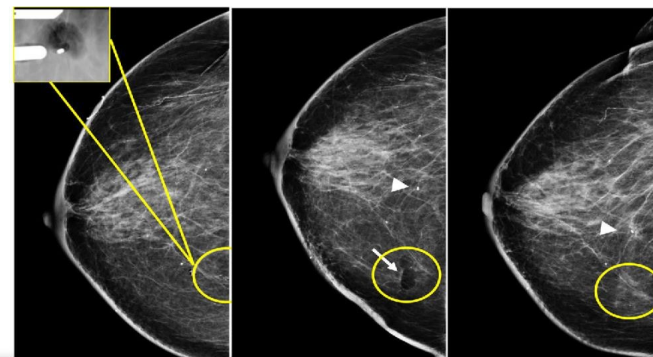
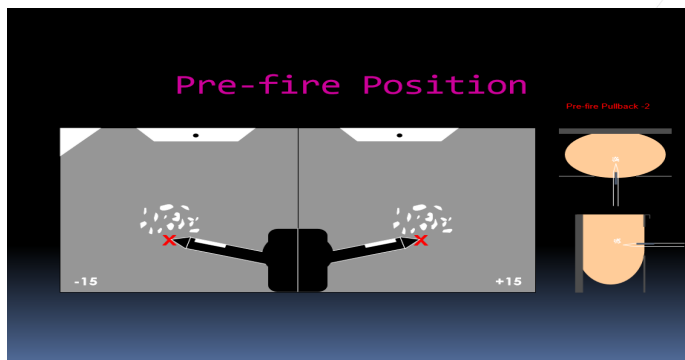


Fig. 1 Clinical example of accordion effect after stereotactic biopsy procedure. (left) Diagnostic mammogram of 68-year-old patient with suspicious calcifications circled in yellow (inset: subsequent stereotactic... Continue Reading

50

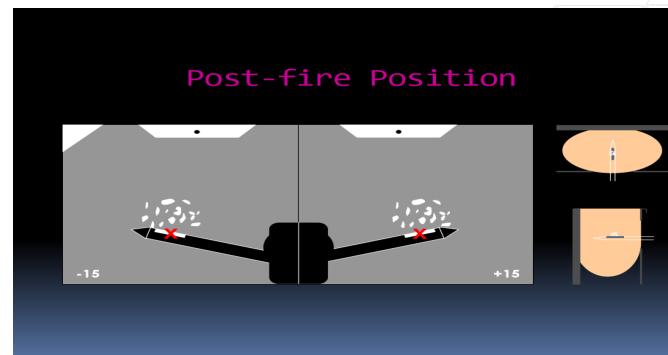
Pre-fire Position



FUJIFILM

51

Post-fire Position



FUJIFILM

52

X or Horizontal Error

Sampling should be increased between 12 and 6 o'clock going through 3 o'clock

FUJIFILM

53

X or Horizontal Error

Sampling should be increased between 12 and 6 o'clock going through 9 o'clock

FUJIFILM

54

Y or Vertical Error

Sampling should be increased between 9 and 3 o'clock going through 12 o'clock

FUJIFILM

55

Y or Vertical Error

Sampling should be increased between 9 and 3 o'clock going through 6 o'clock

FUJIFILM

56

Z or Depth Error

The depth must be decreased by pulling back the probe

FUJIFILM


57

Z or Depth Error

The depth must be decreased by pulling back the probe

FUJIFILM

58



59