The Importance of Standardized Positioning:
The Basics of Mammography That You Were Never Taught

Presented by:
Millie Castellanos, B.S., R.T.(R)(M)(ARRT)(CRT)
Director of Education, Mammography Educators

Content created by:
Louise Miller, R.T.(R)(M)(ARRT), CRT(M), FSBI, FNCBC

© 2026 Mammography Educators

1

cmajOPEN

Research

Evaluation of the quality of mammographic breast positioning: a quality improvement study

Julie Rouette MSc, Noémie Elfassy MD, Nathaniel Bouganim MD, Hui Yin MSc, Nathaniel Lasry PhD, Laurent Azoulay PhD

Abstract

Background: Although there are concerns that inadequate breast positioning in mammographic examinations may lead to cancers being missed, few studies have examined the quality of breast positioning, especially in the Canadian context. Our objective was to assess the quality of breast positioning in mammographic examinations in a Quebec-wide representative sample of technologists.

Methods: This quality improvement study was part of a professional inspection launched by the Ordre des technologues en imagerie médicale, en radio-oncologie et en électrophysiologie médicale du Québec among its members. The inspection was conducted between May and July 2017 on a proportionate stratified random sample of all active technologists certified in mammography in Quebec. Each technologist provided images from 15 consecutive mammographic examinations they performed in the previous 6 months. The quality of positioning was then evaluated by senior technologists using a quality assessment tool specifically developed for this inspection. A technologist was deemed to have failed the professional inspection when at least 7 of the 15 mammographic examinations were scored as critical failures. Proportions were calculated accounting for sampling weights and correction for finite population.

Results: Among the 520 technologists certified in mammography in Quebec, 76 technologists (14.6%) were randomly selected for the professional inspection and contributed images from 1127 mammographic examinations. Thirty-eight technologists (weighted percentage 50.3%, 95% confidence interval [CI] 37.6% to 63.0%) failed the professional inspection. Overall, 492 mammographic examinations (43.7%, 95% CI 38.6% to 48.8%) had at least 1 image scored as a critical failure.

Interpretation: Half of the technologists performing mammographic examinations in Quebec who participated in this study failed the inspection, and a substantial proportion of their mammographic examinations demonstrated critical failures in breast positioning. Overall, our findings are concordant with those of previous studies and highlight the need for additional investigations assessing the quality of breast positioning in mammographic examinations in other jurisdictions.

Source: Canadian Medical Association Journal, 2017

2

U.S. Department of Health and Human Services

FDA U.S. FOOD & DRUG ADMINISTRATION

A to Z Index | Follow FDA | En Español

Search FDA

Home | Food | Drugs | Medical Devices | Radiation-Emitting Products | Vaccines, Blood & Biologics | Animal & Veterinary | Cosmetics | Tobacco Products

Radiation-Emitting Products

Home › Radiation-Emitting Products › Mammography Quality Standards Act and Program › MQSA Insights

MQSA Insights

MQSA Insights Articles

MQSA National Statistics

Poor Positioning Responsible For Most Clinical Image Deficiencies, Failures

SHARE | TWEET | LINKEDIN | PIN IT | EMAIL | PRINT

Mammography combines "the science of imaging and the art of positioning" [1]. Although there have been many significant and exciting changes to the technology of mammography since the passage of MQSA in 1999, including the introduction of full-field digital mammography (FFDM) and digital breast tomosynthesis (DBT), one aspect of mammography that remains unchanged and critically important is proper patient positioning.

Positioning is so important because only those portions of the breast which are included on the mammographic image can be evaluated for signs of cancer. Any portion of the breast which is not imaged cannot be evaluated, and cancers in those portions of the breast can be missed. In a 2002 study, the "[s]ensitivity [of mammography] dropped from 84.4% among cases with passing positioning to 66.3% among cases with failed positioning" [2].

Poor positioning has been found to be the cause of most clinical image deficiencies and most failures of accreditation. In 2015, the American College of Radiology (ACR), the largest FDA-approved accreditation body (AB), found that of all clinical images which were deficient on the first attempt at accreditation, 92% were deficient in positioning. Also, in ACR-accredited facilities, 79% of all unit accreditation failures in 2015 were due to

Source: U.S. Food & Drug Administration

3

US Food and Drug Administration

- "In a 2002 study, the '[s]ensitivity [of mammography] dropped from 84.4% among cases with passing positioning to 66.3% among cases with failed positioning'."
- "Poor positioning has been found to be the cause of most clinical image deficiencies and most failures of accreditation." (92%)

4

Decreased Sensitivity

- 84.4% with proper positioning
- 66.3% with failed positioning

= 18.1% decreased sensitivity



MAMMOGRAPHY EDUCATORS

5

Poor Positioning = Missed Breast Cancers



MAMMOGRAPHY EDUCATORS

6

Quality Standards – Why?

ALL industries have established standardized methods in the performance of tasks to:

- Establish and maintain quality
- Increase consumer satisfaction
- Increase profit
- Reduce possibility of litigation
- Reduce errors



MAMMOGRAPHY EDUCATORS

7

How do we reduce medical errors?

- Standardization
- Consistency
- Reproducibility



MAMMOGRAPHY EDUCATORS

8



MAMMOGRAPHY EDUCATORS

9

Standardized Technologist Training for General Radiology



MAMMOGRAPHY EDUCATORS

10

Standardization

We *all*:

- Position the same way for every body part
- Position in the same sequence
- Set up the machine before we bring in the patient
- Position the whole patient, not just the body part

MAMMOGRAPHY EDUCATORS

11

In General Radiology…

All training is competency based and a technologist's skills will be evaluated for *positioning techniques*, as well as *clinical image evaluation.*

MAMMOGRAPHY EDUCATORS

12





MAMMOGRAPHY EDUCATORS

13

Consistency and Ergonomics

- **M**achine
- **P**atient
- **B**ody Part (Breast)

MAMMOGRAPHY EDUCATORS

14

We position the **whole patient**,
not just the body part!

MAMMOGRAPHY EDUCATORS

15







MAMMOGRAPHY EDUCATORS

16

All exams are done using the *same* positioning technique, in the *same* sequence.



MAMMOGRAPHY EDUCATORS

17

Why???

- Consistency
- Reproducibility
- Efficiency
- Proficiency
- Use of proper body mechanics



MAMMOGRAPHY EDUCATORS

18

But in mammography…We are ”all over the map”

- LCC, LMLO, RMLO, RCC
- RCC, LCC, RMLO, LMLO
- RMLO, RCC, LMLO, LCC
- LCC, RCC, LMLO, RMLO
- RCC, RMLO, LMLO, LCC
- LCC, LMLO, RCC, RMLO
- LMLO, LCC, RCC, RMLO



MAMMOGRAPHY EDUCATORS

19

My Suggestion

- CCs first
- Then do the MLO on the side you just finished the CC
- Finish with the other MLO

Example: RCC, LCC, LMLO, RMLO



MAMMOGRAPHY EDUCATORS

20

So why is this true for all body parts in radiology EXCEPT in Mammography???

21

In Mammography…

- Most technologists have not been taught a standardized method of positioning
- Most technologists have been taught various positioning methods by various technologists

22

Most technologists *do not* practice a standardized method of positioning or position the same way.

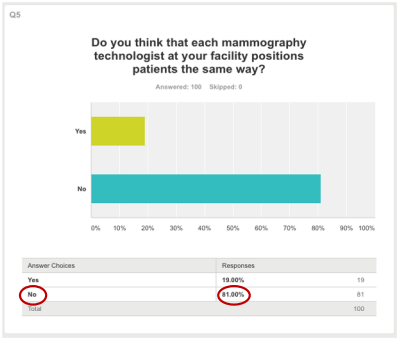

23

No Standards for Mammography Positioning

There are standards for *WHAT* images should look like, but not *HOW* you get to that point!

24

So the problem is…

No standardization or follow-through, which means:

- Less consistency and reproducibility
- More repeats and rejects
- More accreditation failures
- Increased radiation exposure
- MISSED BREAST CANCERS



MAMMOGRAPHY EDUCATORS

25

How can we make things better?

Consistency and Reproducibility



MAMMOGRAPHY EDUCATORS

26

Mammography Positioning Techniques

Should be:

- Consistent
- Reproducible
- Efficient
- Proficient
- Based on sound ergonomic principles



MAMMOGRAPHY EDUCATORS

27

Common Work-Related Injuries

- Wrists
- Shoulders
- Back
- Knees
- Hips



MAMMOGRAPHY EDUCATORS

28

YES!!!



NO!!!



MAMMOGRAPHY EDUCATORS

29

YES!!!



NO!!!



MAMMOGRAPHY EDUCATORS

30

YES!!!

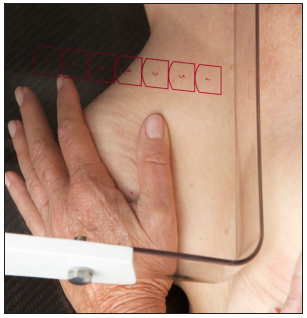

NO!!!

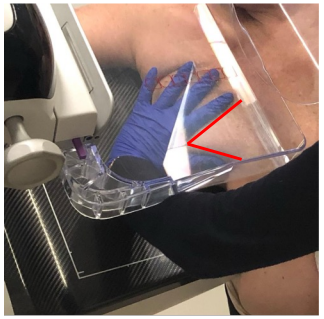

MAMMOGRAPHY EDUCATORS

31

Do Standardized Positioning Techniques for Mammography Work?

- Scientific studies prove that standardized positioning techniques improve quality
  - Visualization of more posterior and lateral breast tissue, IMF and pectoralis muscle on the CC
- Unpublished data showed that standardized positioning techniques decrease repeats, rejects and technical callbacks by up to 50%!

MAMMOGRAPHY EDUCATORS

32

AJR
American Journal of Roentgenology

:hael Linver on 09/06/17 from IP address 76.113.43.146. Copyright ARRS. For personal use only; all rights reserved

Mammography Positioning Standards in the Digital Era: Is the Status Quo Acceptable?

Ashley I. Huppe[1]
Kelly L. Overman[2]
Jason B. Gatewood[1]
Jacqueline D. Hill[1]
Louise C. Miller[3]
Marc F. Inciardi[1]

Huppe A, Overman K, Gatewood JB, Hill JD, Miller LC, Inciardi MF

OBJECTIVE. The objective of our study was to evaluate positioning of full-field digital mammography (FFDM) and digital breast tomosynthesis (DBT) compared with film-screen (FS) mammography positioning standards.

MATERIALS AND METHODS. A retrospective study was conducted of consecutive patients who underwent screening FFDM in 2010–2012 and DBT in 2012–2013 at an academic institution. Examinations were performed by five experienced technologists who underwent updated standardized positioning training. Positioning criteria were assessed by consensus reads among three breast radiologists and compared with FS mammography data from a 1993 study by Bassett and colleagues.

RESULTS. One hundred seventy patients ($n = 340$ examinations) were analyzed, showing significant differences between FFDM and DBT examinations ($p < 0.05$) for medial or inferior skin folds (FFDM vs DBT: craniocaudal [CC] view, 16% [$n = 56$] vs 23% [$n = 77$]; mediolateral oblique [MLO] view, 35% [$n = 118$] vs 45% [$n = 154$]), inclusion of lateral glandular tissue on CC view (FFDM vs DBT, 73% [$n = 247$] vs 81% [$n = 274$]), and concave pectoralis muscle shape (FFDM vs DBT, 36% [$n = 121$] vs 28% [$n = 95$]). In comparison with Bassett et al. data, all positioning criteria for both FFDM and DBT examinations were significantly different ($p < 0.05$). The largest differences were found in visualization of the pectoralis muscle on CC views and the inframammary fold on MLO views, inclusion of posterior or lateral glandular tissue, and inclusion of skin folds, with DBT and FFDM more frequently exhibiting all criteria than originally reported Bassett et al. findings.

CONCLUSION. DBT and FFDM mammograms more frequently include posterior or lateral tissue, the inframammary fold on MLO views, the pectoralis muscle on CC views, and skin folds than FS mammograms. Inclusion of more breast tissue with newer technologies suggests traditional positioning standards, in conjunction with updated standardized positioning training, are still applicable at the expense of including more skin folds.

MAMMOGRAPHY EDUCATORS

Source: American Journal of Roentgenology: 209, December 2017

33

Criteria Met After Standardized Training

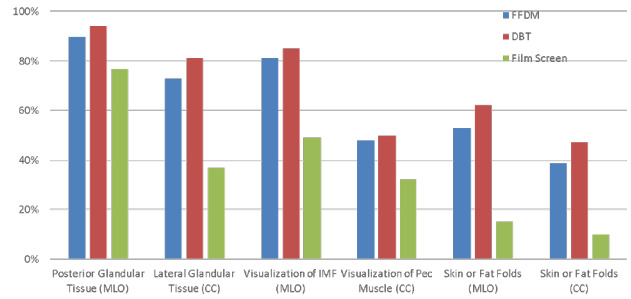

MAMMOGRAPHY EDUCATORS

Source: American Journal of Roentgenology: 209, December 2017

34

Reasonable Expectations for the CC

	Positioning Criteria	FFDM	DBT	Bassett
CC View	Pec Muscle Visualized	48%	50%	32%
	No Motion	100%	98%	-
	Lateral Glandular Tissue Included	73%	81%	37%
	Nipple in Profile	83%	85%	89%
	Skin or fat folds	39%	47%	10%
	Medial Location	16%	23%	-
	Lateral Location	29%	32%	-
	Visualization of Cleavage	41%	34%	-
	Requires More Than One View	5%	7%	-

MAMMOGRAPHY EDUCATORS

Source: American Journal of Roentgenology: 209, December 2017

35

Reasonable Expectations for the MLO

	Positioning Criteria	FFDM	DBT	Bassett
MLO View	Visualization of Pec Muscle to PNL	86%	87%	81%
	Concave Pec	36%	28%	-
	Straight Pec	41%	46%	-
	Convex Pec	23%	26%	-
	Wide Margin at Top of Pec	95%	93%	-
	No Motion	98%	97%	99%
	Posterior Glandular Tissue Included	90%	94%	77%
	Nipple in Profile	89%	92%	88%
	Skin or fat folds	53%	62%	15%
	Upper Location	25%	27%	-
	Lower Location	35%	45%	-
	Visualization of Inframammary Fold	81%	85%	49%
	Requires More Than One View	13%	17%	-

MAMMOGRAPHY EDUCATORS

Source: American Journal of Roentgenology: 209, December 2017

36

Reasonable Expectations

- Our patients have different and often challenging body habitus
- Their breast size, shape, mobility and tenderness are hugely variable

MAMMOGRAPHY EDUCATORS

37

Reasonable Expectations

Even the “perfect” patient, in terms of body habitus, breast mobility, etc. may provide a challenge that inhibits the technologist’s ability to position and compress properly.

MAMMOGRAPHY EDUCATORS

38





MAMMOGRAPHY EDUCATORS

39



MAMMOGRAPHY EDUCATORS

40



MAMMOGRAPHY EDUCATORS

41

But regardless of these variables, we CAN improve image quality by ***using standardized positioning techniques*** *and* developing a strong knowledge-based foundation that depends on the technologist's understanding of correlative anatomy.

MAMMOGRAPHY EDUCATORS

42

RCC: Steps 1-9 (Front)



MAMMOGRAPHY EDUCATORS

43

Quick Steps for the CC (Left)

___ 1. Elevate breast/IMF (until the PNL is perpendicular to the chest wall)
___ 2. Adjust IR height (so top edge is parallel with elevated IMF)
___ 3. Pull the breast onto the IR with both hands (left hand on top; right hand on bottom) and at the same time ask the patient to step forward into the machine (no leaning) and have them turn their face towards you
___ 4. Switch hands, so your right hand is on the top (palm down) and anchor the breast with the base of your right thumb.
___ 5. Lift the opposite/contralateral breast onto the IR with your left hand, palm facing up; then ask the patient to turn their right hip forward.
___ 6. Guide the patient's head forward and around the face shield, if possible
___ 7. Place your left elbow and forearm at the mid thoracic region (where their bra clasp would be) and gently push the patient forward
___ 8. Relax patient's left shoulder with your left hand, if possible
___ 9. Pull superior breast tissue forward by placing the base/edge of your right thumb on top of the breast against the chest wall, then apply compression while continuing to "push" the patient forward

MAMMOGRAPHY EDUCATORS

Source: Mammography Educators

44

RMLO: Steps 1-10



MAMMOGRAPHY EDUCATORS

45

Quick Steps for the MLO (Left)

___ 1. Stand perpendicular to the patient with your sternum pressing against patient's right humerus
___ 2. Lift patient's left shoulder/arm up over the corner of the IR with your right hand in the patient's axilla. At the same time, your right hand should "meet" your left hand in the axilla and help to lift the patient's left shoulder up and over the IR
___ 3. IR is placed in back of axilla (just interior to latissimus dorsi)
___ 4. Patient's left hand should be resting on bar, with their elbow bent behind the IR
___ 5. Place your left hand on patient's left shoulder (if possible) to keep their shoulder relaxed and down
___ 6. Your right hand, with palm facing up, slides down lateral side of the breast to pull on lateral breast tissue and smooth out any skin folds
___ 7. Once your right hand is at the bottom of the breast, turn your hand over so that your hand is now palm down on the breast with the base of your thumb just anterior to the IMF
___ 8. Push the breast up and out with the base of your thumb, keeping continuous contact with the breast
___ 9. At the same, ask the patient to lift and flatten their other breast, as needed
___ 10. Continue to hold the breast in the up and out position until compression is complete

MAMMOGRAPHY EDUCATORS

Source: Mammography Educators

46

Does it work??

MAMMOGRAPHY EDUCATORS

47

BEFORE **STANDARDIZED POSITIONING** **AFTER**
13.6 cm **+ 3.0 cm** **16.6 cm**

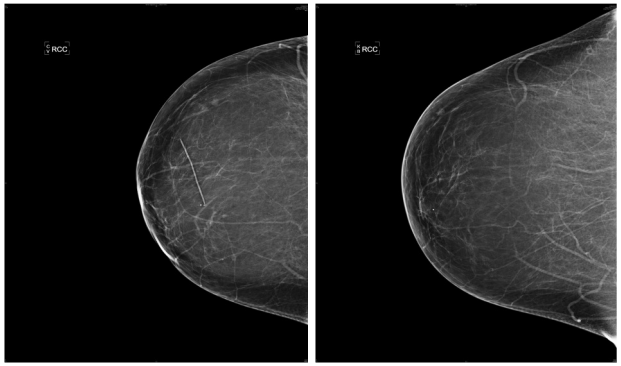

MAMMOGRAPHY EDUCATORS

48

BEFORE
14.8 cm

STANDARDIZED POSITIONING
+ 2.0 cm

AFTER
16.8 cm

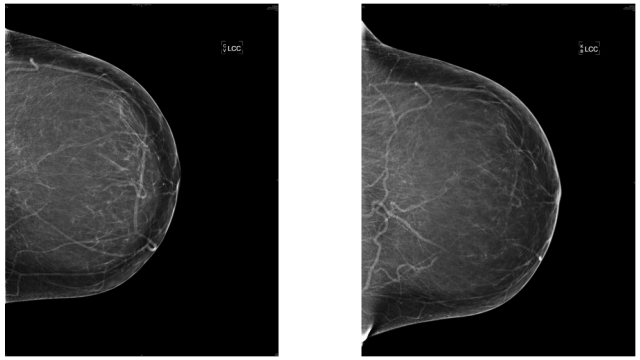

MAMMOGRAPHY EDUCATORS

49

BEFORE
13.9 cm

STANDARDIZED POSITIONING
+ 0.7 cm

AFTER
14.6 cm

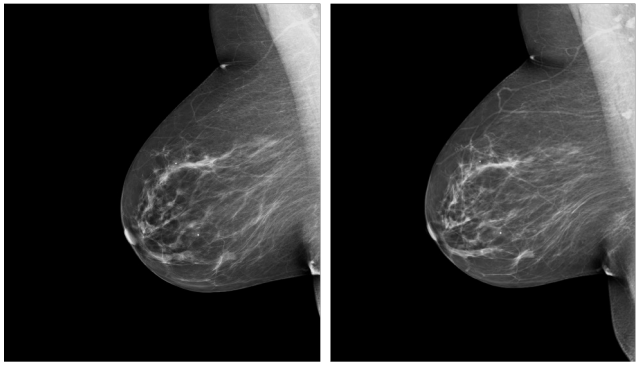

MAMMOGRAPHY EDUCATORS

50

BEFORE
11.8 cm

STANDARDIZED POSITIONING
+ 1.0 cm

AFTER
12.8 cm

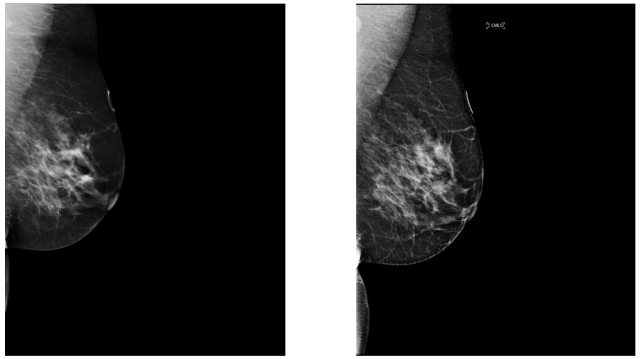

MAMMOGRAPHY EDUCATORS

51

Consistency and Reproducibility

Different techs – Different years – Miller Method

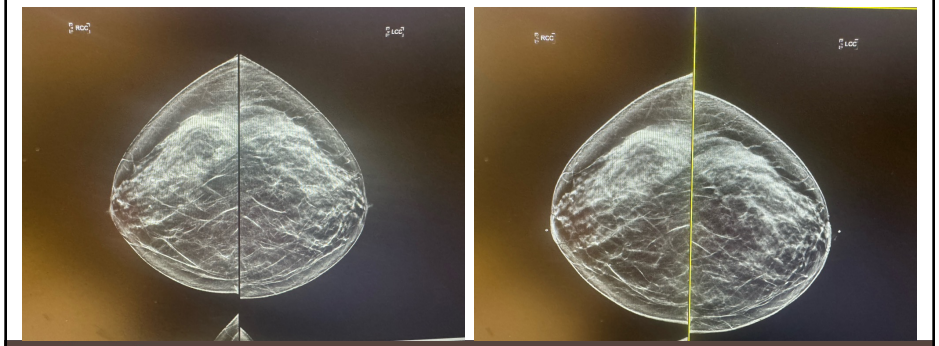

MAMMOGRAPHY EDUCATORS

52

Consistency and Reproducibility

Different techs – Different years – Miller Method

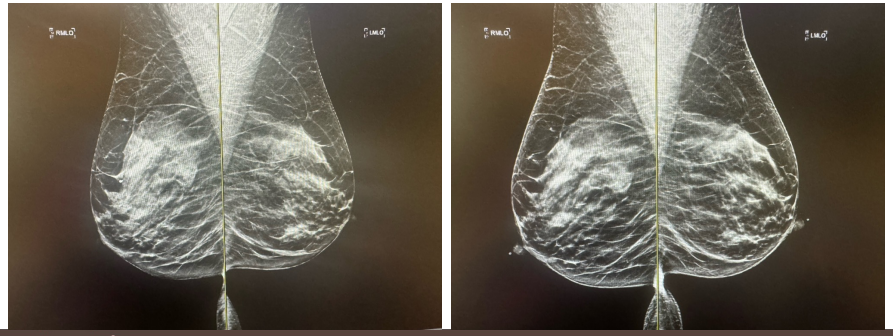

MAMMOGRAPHY EDUCATORS

53



MAMMOGRAPHY EDUCATORS

54

It is ALL our responsibility to make sure that ALL patients receive the highest quality mammogram achievable.

MAMMOGRAPHY EDUCATORS

55

Back To The Basics



MAMMOGRAPHY EDUCATORS

56

Mammography should be taught according to scientific principle, NOT ANECDOTE!

MAMMOGRAPHY EDUCATORS

57

Anecdote vs. Science



MAMMOGRAPHY EDUCATORS

58

Anecdote vs. **Science**



MAMMOGRAPHY EDUCATORS

59

SCIENCE:

ANATOMY – PHYSIOLOGY – PHYSICS

MAMMOGRAPHY EDUCATORS

60

You lucked out…



MAMMOGRAPHY EDUCATORS

61

Except…

- Newton's Third Law: for every action there is reaction
- Law of gravity



MAMMOGRAPHY EDUCATORS

62

Anatomy and Physiology

As they relate to mammography positioning, using general radiology principles…

MAMMOGRAPHY EDUCATORS

63

Goals for **General Radiology** Positioning

- Bring the body part back to its true anatomical position OR the position that will best visualize the body part
- Use palpable and visible anatomical landmarks for positioning and clinical image evaluation
- Use consistent and reproducible methods

MAMMOGRAPHY EDUCATORS

64

Goals for **Mammography** Positioning

Bring the breast back to its natural anatomical position (*with the nipple perpendicular to the chest wall as possible*) on both screening views to maximize visualization of breast tissue and to avoid superimposition of structures.

MAMMOGRAPHY EDUCATORS

65

Anatomy of the Breast

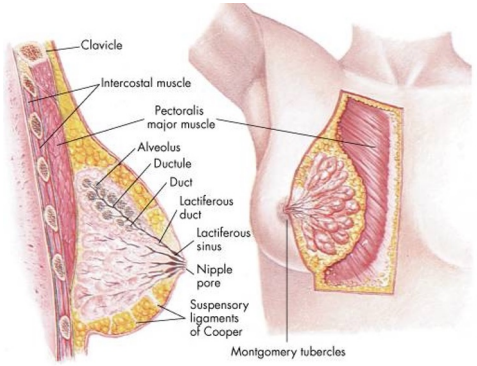

MAMMOGRAPHY EDUCATORS

66

Normal or natural position of the breast is when the nipple is perpendicular to the chest wall.

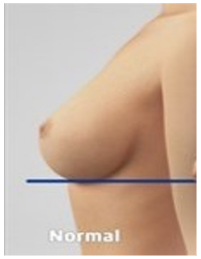

MAMMOGRAPHY EDUCATORS

67

When positioning for mammography we need to bring the breast back to its 'normal' position.

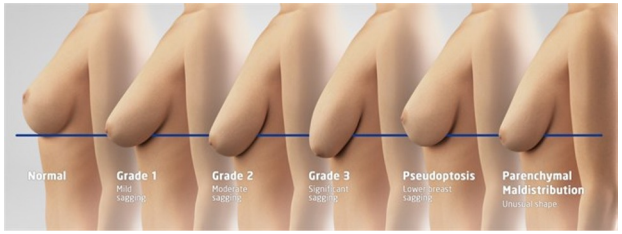

MAMMOGRAPHY EDUCATORS

68

In order to accomplish this and include the maximum amount of breast tissue, we must consider the anatomical landmarks that will be used for positioning and clinical image analysis.

MAMMOGRAPHY EDUCATORS

69

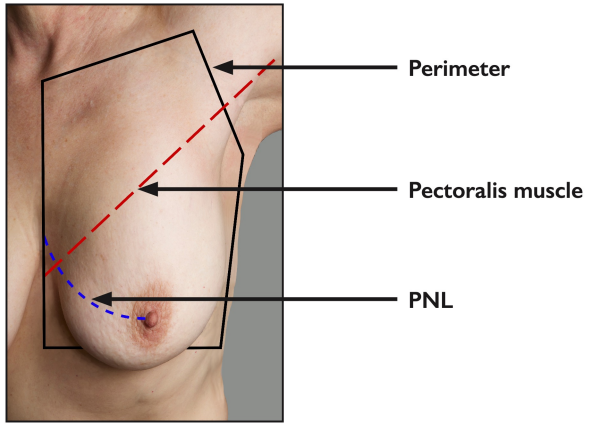

MAMMOGRAPHY EDUCATORS

70

Perimeter of the Breast

MAMMOGRAPHY EDUCATORS

71

Perimeter Used for Positioning and Clinical Image Analysis

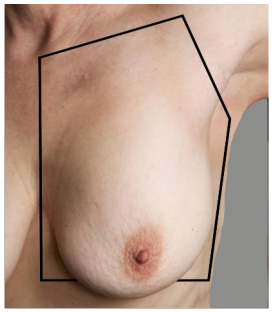

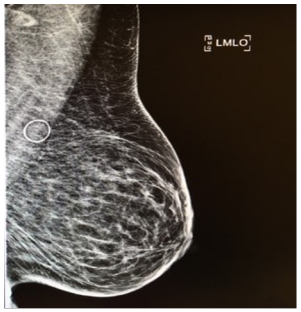

MAMMOGRAPHY EDUCATORS

72

Pectoralis Used for Positioning and Clinical Image Analysis

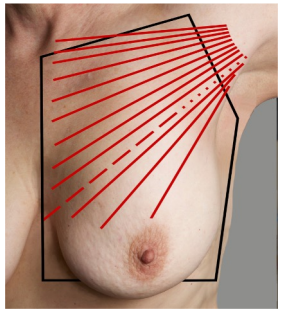

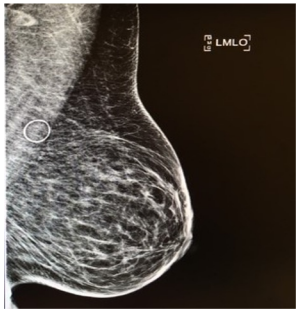

MAMMOGRAPHY EDUCATORS

73

PNL Used for Positioning

Elevate the breast so that the PNL is as close as possible to perpendicular to the chest wall.



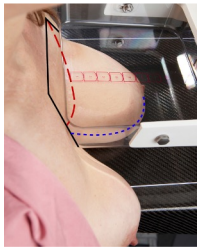

MAMMOGRAPHY EDUCATORS

74

PNL Used for Clinical Image Analysis

PNL measurement of CC should be within 1cm of the PNL measurement on the MLO.

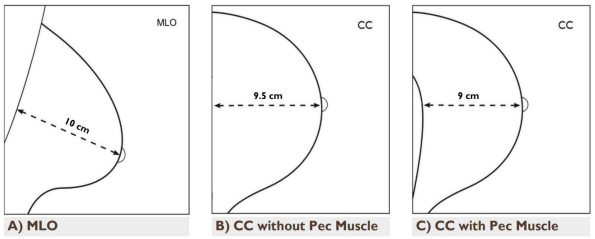

MAMMOGRAPHY EDUCATORS

75

The MLO

- Inclusion of all breast tissue within perimeter
- Pectoral muscle fully visualized
- Tissue well separated
- Tissue visualized back to the retromammary fat space
- IMF

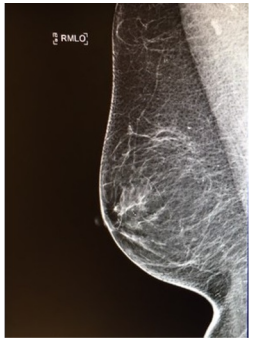

MAMMOGRAPHY EDUCATORS

76

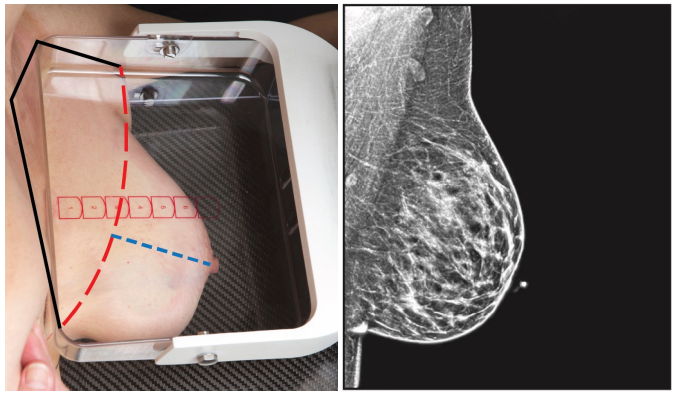

77

The MLO

Visualization of the pectoral muscle:

- The pectoralis muscle is not really part of the breast
- However, it serves as an important anatomical landmark for positioning and image evaluation

78

The absence or presence of these characteristics will tell you exactly what you did right or wrong when positioning and therefore, whether you included or excluded breast tissue!

79

Remember

There are only two margins for error:

1) The way the **machine** is set up (i.e., height, angle, compression paddle size, etc.)
2) The way the **patient** is "set up": both feet, hips, and shoulders facing forward

80

The MLO

- **Width:** wide margin at the top
- **Length:** down to the level of the PNL
- **Shape:** convex/straight

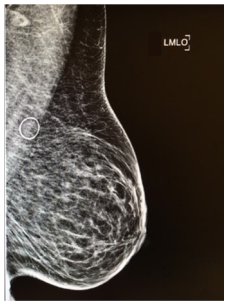

MAMMOGRAPHY EDUCATORS

81

The MLO

WIDTH of the Muscle

There should be a wide margin of the pectoralis muscle at the top of the image (in the axilla).



MAMMOGRAPHY EDUCATORS

82

The MLO

EQUIPMENT: Width of the muscle is related to the placement of the IR in the axilla.

The back corner of the IR should be placed just anterior to the latissimus dorsi.

MAMMOGRAPHY EDUCATORS

83



MAMMOGRAPHY EDUCATORS

84

The MLO

PATIENT: Width of the muscle is related to the position of the patient.

The patient must be turned into the machine with both feet, hips and shoulders as far forward as possible. The patient's shoulder should be down and relaxed and if possible, held in position by the technologist.

MAMMOGRAPHY EDUCATORS

85



MAMMOGRAPHY EDUCATORS

86

Width of the Muscle

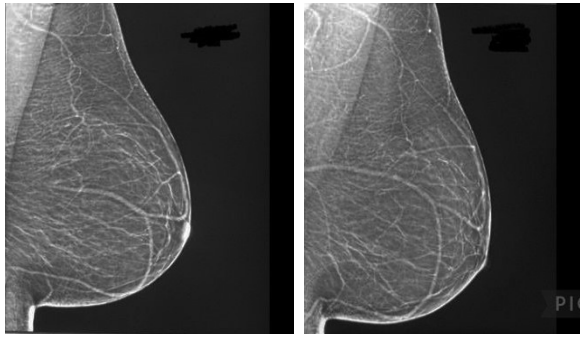

MAMMOGRAPHY EDUCATORS

87

The MLO

LENGTH of the Muscle

Should be visualized down to the level of the PNL.

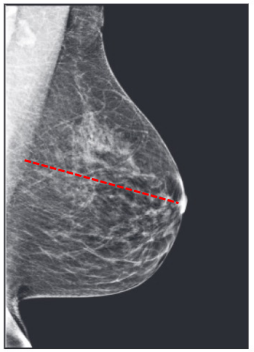

MAMMOGRAPHY EDUCATORS

88

The MLO

EQUIPMENT: Angle for the MLO

- Angle to the free margin of the pectoralis muscle
- Keep angulation consistent
- Steeper angle for patients with longer thoraxes and small breasts
- Lesser angles for shorter thoraxes and larger breasts

Proper degree of angulation

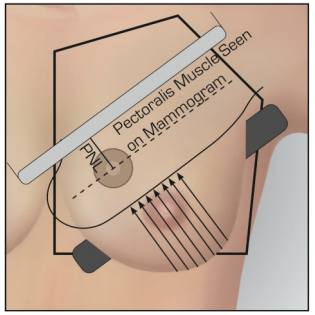

Angle too steep

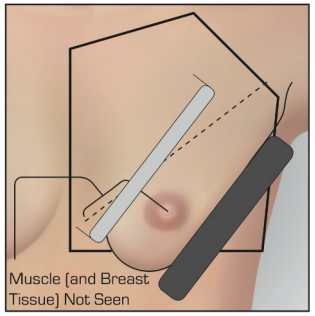

Recommended Angulation for the MLO

- Depends on body habitus
- Maintain consistency from year to year*

*An MLO angled at 56-degrees one year will look markedly different than an MLO angled at 42-degrees the next year.

Keep Angles Consistent

Use 5-degree increments – no more 43, 48, 52 degrees:

- 40 degrees for shorter, heavier patients with large breasts
- 45 degrees for average patients
- 50 degrees for tall, thinner patients with smaller breasts
- 35 degrees for patients who have undergone reduction

The MLO

PATIENT: Length of the muscle is related to the position of the patient.

The patient must be turned into the machine with both feet, hips and shoulders as far forward as possible, as not to impede the progress of the compression paddle.

MAMMOGRAPHY EDUCATORS

93

Proper degree of angulation

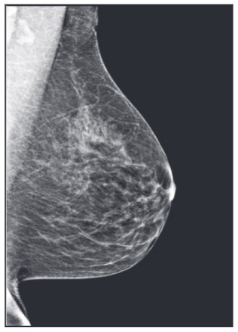

Angle too steep

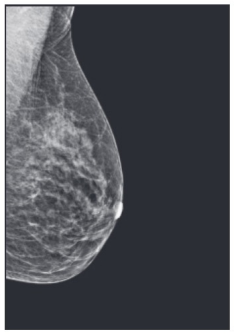

MAMMOGRAPHY EDUCATORS

94

OR…
The patient is not facing the machine properly.

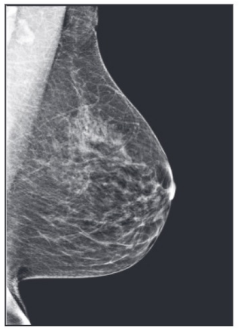

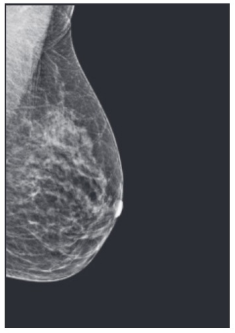

MAMMOGRAPHY EDUCATORS

95

The MLO

SHAPE of the Muscle

The muscle should be convex or straight.

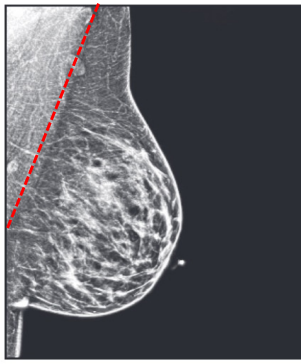

MAMMOGRAPHY EDUCATORS

96

The MLO

EQUIPMENT: The shape and opacity of the muscle is related to the height of the IR.

The top of the IR should be positioned at the height of the sternoclavicular joint or halfway between the top of the shoulder and the axillary crease.

MAMMOGRAPHY EDUCATORS

97

The MLO

PATIENT: The shape and opacity of the muscle is related to the relaxation of the pectoralis muscle.

Patient's shoulder, arm and hand must be relaxed with the elbow bent and relaxed behind the IR.

MAMMOGRAPHY EDUCATORS

98

Concave

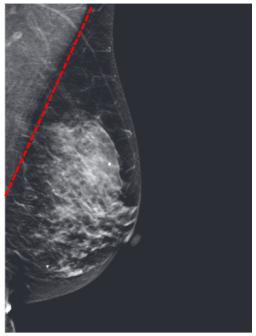

Convex

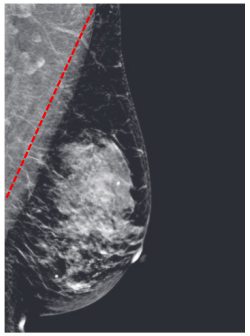

MAMMOGRAPHY EDUCATORS

99

The MLO

Common problems:

- No visualization of the IMF
- Breast drooping

MAMMOGRAPHY EDUCATORS

100

No IMF

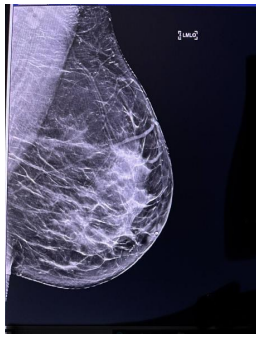

IMF



MAMMOGRAPHY EDUCATORS

101

Keep Angles Consistent

The position of the patient related to the bottom, front corner of the IR is critical.

- Patient must be facing forward with both feet also forward
- Lower, front corner of the IR should be directly below the patient's nipple or halfway between their ASIS and umbilicus
- This requires the patient taking a side step towards you

MAMMOGRAPHY EDUCATORS

102

Improper

Edge of IR in front of IMF

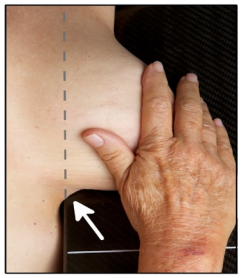

Proper

Edge of IR behind IMF



Top edge of IR indicated by vertical dotted line.

MAMMOGRAPHY EDUCATORS

103



MAMMOGRAPHY EDUCATORS

104

The “Sagging” Breast





MAMMOGRAPHY EDUCATORS

105

The “Sagging” Breast

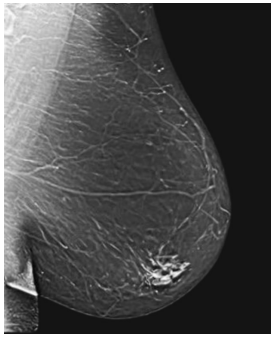



MAMMOGRAPHY EDUCATORS

106

The “Sagging” Breast





MAMMOGRAPHY EDUCATORS

107

The “Sagging” Breast

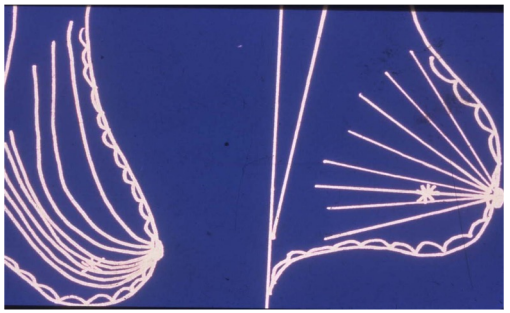

MAMMOGRAPHY EDUCATORS

108

Stages of Breast Cancer Development

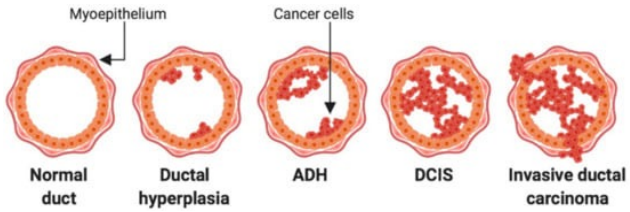

MAMMOGRAPHY EDUCATORS

109

Position of the Breast

- Breast must be held in the “up and out” position to bring the breast back to its “normal” position (nipple perpendicular to the chest wall)
- Maintained by adequate compression
- Don’t let go until compression is complete

MAMMOGRAPHY EDUCATORS

110

Solution for the “Sagging” Breast

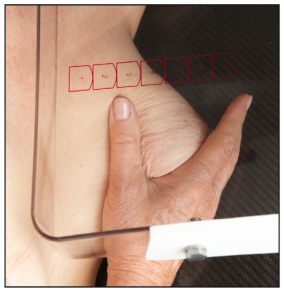

Hold the breast in up and out position.



Compress.

MAMMOGRAPHY EDUCATORS

111

The CC

- Include maximum amount of breast tissue in the axial/transverse plan
- Visualization of medial breast tissue
- Visualization of pectoralis muscle on approximately 50% of all CCs
- PNL within 1cm of PNL on MLO

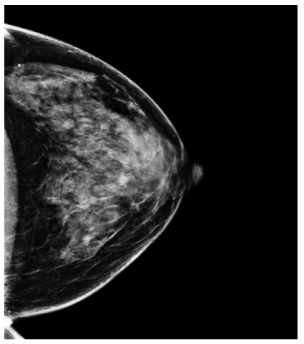

MAMMOGRAPHY EDUCATORS

112

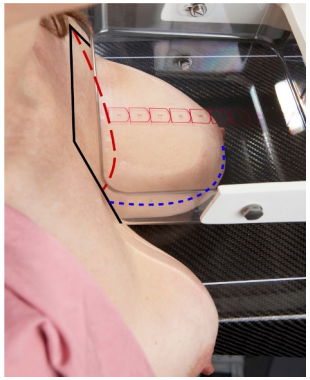

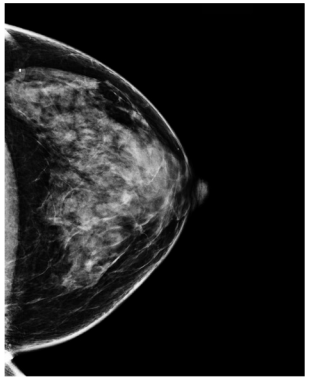

MAMMOGRAPHY EDUCATORS

113

The CC

- The CC is done to provide an “orthogonal” view from the MLO
- When added to the MLO, it increases breast cancer detection
- While the CC is not primarily done to visualize medial breast tissue (cleavage), it is a “by-product” of a good CC
- If you miss breast tissue on the MLO, it will be medial tissue, so it’s important to try to include that on the CC view

MAMMOGRAPHY EDUCATORS

114

The CC: **Is it the equipment or the patient?**

Equipment:

- IR too high or too low
- Compression paddle size

Patient:

- Facing towards the machine with both feet, hips and shoulders forward

MAMMOGRAPHY EDUCATORS

115

Due to lack of anatomical landmarks, positioning techniques are extremely important!!

MAMMOGRAPHY EDUCATORS

116

The CC

Common problems:

- Short CC (PNL measurement on CC is less than 1 cm of PNL measurement on the MLO)
- No pec muscle (remember the 50% rule!)
- No visualization of deep medial breast tissue (cleavage)

All of these are most often related to positioning technique vs. equipment and patient position. (Although they are still important!)

MAMMOGRAPHY EDUCATORS

117



MAMMOGRAPHY EDUCATORS

118

Meet, Beat, **Repeat**



Year 1

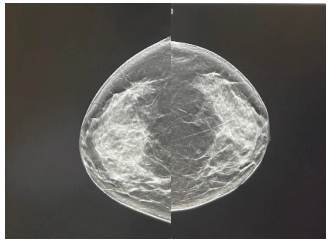

Year 2

MAMMOGRAPHY EDUCATORS

119

Focus On…

- Consistency
- Reproducibility
- Efficiency
- Proficiency
- Ergonomic principles

MAMMOGRAPHY EDUCATORS

120

Mammography Saves Lives!

But it is up to you…….

Even the best radiologist, in the best breast center cannot diagnose a cancer that is not included on the image.

MAMMOGRAPHY EDUCATORS

121

We hold their lives in our hands.



MAMMOGRAPHY EDUCATORS

122

Additional Mammographic Views

Presented by:
Millie Castellanos, B.S., R.T.(R)(M)(ARRT)(CRT)
Director of Education, Mammography Educators

Content created by:
Louise Miller, R.T.(R)(M)(ARRT), CRT(M), FSBI, FNCBC

MAMMOGRAPHY EDUCATORS

© 2026 Mammography Educators

123

Most Commonly Used Additional Views Lexicon

- XCCL – Exaggerated Craniocaudal Lateral
- CV – Cleavage
- LM – Lateromedial
- ML – Mediolateral

MAMMOGRAPHY EDUCATORS

124

Most Commonly Used Additional Views Lexicon

- M – Magnification
- ID – Implant Displaced
- *No label:* Spot Compression

Labeling Codes (Lexicon)

The name is the view (labeling code), always preceded by identification of laterality:

- i.e., LXCCL or RXCCL

Most Commonly Used Additional Views

- XCCL
- CV
- LM/ML

Why We Do Additional Views

- To show a specific component of the anatomy not seen on standard views
- To provide localization of an area of concern medial/lateral or superior/inferior to the nipple

Or…

- To show an area of concern in better details
- To counteract superimposition of structures
- To triangulate a lesion

MAMMOGRAPHY EDUCATORS

129

Commonly used additional views are done to show a specific component of the anatomy not seen on standard views.

MAMMOGRAPHY EDUCATORS

130

Ask and Answer

- Which part of the breast do I want to visualize?
- In which projection?
- Which view will accomplish this?

MAMMOGRAPHY EDUCATORS

131

Imaging the Breast in a Transverse or Axial Plane

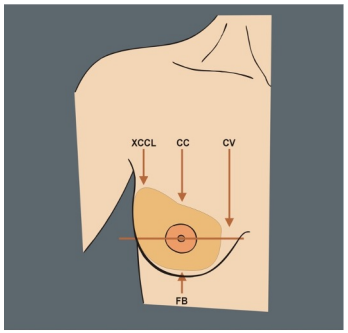

MAMMOGRAPHY EDUCATORS

132

XCCL – Exaggerated Craniocaudal Lateral

Visualization of lateral breast tissue in a CC projection.

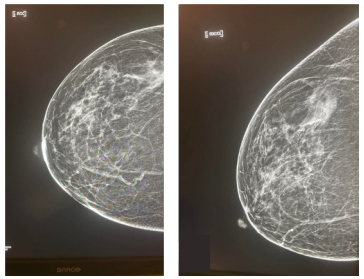

MAMMOGRAPHY EDUCATORS

133

Use of the XCCL

- Should be used on a ***baseline*** exam when lateral posterior breast tissue is missing on the CC view
- If glandular breast tissue on subsequent screening views is visualized back to the retromammary fat space on the MLO, an XCCL is not needed

MAMMOGRAPHY EDUCATORS

134

XCCL is required for baseline, but not on subsequent screenings.

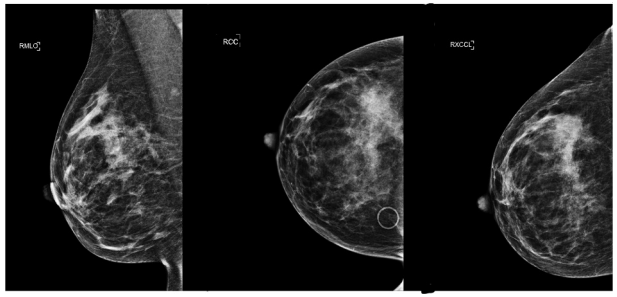

MAMMOGRAPHY EDUCATORS

135

Use of the XCCL

- Should be performed on less than 10% of all patients
- Performed at 0-degree angulation
- Patient's body should be at 45-degree angle to IR
- Nipple should be pointing towards the upper corner of the image receptor (IR)

MAMMOGRAPHY EDUCATORS

136

Muscle or no muscle?

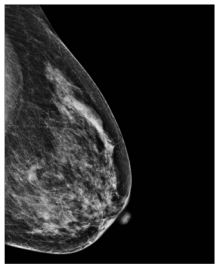

NO MUSCLE!

MAMMOGRAPHY EDUCATORS

137

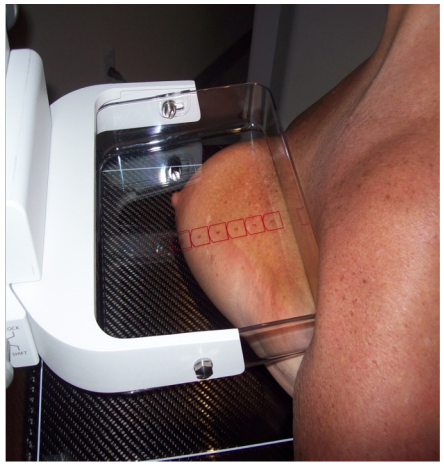

MAMMOGRAPHY EDUCATORS

138

Incorrect



Correct



MAMMOGRAPHY EDUCATORS

139

CV – Cleavage

Used for visualization of medial breast tissue in a CC view.

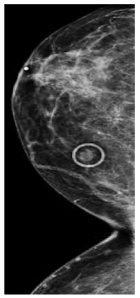

MAMMOGRAPHY EDUCATORS

140



141

Superior or Inferior Orientation to the Nipple (LM or ML)

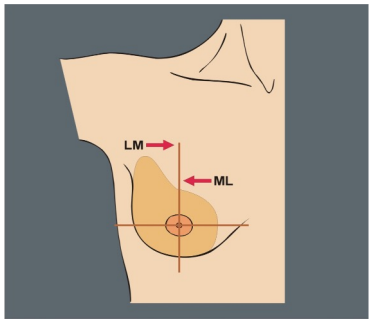

142

90-Degree (True) Lateral

- LM – Lateromedial
- ML – Mediolateral

143

Use of the Lateral

- Shows effects of gravity on air fluid levels (milk of calcium)
- Used as a “tie breaker” view (to overcome superimposition of structure)
- Visualizes the breast in the sagittal plane (demonstrates an AOC superior or inferior to the nipple)

144

Why do the LM?

When you did the MLO, you showed the lateral breast in better detail; The LM…

- Shows the medial breast in better detail
- Takes advantage of the lateral mobile border of the breast, thus facilitates positioning

MAMMOGRAPHY EDUCATORS

145

Why do the LM?

- The posterior medial breast is hardest part of the breast to image and the area most often missed on the MLO.
- If done properly, by off-setting the IR into the contralateral breast, you will be able to go deeper against the chest wall.
- There is no issue of the contralateral breast impeding the path of the compression paddle.

MAMMOGRAPHY EDUCATORS

146

Improperly positioned LM with breasts separated, so the middle of the IR is centered on midsternal line. This excludes deep medial breast tissue on the side you are imaging.

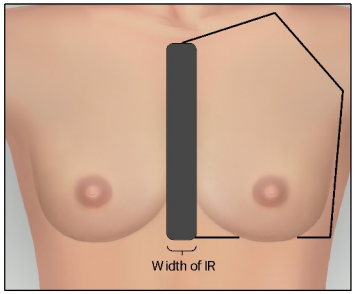

MAMMOGRAPHY EDUCATORS

147

Properly positioned LM with breasts separated, so the top edge of the IR is centered on midsternal line and the width of the IR is pressing against the contralateral breast.

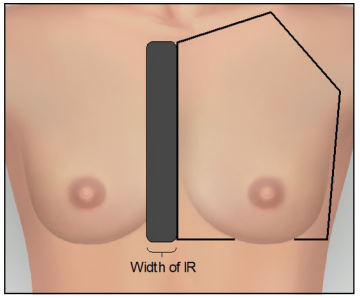

MAMMOGRAPHY EDUCATORS

148

LM – Front View



MAMMOGRAPHY EDUCATORS

149

LM – Back View



MAMMOGRAPHY EDUCATORS

150

ML – Mediolateral

The opposite breast must be pulled back to allow the compression paddle to pass and may therefore eliminate visualization of deep medial breast tissue.

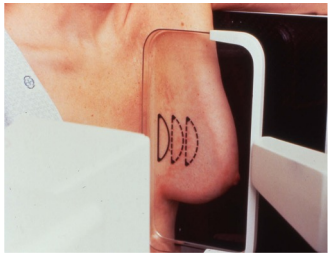

MAMMOGRAPHY EDUCATORS

151

Additional Views for Clarification of Area of Concern (AOC)

- Spot Compression
- Spot Compression with Magnification

MAMMOGRAPHY EDUCATORS

152

Spot Compression Paddles



MAMMOGRAPHY EDUCATORS

Image Courtesy of Robyn Hadley, R.T.(R)(M)

153

Square vs. Round Paddle

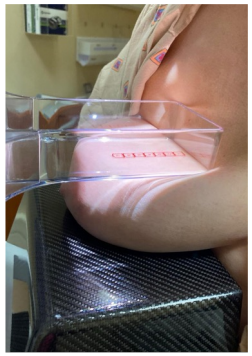

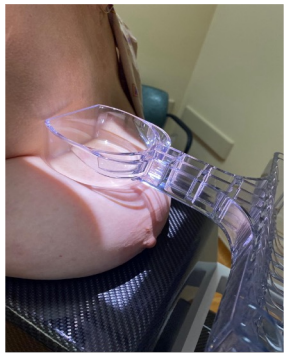

MAMMOGRAPHY EDUCATORS

Image Courtesy of Robyn Hadley, R.T.(R)(M)

154

Spot Compression with Magnification



MAMMOGRAPHY EDUCATORS

Image Courtesy of Robyn Hadley, R.T.(R)(M)

155

Square vs. Round Paddle

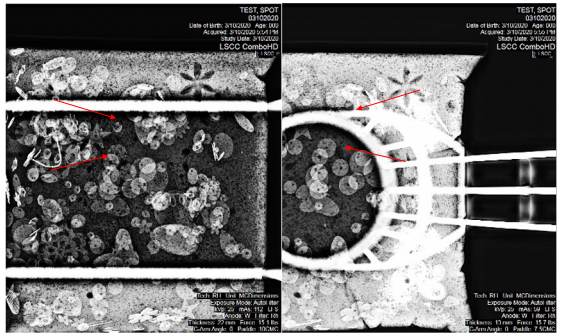

MAMMOGRAPHY EDUCATORS

Image Courtesy of Robyn Hadley, R.T.(R)(M)

156

Imaging of Augmented Breasts

- CC views of each breast with implants in place
- MLO views of each breast with implants in place
- CCID views of each breast with implant displaced
- MLOID views of each breast with implant displaced

MAMMOGRAPHY EDUCATORS

157

Imaging of Augmented Breasts

Full implant views:

- Should be done with only enough compression to immobilize the breast to prevent motion unsharpness
- Curved paddle can be used, if available
- Appropriate technique (usually manual) should be used

MAMMOGRAPHY EDUCATORS

158

Imaging of Augmented Breasts

ID views:

- Depending on implant mobility, can be performed with taut compression
- Half paddle can be used for patients with small amount of natural breast tissue
- Appropriate techniques (patients without implants) should be used
- Patient can be positioned from behind (tech standing and/or patient seated)

MAMMOGRAPHY EDUCATORS

159

Half Paddle





MAMMOGRAPHY EDUCATORS

Image Courtesy of Robyn Hadley, R.T.(R)(M)

160

Imaging of Augmented Breasts

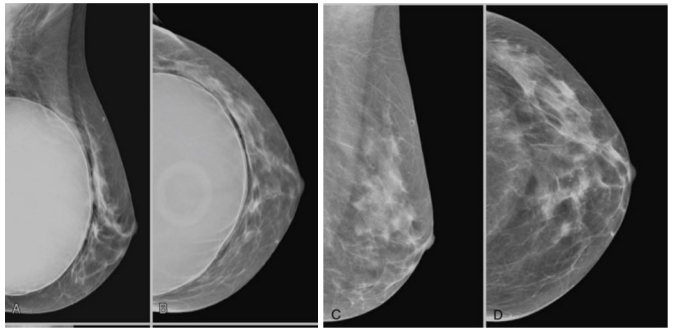

MAMMOGRAPHY EDUCATORS

161

Working from Behind for CCID Views



MAMMOGRAPHY EDUCATORS

162

Working from Behind for MLOID Views



MAMMOGRAPHY EDUCATORS

163

Conclusion

Additional views:

- Helpful in identifying true location of areas of concern
- Used for diagnostic workups
- Can provide valuable information to aid in diagnosis of breast cancer

MAMMOGRAPHY EDUCATORS

164

Challenging Patients and Situations in Mammography

Presented by:
Millie Castellanos, B.S., R.T.(R)(M)(ARRT)(CRT)
Director of Education, Mammography Educators

Content created by:
Louise Miller, R.T.(R)(M)(ARRT), CRT(M), FSBI, FNCBC

© 2026 Mammography Educators





Challenging Patients

- Patient circumstances
- Body habitus issues
- Special needs

Challenging Patients

- **Patient circumstances**
- Body habitus issues
- Special needs



MAMMOGRAPHY EDUCATORS

169

Variable Patient Circumstances

- Mobility
- Limitations
- Breast size



MAMMOGRAPHY EDUCATORS

170

Variable Patient Circumstances

- **Mobility**
- Limitations
- Breast size



MAMMOGRAPHY EDUCATORS

171

Mobility

- Wheelchairs
- Walkers
- Scooters



MAMMOGRAPHY EDUCATORS

172

Mobility

- **Wheelchairs**
- Walkers
- Scooters

MAMMOGRAPHY EDUCATORS

173



MAMMOGRAPHY EDUCATORS

174

Wheelchair Patients

- Get her to sit up as straight as possible in the chair
- Have her sit as far forward in the chair as possible (use pillows to "bolster" her)
- Remove the arms from the chair
- Turn the wheelchair at a 45-degree angle away from the IR

MAMMOGRAPHY EDUCATORS

175

Turn the wheelchair at a 45-degree angle away from the IR.



MAMMOGRAPHY EDUCATORS

176

Mobility

- Wheelchairs
- **Walkers**
- Scooters

MAMMOGRAPHY EDUCATORS

177





MAMMOGRAPHY EDUCATORS

178

Patients with Walkers

- Assess stability
- Get her to sit up as straight as possible in the chair
- Have her sit as far forward in the chair as possible (use pillows to “bolster” her)
- Move foot pedals out of the way

MAMMOGRAPHY EDUCATORS

179

Mobility

- When in doubt, the patient should be seated!
- Be very cautious of stools with wheels
- Override automatic compression release
- Let them hang on
- Get assistance
- Accurately assess stability

MAMMOGRAPHY EDUCATORS

180

Assessing Stability

Ask them if they do things in their “real life” that requires similar ability:

- “Can you get in and out of bed on your own?”
- “Do you get to the bathroom without help?”

MAMMOGRAPHY EDUCATORS

181

Reduce Fall Risk







MAMMOGRAPHY EDUCATORS

182

Don’t Just Ask: “Can you stand?”

Mammography requires:

- Balance
- Stability
- ROM

MAMMOGRAPHY EDUCATORS

183

Mobility

- Wheelchairs
- Walkers
- **Scooters**

MAMMOGRAPHY EDUCATORS

184

Let Her Drive Herself to Where You Need Her to Be!



MAMMOGRAPHY EDUCATORS

185

Variable Patient Circumstances

- Mobility
- **Limitations**
- Breast size

MAMMOGRAPHY EDUCATORS

186

Limitations

- Limited ROM - neck, shoulder, arm, etc.
- Full or partial paralysis

MAMMOGRAPHY EDUCATORS

187

Limited ROM: Full or Partial Paralysis

- Mostly does not affect CC
- If you can't do a MLO… do a LM or ML
- For visualization of UOQ, do slightly angled AT

MAMMOGRAPHY EDUCATORS

188

Variable Patient Circumstances

- Mobility
- Limitations
- **Breast size**

189

Breast Size

- Extremely large
- Extremely small

190

Extremely Large Breasts



191

Extremely Large Breasts: Challenges

- Volume of breast tissue
- Weight of the breast
- Limited size of IR
- Increased probability of stretching/tearing of the skin (especially in IMF)
- Protruding abdomen

192

Extremely Large Breasts: Tips

- Perform a high and low MLO, if needed
- Do an anterior compression view, if needed
- To help increase visibility of the IMF, have the patient lift and flatten her contralateral breast

MAMMOGRAPHY EDUCATORS

193

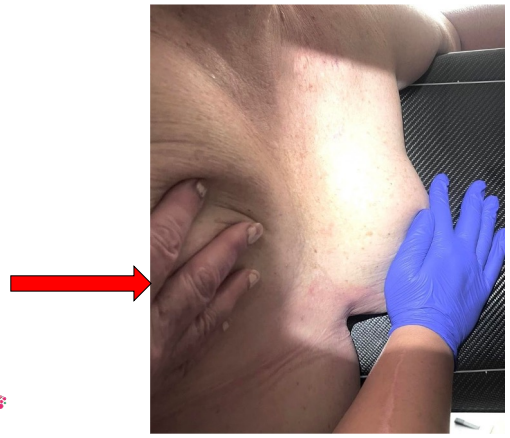

MAMMOGRAPHY EDUCATORS

194

Extremely Large Breasts: Tips

- Hold the breast up higher than you think you need
- Make sure it is held up *and* out
- **Don't let go** until compression is complete

MAMMOGRAPHY EDUCATORS

195

Holding the Breast in the Up and Out Position Until Compression is Complete





MAMMOGRAPHY EDUCATORS

196

Extremely Large Breasts: Challenges

Biggest challenge is that multiple images have to be used and then “piece” them together, making sure that breast tissue was not “missed”:

- “Mosaic” or “tile” the breast in segments
- Use “marker” to designate overlap

MAMMOGRAPHY EDUCATORS

197

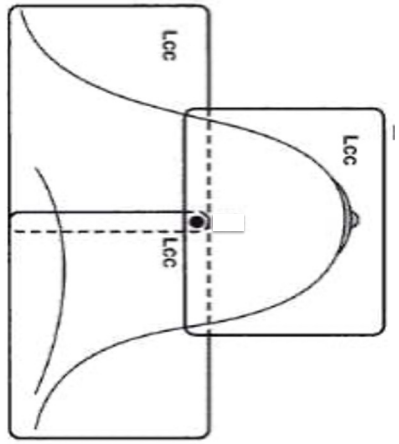

MAMMOGRAPHY EDUCATORS

198

Extremely Small Breasts



MAMMOGRAPHY EDUCATORS

199





MAMMOGRAPHY EDUCATORS

200

Use the Half (Implant) Paddle



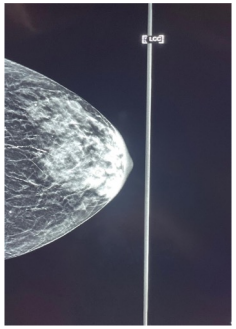

MAMMOGRAPHY EDUCATORS

201

Position From Behind the Patient

- Use the implant displacement techniques
- Position from behind the patient*
- Have the patient seated

** If positioning from behind the patient, it is imperative that you explain the process to assure her comfort level.*

MAMMOGRAPHY EDUCATORS

202







MAMMOGRAPHY EDUCATORS

203

Challenging Patients

- Patient circumstances
- **Body habitus issues**
- Special needs

MAMMOGRAPHY EDUCATORS

204

Body Habitus Issues

- Pectus carinatum
- Pectus excavatum
- Kyphosis
- Lordosis
- Scoliosis

MAMMOGRAPHY EDUCATORS

205

Body Habitus Issues

- **Pectus carinatum**
- Pectus excavatum
- Kyphosis
- Lordosis
- Scoliosis

MAMMOGRAPHY EDUCATORS

206

Pectus Carinatum

- Also called **pigeon chest**
- A deformity of the chest characterized by a protrusion of the sternum and ribs
- More common in males than females (4:1 ratio)

Hint: Carrions (birds that eat meat)

MAMMOGRAPHY EDUCATORS

207

Carrions






MAMMOGRAPHY EDUCATORS

208

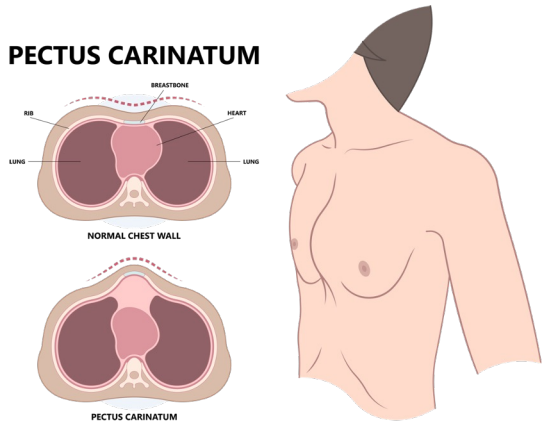

209

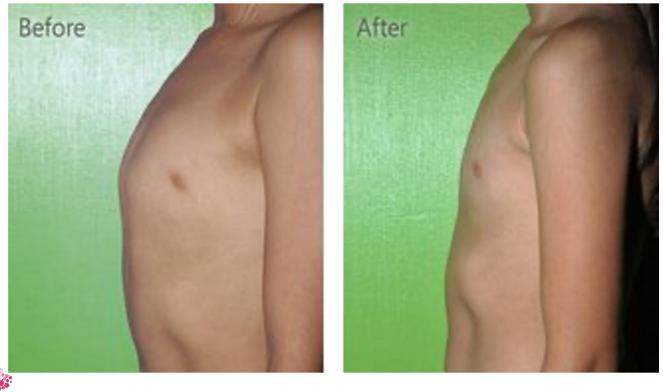

210

Body Habitus Issues

- Pectus carinatum
- **Pectus excavatum**
- Kyphosis
- Lordosis
- Scoliosis

211

Pectus Excavatum

- Also called **funnel chest**
- A deformity of the chest characterized by an indentation of the sternum accompanied by a protrusion of the ribs
- More common in males than females (3:1 ratio)

Hint: Excavate, cave

212

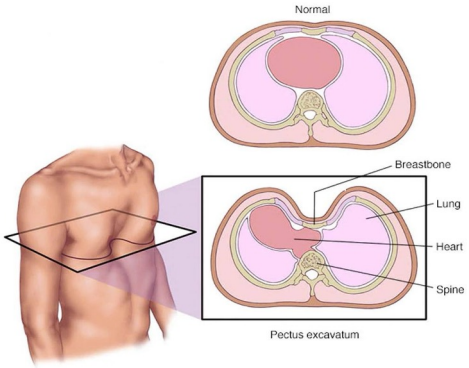

© MAYO FOUNDATION FOR MEDICAL EDUCATION AND RESEARCH. ALL RIGHTS RESERVED

213




214

Pectus Carinatum / Pectus Excavatum

- Try standard views
- “Chevron” the CCs: XCCL and CV, as needed
- LM as additional view (slightly angle the top of the IR away from breast being imaged, if needed)

215

Body Habitus Issues

- Pectus carinatum
- Pectus excavatum
- **Kyphosis**
- **Lordosis**
- **Scoliosis**

216

Conditions of the Spine

- Kyphosis: Curvature of the thoracic spine
- Lordosis: Curvature of the lumbar spine
- Scoliosis: Lateral curvature of the spine

Kyphosis Lordosis Scoliosis

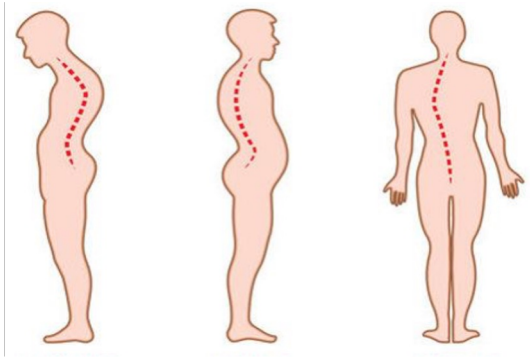

Body Habitus Issues

- Pectus carinatum
- Pectus excavatum
- **Kyphosis**
- **Lordosis**
- Scoliosis

Positioning for Patients with Kyphosis/Lordosis

Attempt the standard views first, then add views as needed:

- "Lordotic" CC
- LM
- Use tips recommended for pectus issues (angled LM, "chevroned" CCs)

Body Habitus Issues

- Pectus carinatum
- Pectus excavatum
- Kyphosis
- Lordosis
- **Scoliosis**

MAMMOGRAPHY EDUCATORS

221

Scoliosis



MAMMOGRAPHY EDUCATORS

222

Scoliosis

- CCs should not be affected
- Two different degrees of angulation for the MLOs may be needed

MAMMOGRAPHY EDUCATORS

223

KISS*



MAMMOGRAPHY EDUCATORS

224

Keep It Simple Sister!

- I attempt the standard views first
- Get “creative” as needed



MAMMOGRAPHY EDUCATORS

225

My Favorite Go-To View?!



MAMMOGRAPHY EDUCATORS

226

Challenging Patients

- Patient circumstances
- Body habitus issues
- **Special needs**

MAMMOGRAPHY EDUCATORS

227

Special Needs

- Alzheimer's
- Dementia
- Overly medicated
- Elderly, infirm
- Confused
- Developmentally disabled

MAMMOGRAPHY EDUCATORS

228

Special Needs

- Seek assistance of caretaker
- Let them stay in the room
- Speak slowly and clearly
- Use terminology they can understand
- Find solutions for recurring problems

MAMMOGRAPHY EDUCATORS

229

Special Needs



MAMMOGRAPHY EDUCATORS

230

DO YOUR BEST……..

MAMMOGRAPHY EDUCATORS

231

No Matter the Limitations…

Document… Document… Document!

- Use appropriate terminology
- Keep it concise
- Be consistent

MAMMOGRAPHY EDUCATORS

232

What NOT To Do



MAMMOGRAPHY EDUCATORS

233

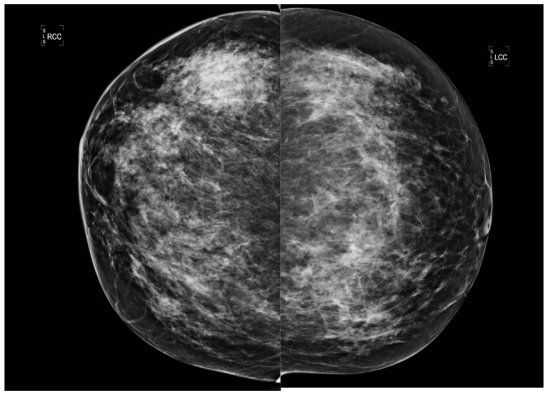

MAMMOGRAPHY EDUCATORS

234

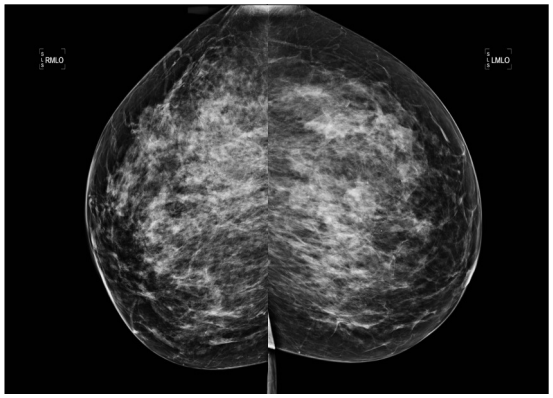

MAMMOGRAPHY EDUCATORS

235

No Magic Bullet



MAMMOGRAPHY EDUCATORS

236

Mission and Motivation

Presented by:
Millie Castellanos, B.S., R.T.(R)(M)(ARRT)(CRT)
Director of Education, Mammography Educators

Content created by:
Louise Miller, R.T.(R)(M)(ARRT), CRT(M), FSBI, FNCBC

© 2026 Mammography Educators

What's Changed?

- Cardboard cassette to Xerography
- Xerography to FS
- FS to FFDM
- FFDM to DBT

Cardboard Cassettes

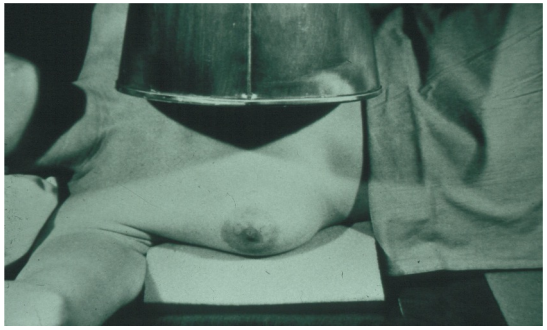

Xerography





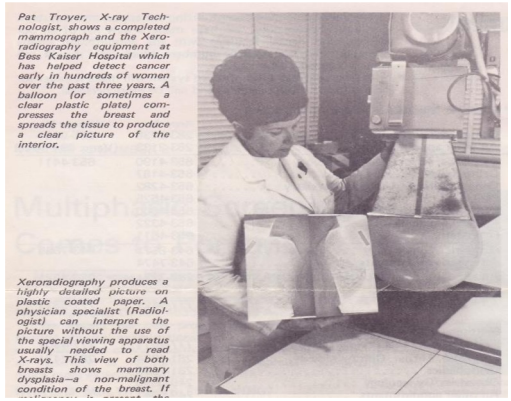

Pat Troyer, X-ray Technologist, shows a completed mammograph and the Xeroradiography equipment at Bess Kaiser Hospital which has helped detect cancer early in hundreds of women over the past three years. A balloon (or sometimes a clear plastic plate) compresses the breast and spreads the tissue to produce a clear picture of the interior.

Xeroradiography produces a highly detailed picture on plastic coated paper. A physician specialist (Radiologist) can interpret the picture without the use of the special viewing apparatus usually needed to read X-rays. This view of both breasts shows mammary dysplasia—a non-malignant condition of the breast. If

MAMMOGRAPHY EDUCATORS

241

Film/Screen vs. Xerox

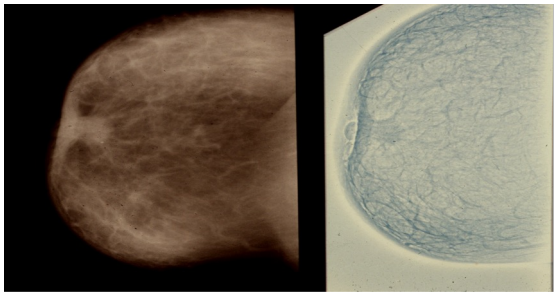

MAMMOGRAPHY EDUCATORS

242

Full Field Digital Mammography



MAMMOGRAPHY EDUCATORS

243

Digital Breast Tomosynthesis - DBT



MAMMOGRAPHY EDUCATORS

244

FS – FFDM – DBT

- Increased width in face shield
- Increased thickness and length of IR compared to the bucky

MAMMOGRAPHY EDUCATORS

245

The Use of AI



MAMMOGRAPHY EDUCATORS

246

Artificial Intelligence for Image Evaluation

- Uses algorithms to 'score' specific characteristics of each image
- Based on evaluation of images by radiologists and technologists
- Millions of images worldwide in data bank

MAMMOGRAPHY EDUCATORS

247

Artificial Intelligence for Image Evaluation

- Evaluates specific positioning criteria
- Identifies deficiencies
- Identifies areas of excellence!
- Also can identify areas that need improvement with instructions and/or videos on how to improve!
- Should provide references and/or instruction for improvement

MAMMOGRAPHY EDUCATORS

248



Source: Augusto Tomas

249

With change comes challenge *and* opportunity.

250

Change is Not Easy… But…

- It is challenging!
- It is something is different!
- It can be fun!!

251

How you approach change will directly affect success!

BE POSITIVE!!

AND STAY CALM…

252

STAY FOCUSED
ON WHAT
IS IMPORTANT



MAMMOGRAPHY EDUCATORS

253

Mission, Motivation,
Patients and Perspective



MAMMOGRAPHY EDUCATORS

254

Mission

- What you do now
- For whom
- How you do it
- What it achieves



MAMMOGRAPHY EDUCATORS

255

Mission

- Our aspirations as individuals
- Our aspirations as a group



MAMMOGRAPHY EDUCATORS

256

Motivation

- Setting goals
- Attitude
- Success
- Performance
- Support
- Ideas

Motivation

- How do we motivate others
- How do we keep ourselves motivated

Patients: Why We Do What We Do!

Why we do what we do?



Perspective: How We Look at Things



Distorted Perspective

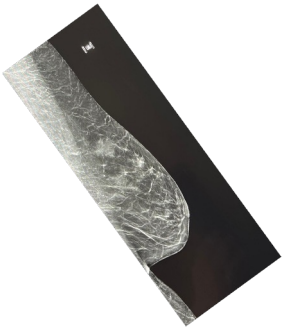

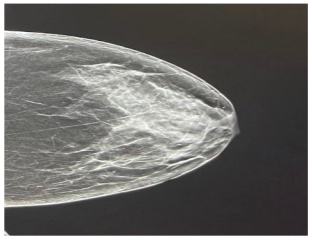

261

Burnout and Stress



262

In Times of Stress

- Remember your mentor or someone you have mentored
- Remember the patient who thanked you for being kind
- Remember something that was personal and positive related to your work

263

This is Personal!

Each and every patient belongs to someone.
Take the time to see them as such.

264

Remembering this will help us focus on the commitment we have made as health CARE professionals.



MAMMOGRAPHY EDUCATORS

265

Are you too busy?



MAMMOGRAPHY EDUCATORS

266

What about your commitment to your work?

Why are you doing this in the first place?



MAMMOGRAPHY EDUCATORS

267

Committed to a Cause

- Gives us a sense of competence about ourselves and others
- Helps us focus our energy
- Is a positive outlet for our energy
- Creates a positive identification
- Connects us with our spiritual self



MAMMOGRAPHY EDUCATORS

268

When We Are Committed

- Emotional support
- Empathy
- Engage with our self and others
- Utilize our inner resources to guide us

Committed to a Cause

- We benefit emotionally
- Create interdependence
- Add to our mental well-being

Committed to Compassion



Having Pride in What You Do







Individual and Collective Pride

Experiences in which we can say:
"I….we….did this well"



MAMMOGRAPHY EDUCATORS

273

Being of service to one another, one colleague, one patient, one life at a time, one moment at a time is essentially what the role of the breast health professional is all about….

MAMMOGRAPHY EDUCATORS

274

Being proud of what you do… and your special role as a link in the chain of life.

MAMMOGRAPHY EDUCATORS

275

Pride we can feel when we are…

- Kind
- Compassionate
- Mentoring
- Teaching
- Motivating
- Sharing
- Healing
- Helping

MAMMOGRAPHY EDUCATORS

276

Making a Difference



MAMMOGRAPHY EDUCATORS

277

This is Personal!

Each and every patient belongs to someone.
Take the time to see them as such.

MAMMOGRAPHY EDUCATORS

278

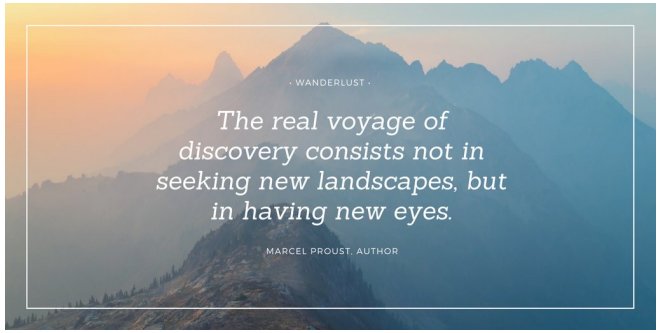

MAMMOGRAPHY EDUCATORS

279



MAMMOGRAPHY EDUCATORS

280

Thank You!

Services we offer, include:
Onsite Positioning Training
Assistance with Accreditation & Inspection
Live Webinars and Conferences
On-Demand Continuing Education

For questions or more information:

Ph: 619-663-8269 | info@mammographyeducators.com

MAMMOGRAPHY EDUCATORS

281



Interact with Breast Imaging Professionals from Around the World

Join our Facebook Group:

Quality Breast Imagers

www.facebook.com/groups/qualitybreastimagers

MAMMOGRAPHY EDUCATORS

282

References

Derenberger, D., & Hadley, R. (2021). Most commonly used additional views, part 3: Defining structures and clarifying presence of abnormalities. *SBI News*, (1). https://mammographyeducation.com/most-commonly-used-additional-views-part-3-defining-structures-and-clarifying-presence-of-abnormalities/

James, J. T. (2013). A new, evidence-based estimate of patient harms associated with hospital care. *Journal of Patient Safety*. https://journals.lww.com/journalpatientsafety/Fulltext/2013/09000/A_New,_Evidence_based_Estimate_of_Patient_Harms.2.aspx

Long, S. M., Miller, L. C., Botsco, M. A., & Martin, L. L. (2010). *Handbook of mammography* (5th ed.). Mammography Consulting Services.

Miller, L. C. (2015). What every mammography technologist would like their radiologist to know about: Our patients. *SBI Newsletter.*

Miller, L. C. (2016, June 3). A technologist's perspective of the FDA report "Poor positioning for most clinical image deficiencies, failures." *SBI News.*

Miller, L. C. (2024). *Mammography Positioning Guidebook* (3rd ed.). Mammography Educators.

Miller, L. C., & Lehmann, T. L. (2020). *Meeting Equip Standards: Image Quality & Positioning Problem-Solving for Breast Imagers*(1st ed.). Mammography Educators.

Rouette, J., Elfassy, N., Bouganim, N., Yin, H., Lasry, N., & Azoulay, L. (2021). Evaluation of the quality of mammographic breast positioning: A quality improvement study. *CMAJ Open*, 9(2), E607–E612. https://doi.org/10.9778/cmajo.20200211

U.S. Food and Drug Administration. (2017, November 29). *Poor positioning responsible for most clinical image deficiencies, failures.* https://publicl.pagefreezer.com/browse/FDA/27-12-2022T08:32/https://www.fda.gov/radiation-emitting-products/mqsa-insights/poor-positioning-responsible-most-clinical-image-deficiencies-failures

MAMMOGRAPHY EDUCATORS

283